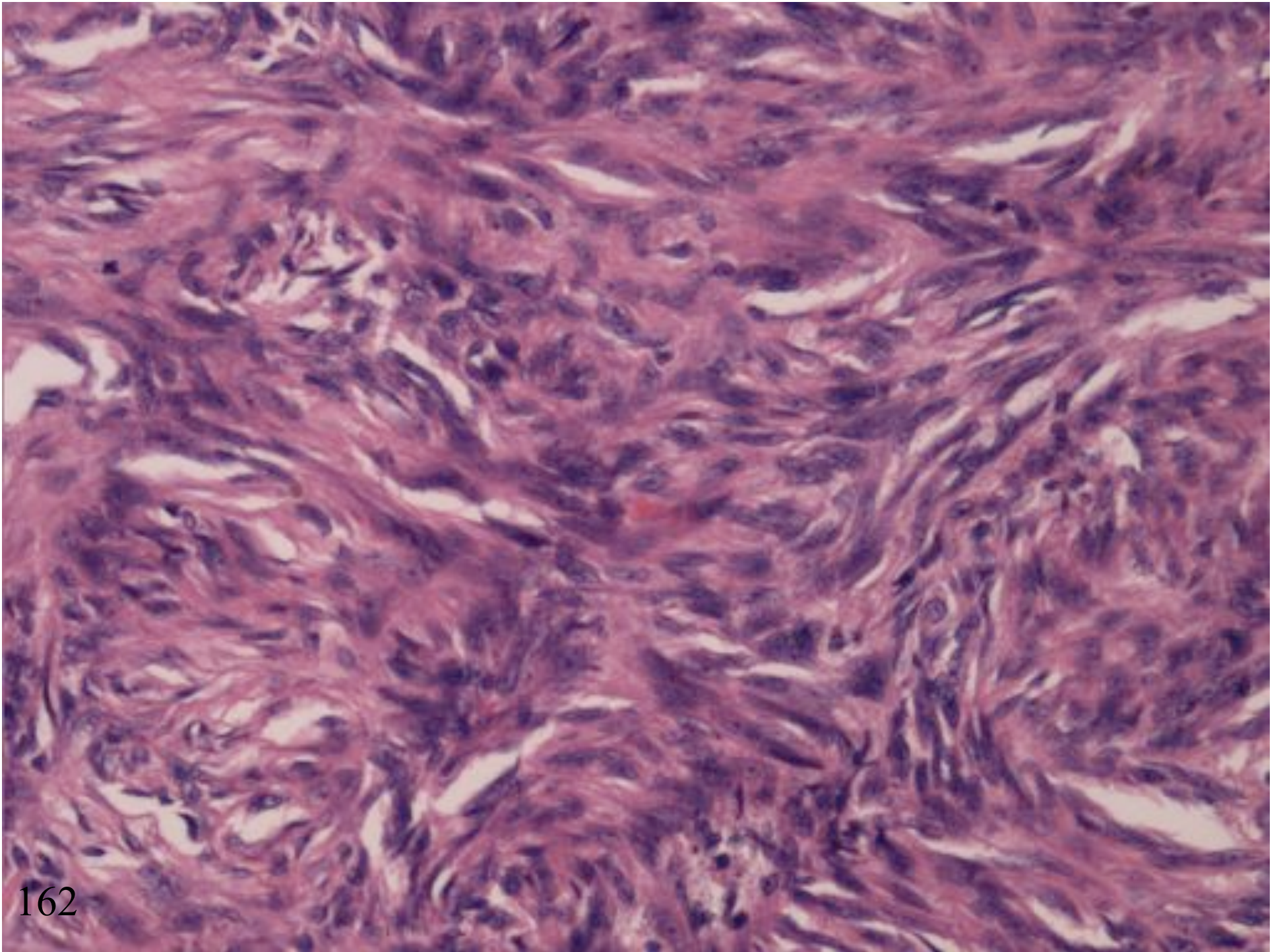
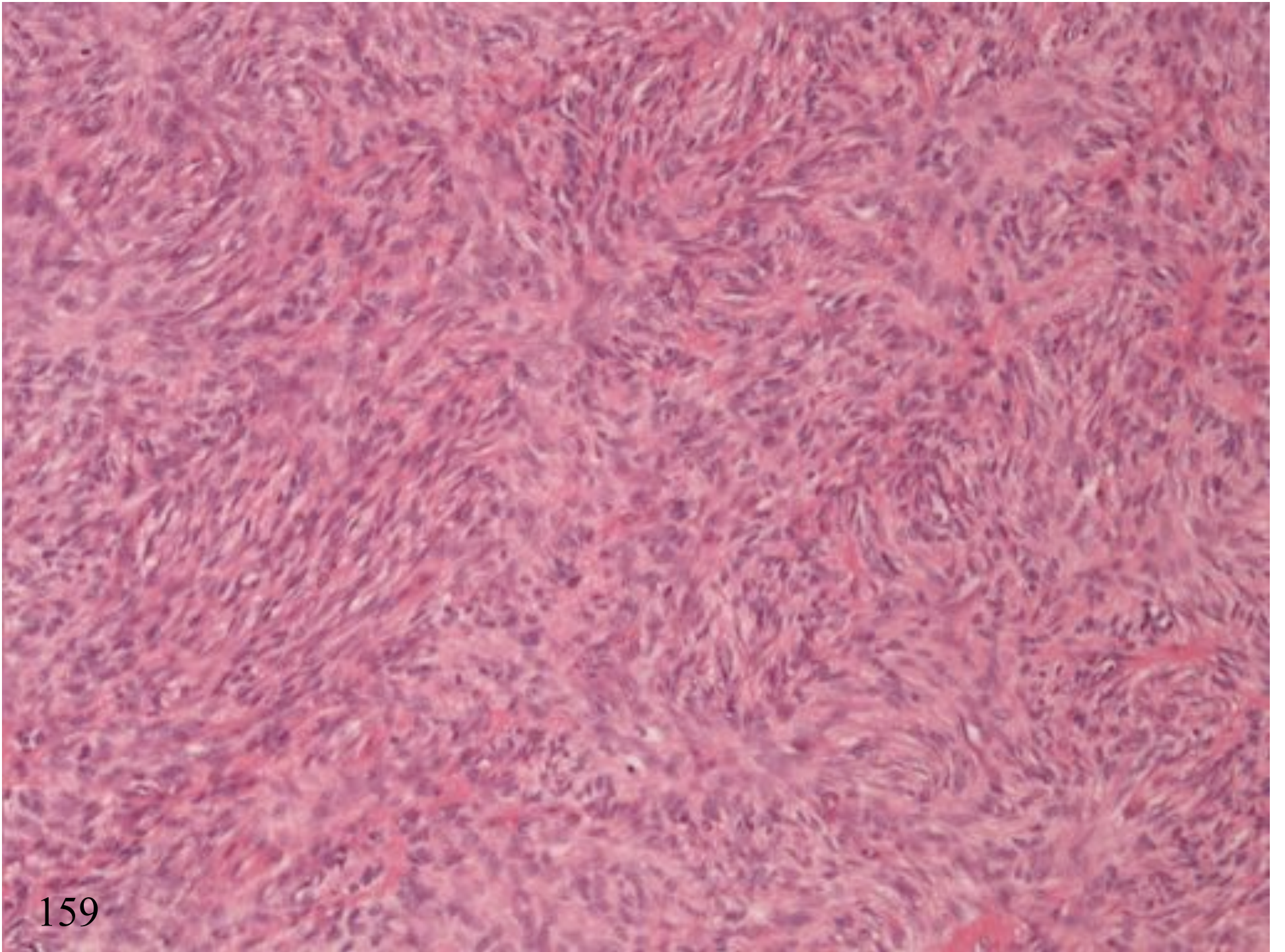


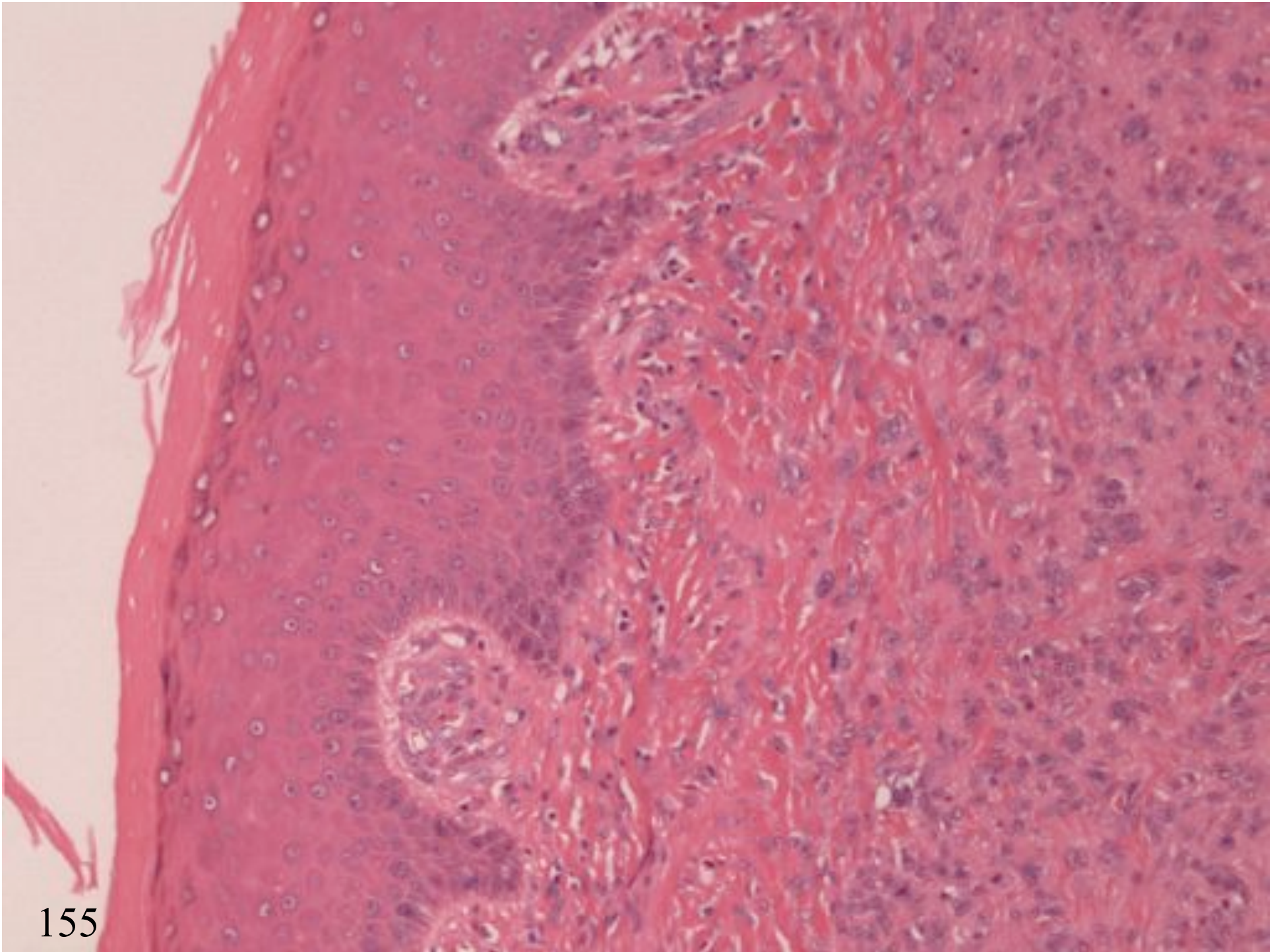
FIBROHISTIOCYTIC PROLIFERATIONS

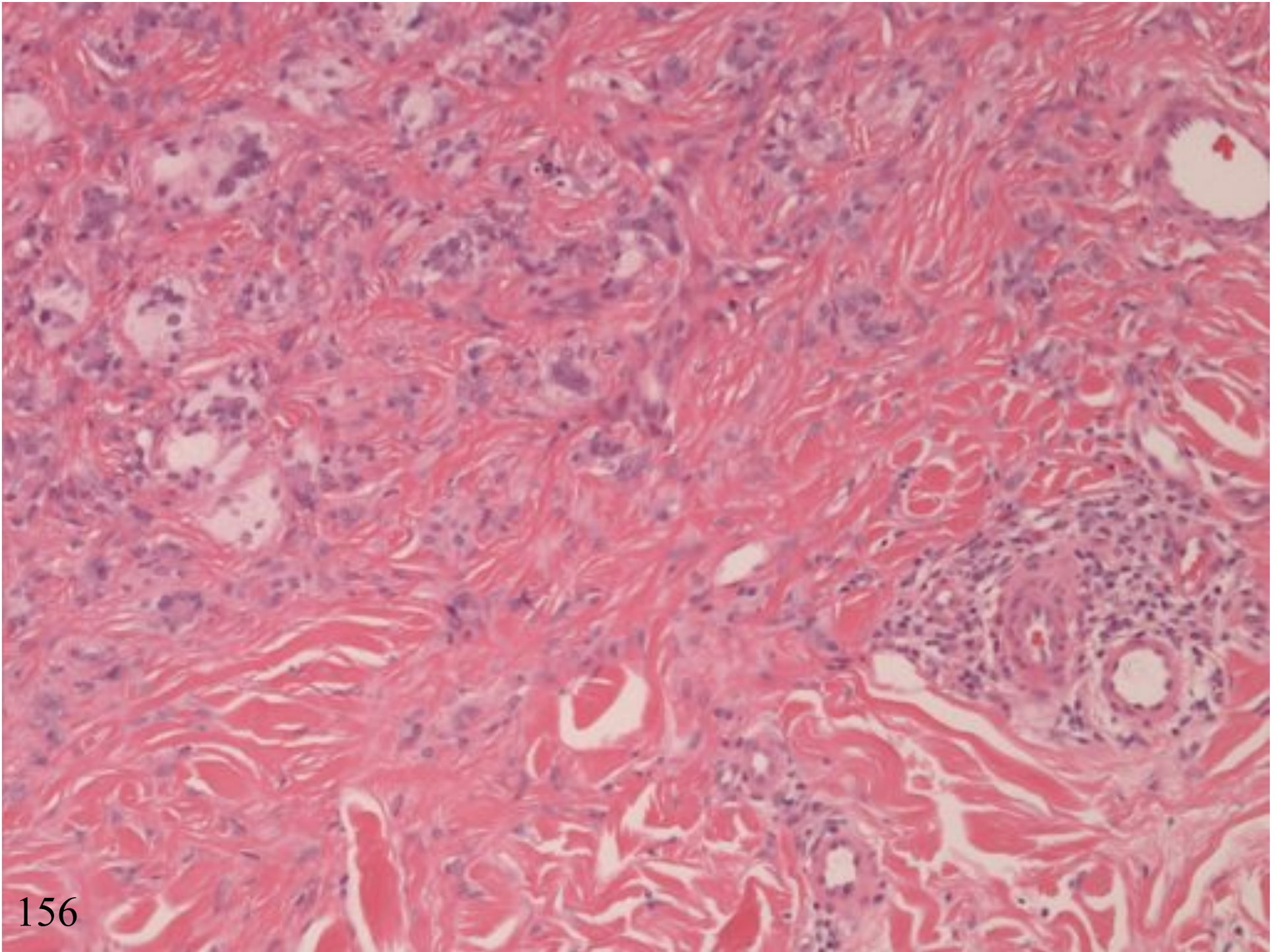
BENIGN FIBROUS HISTIOCYTOMA

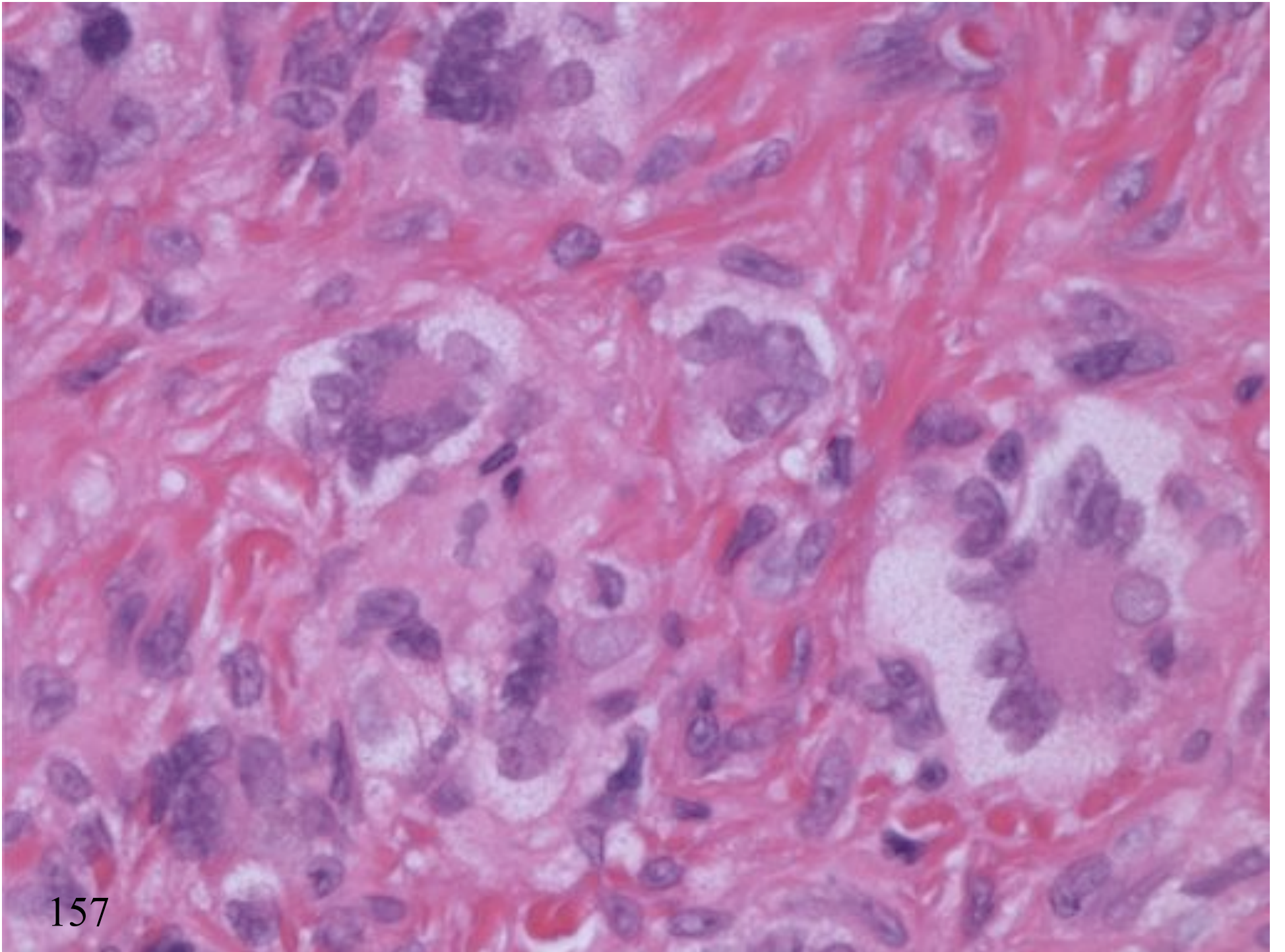
- Cellular storiform pattern (mitoses, sometimes necrosis)
- Pleomorphic
- Unusual location (deep)



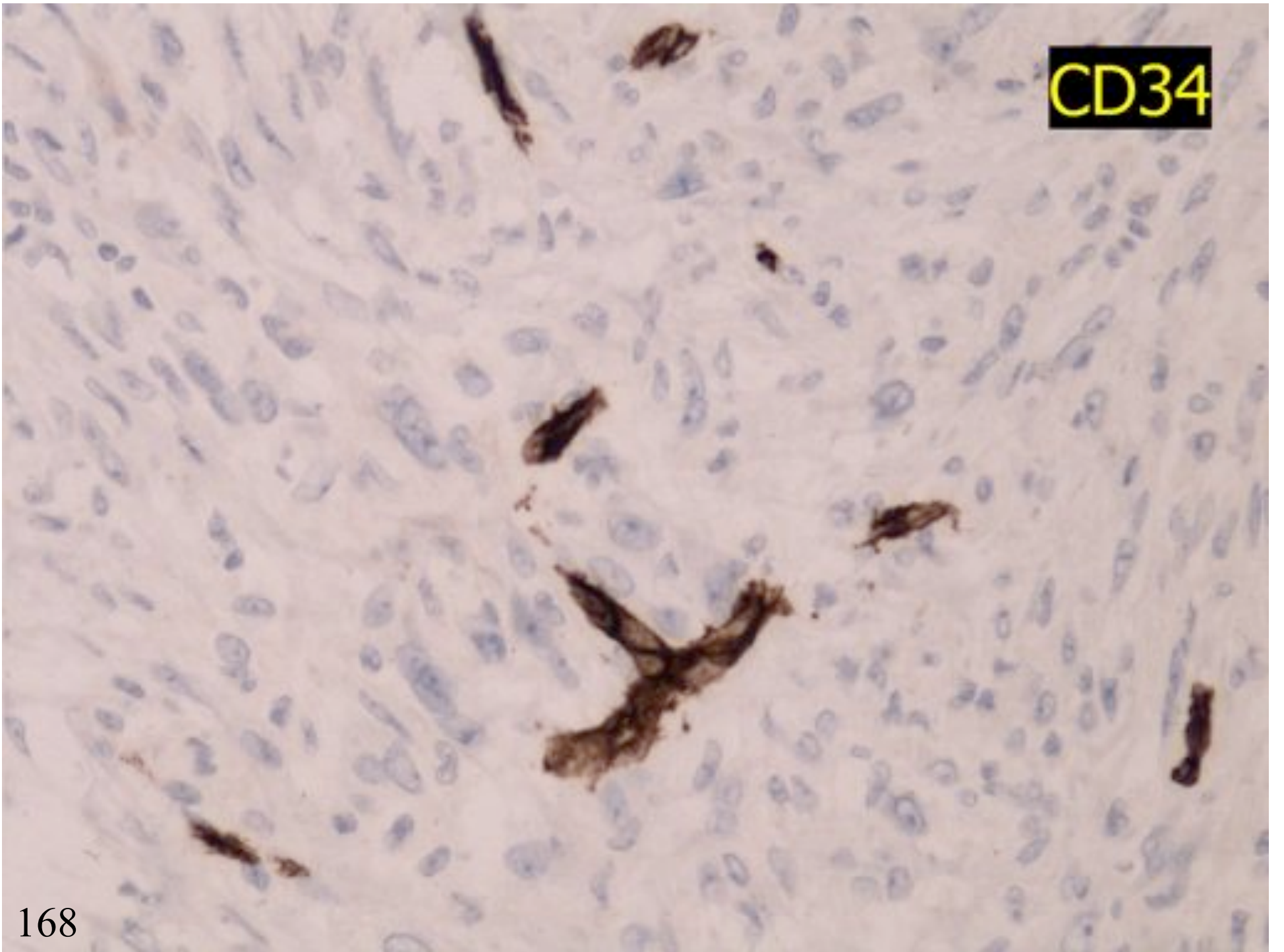




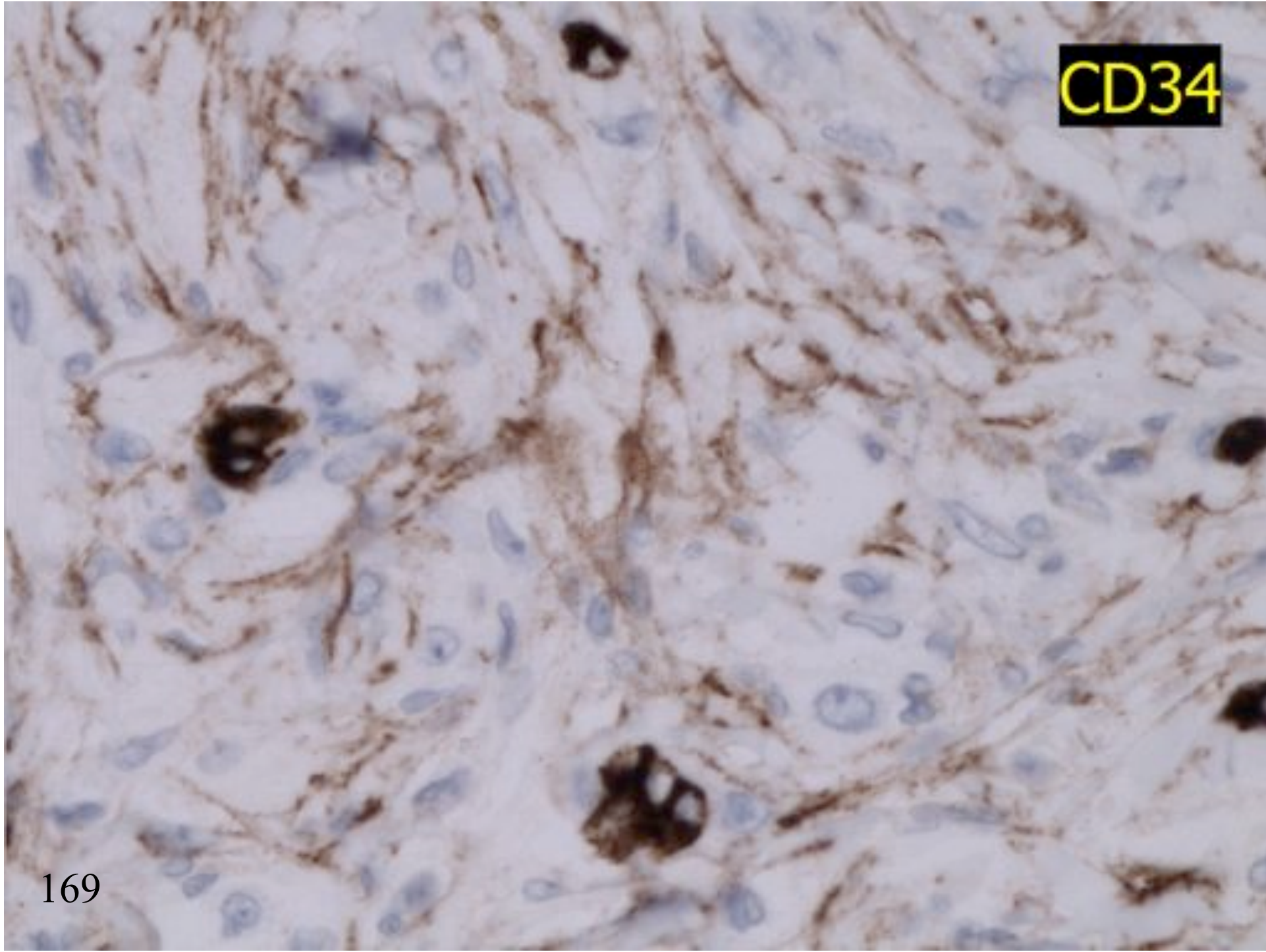




CD34



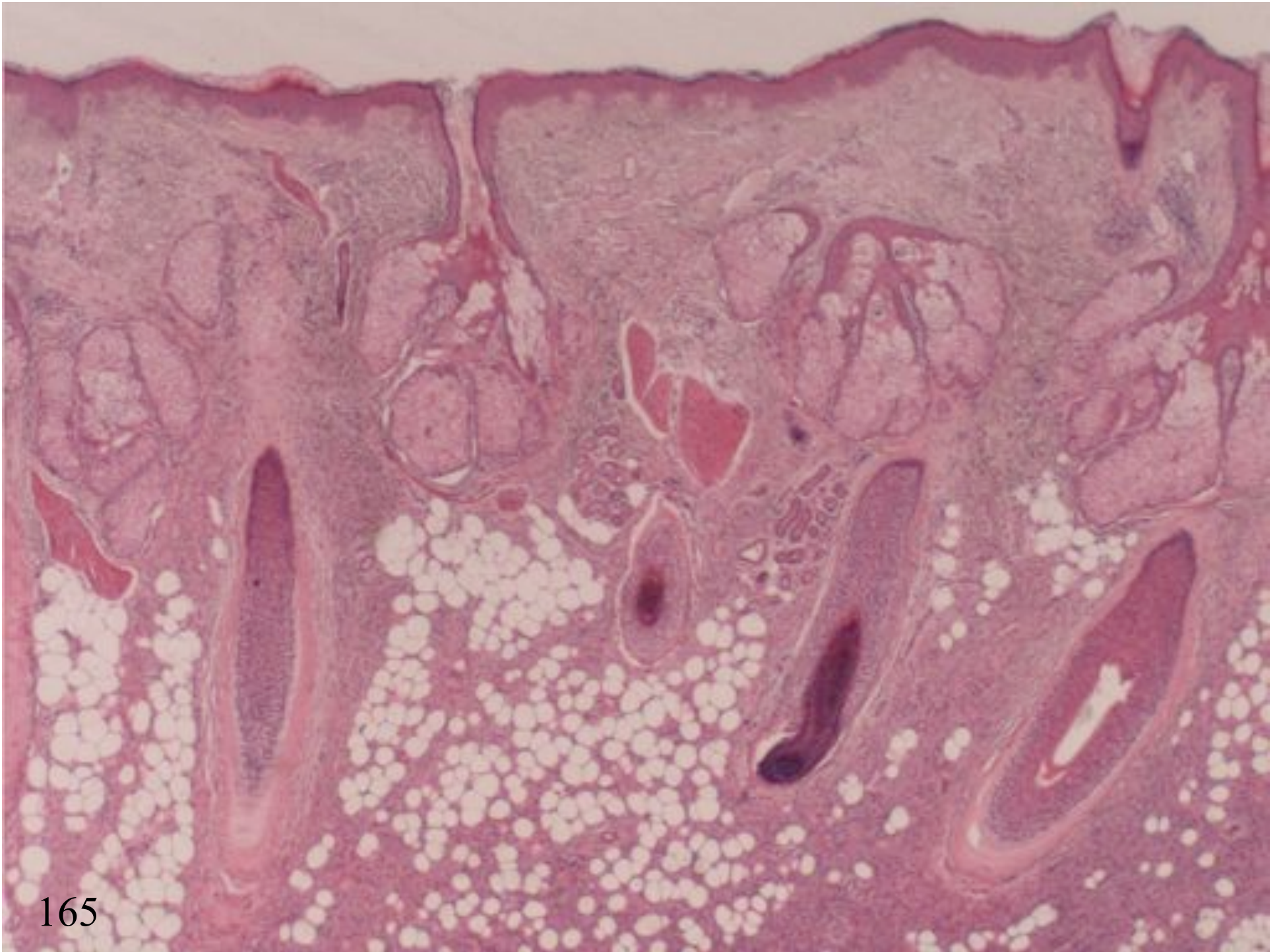
CD34

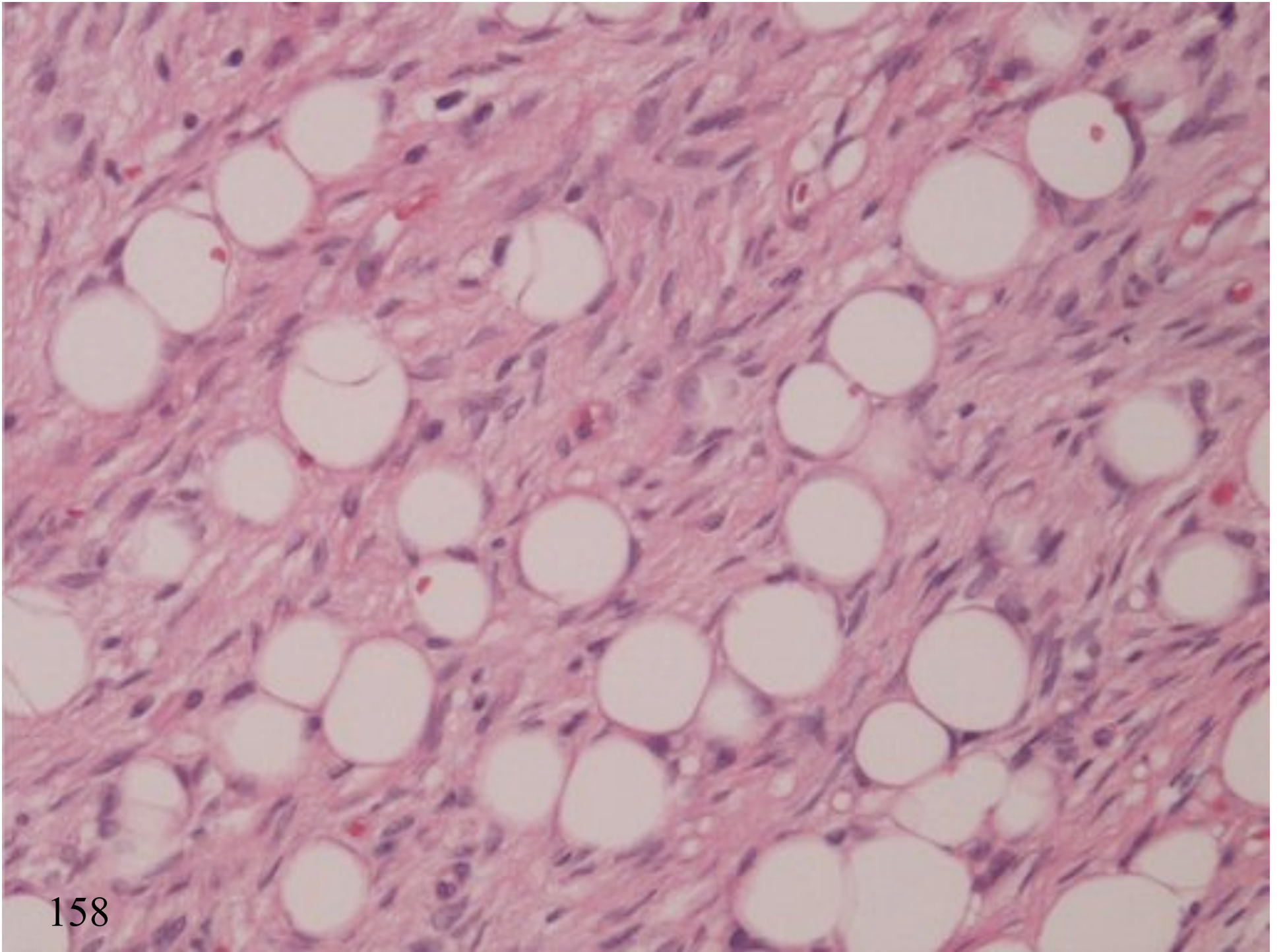


DEEP BFH

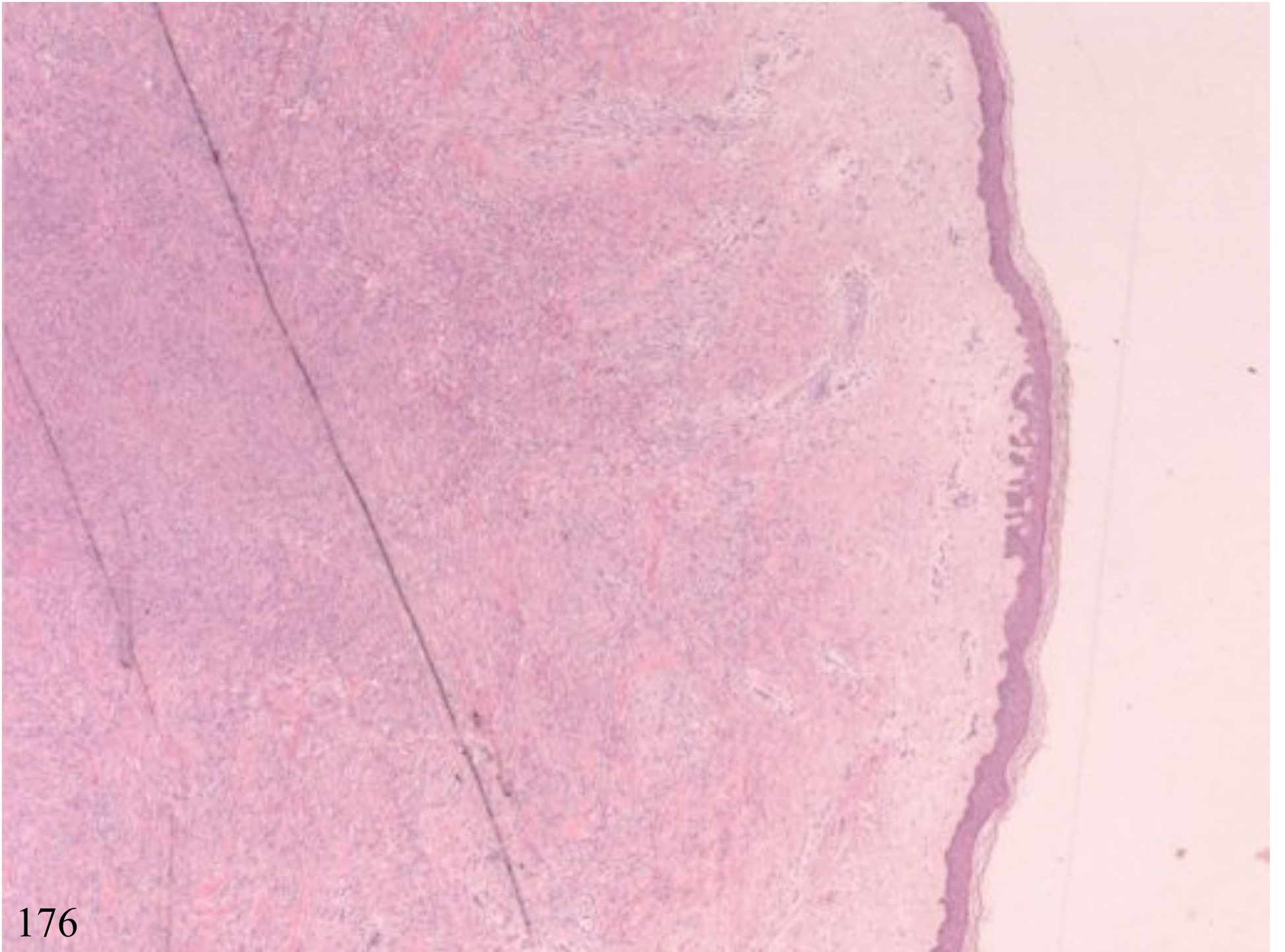
- Monomorphic
- Haemangiopericytic vasculature
- Benign cytology

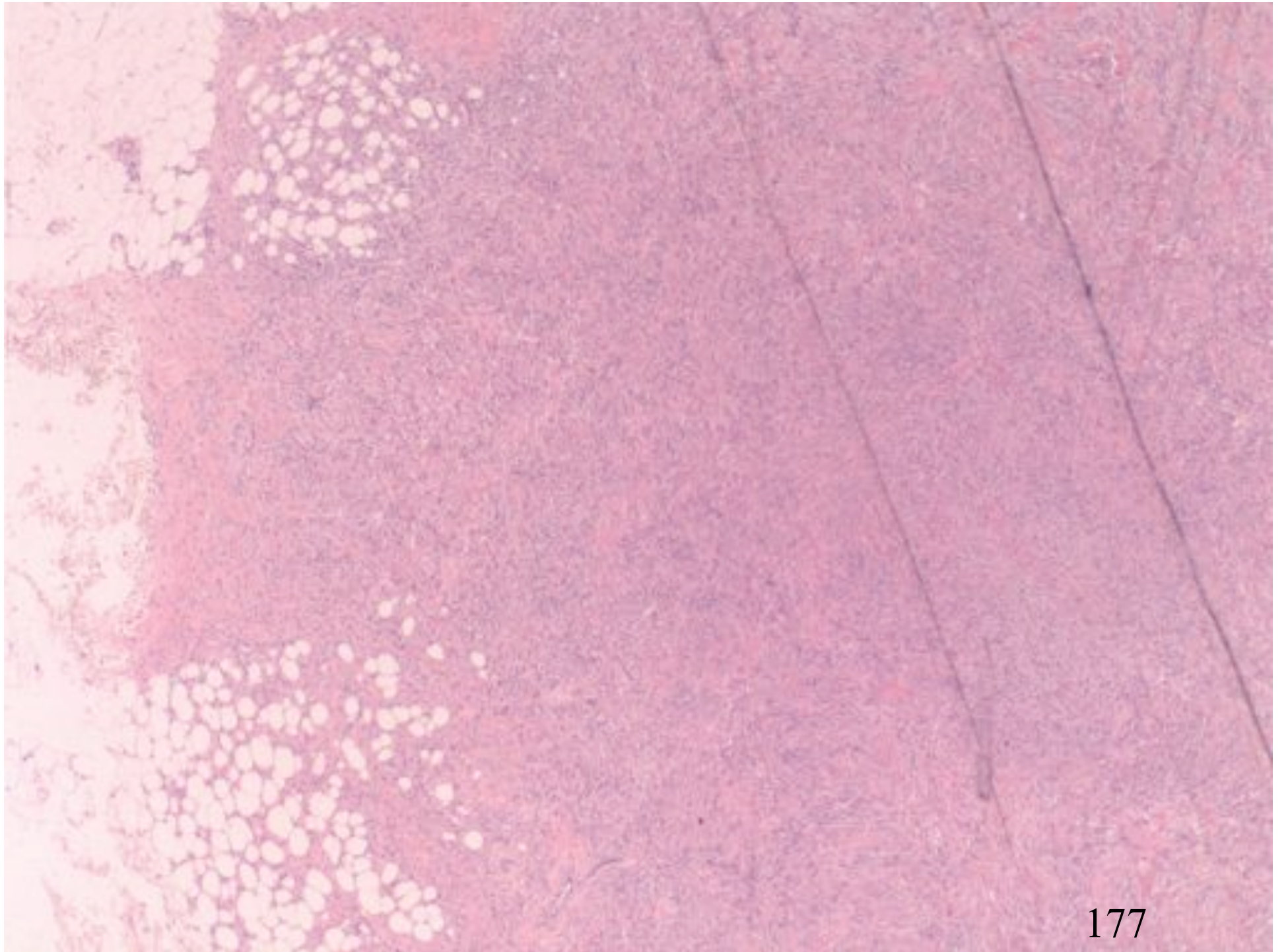
DFSP

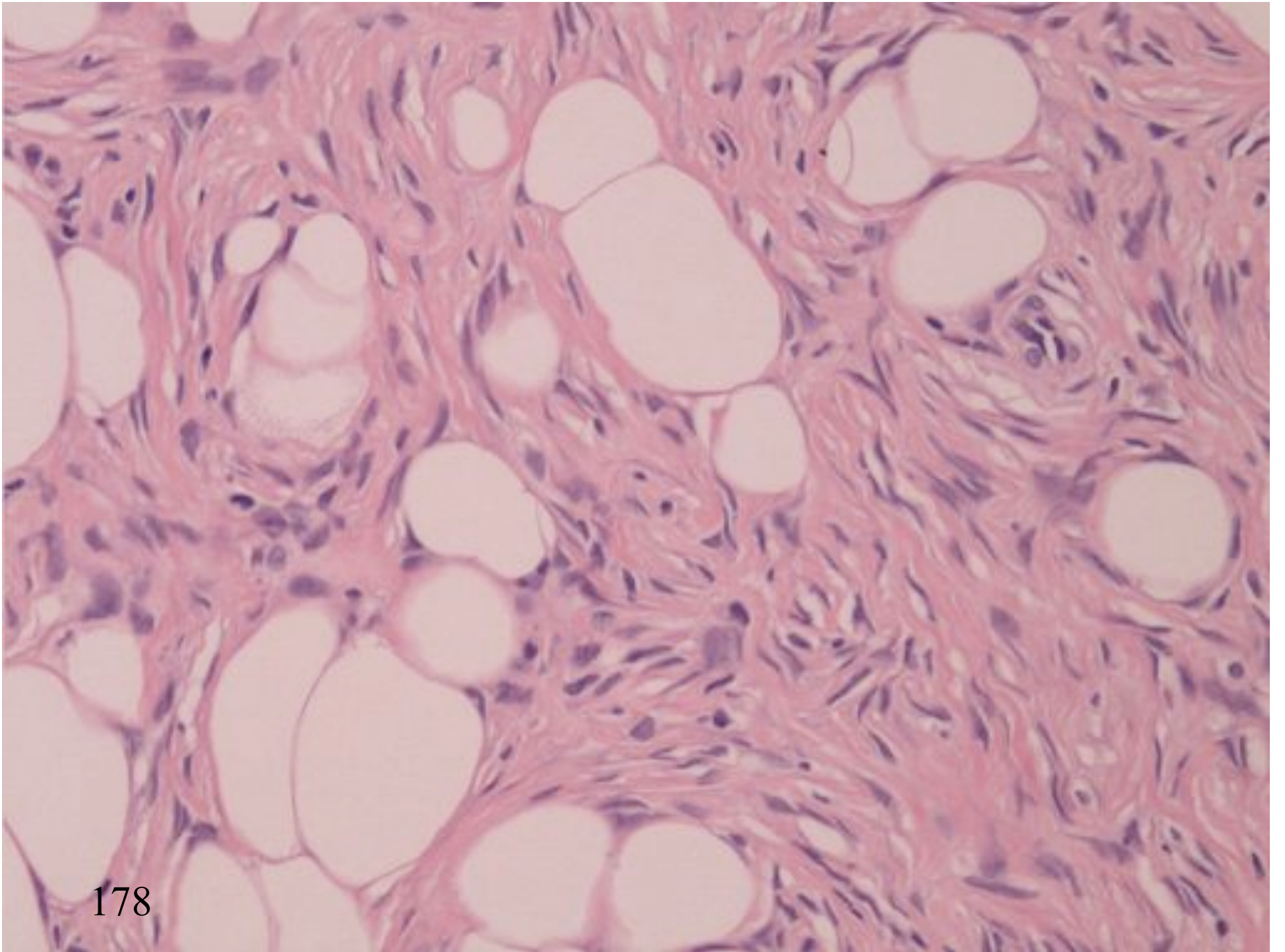


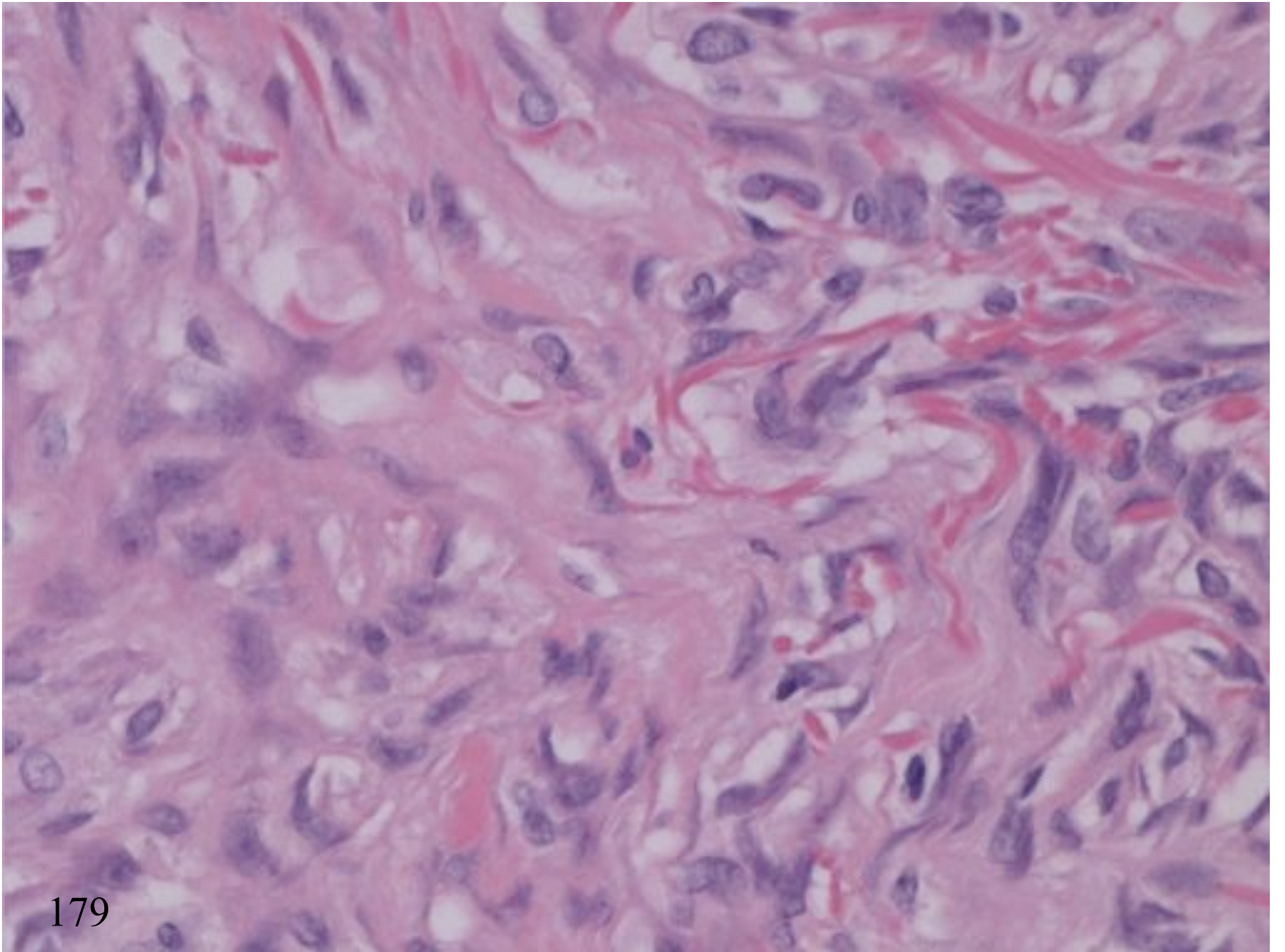


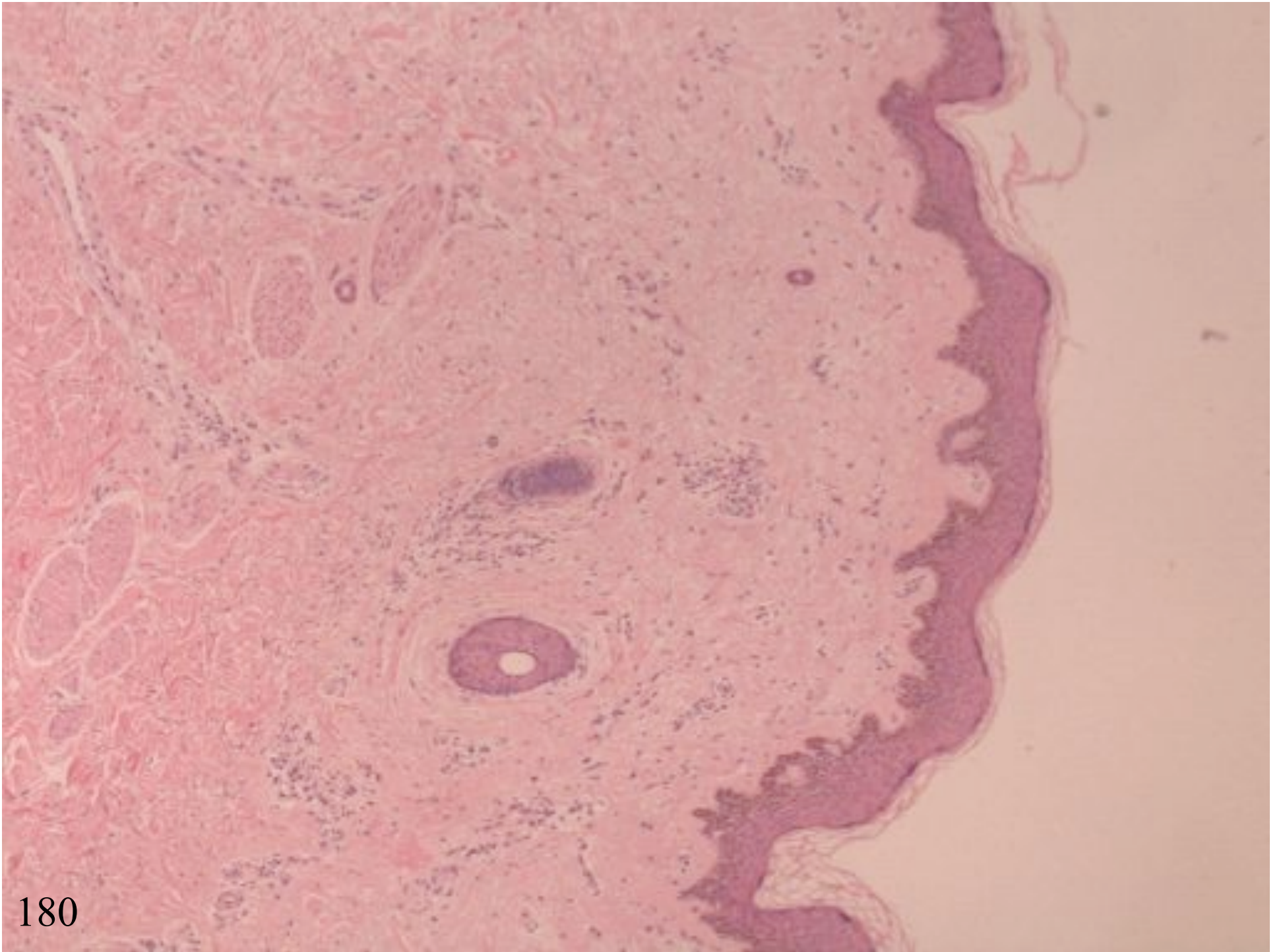
FIBROHISTIOCYTIC TUMOUR

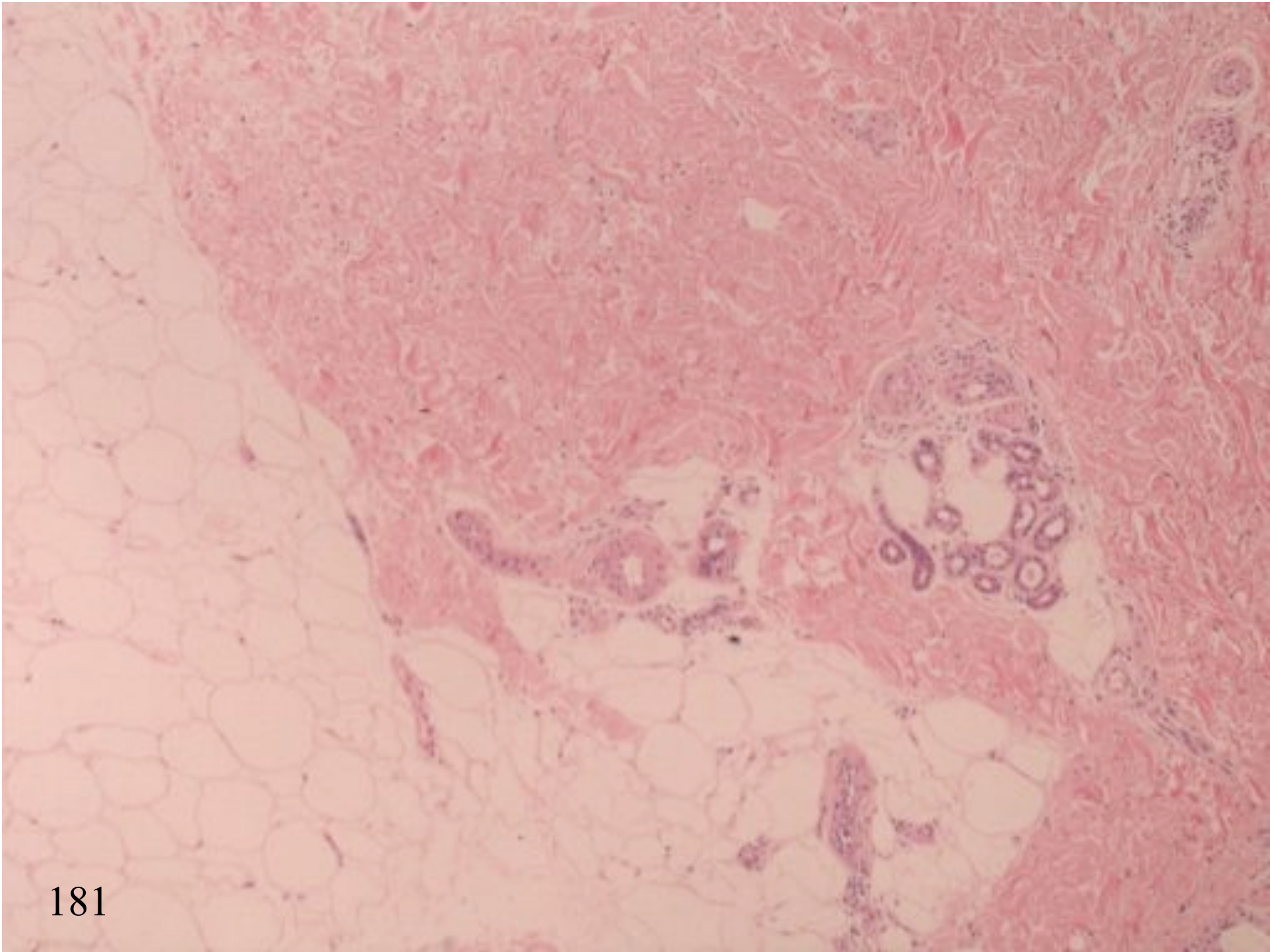




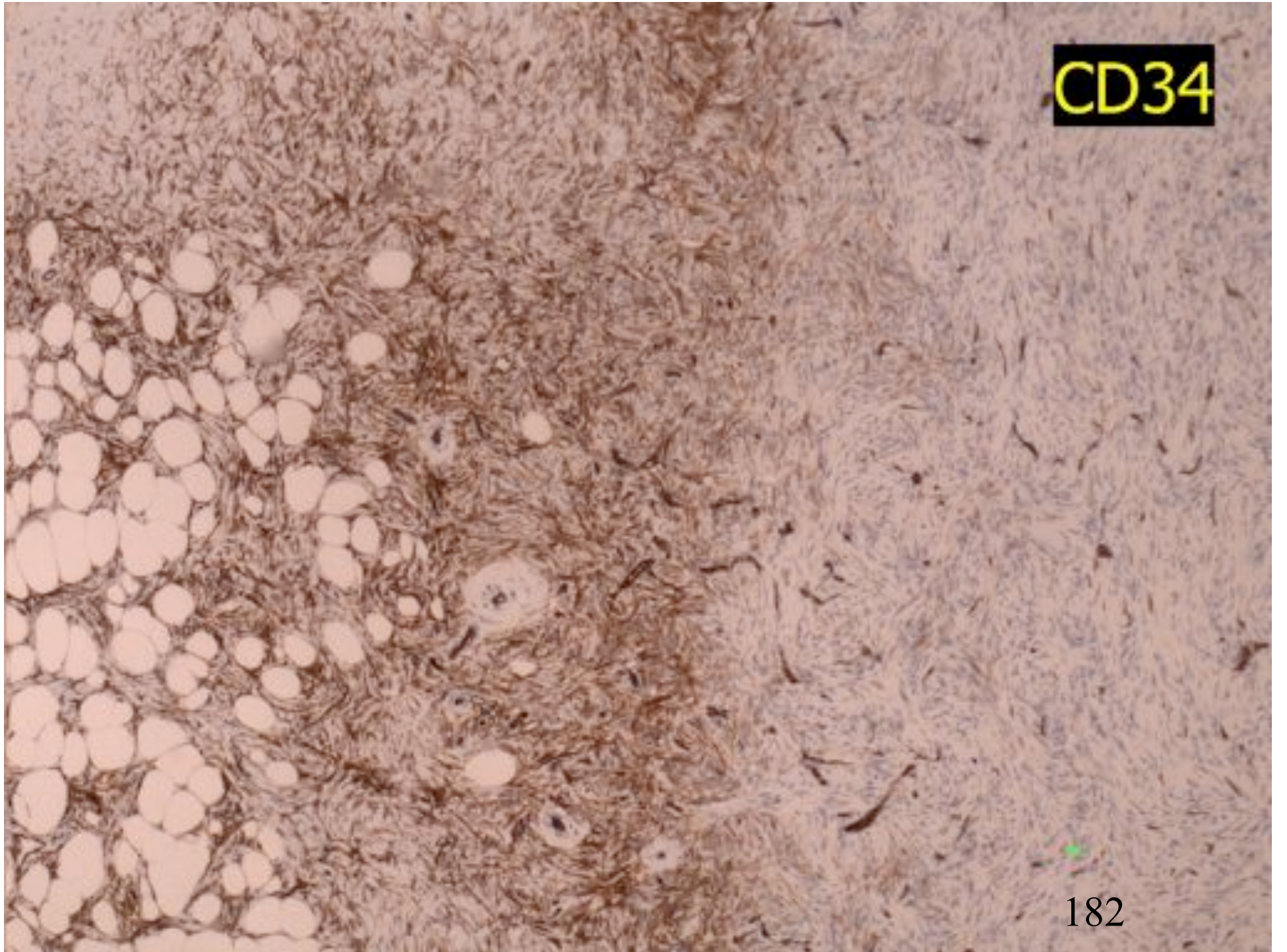




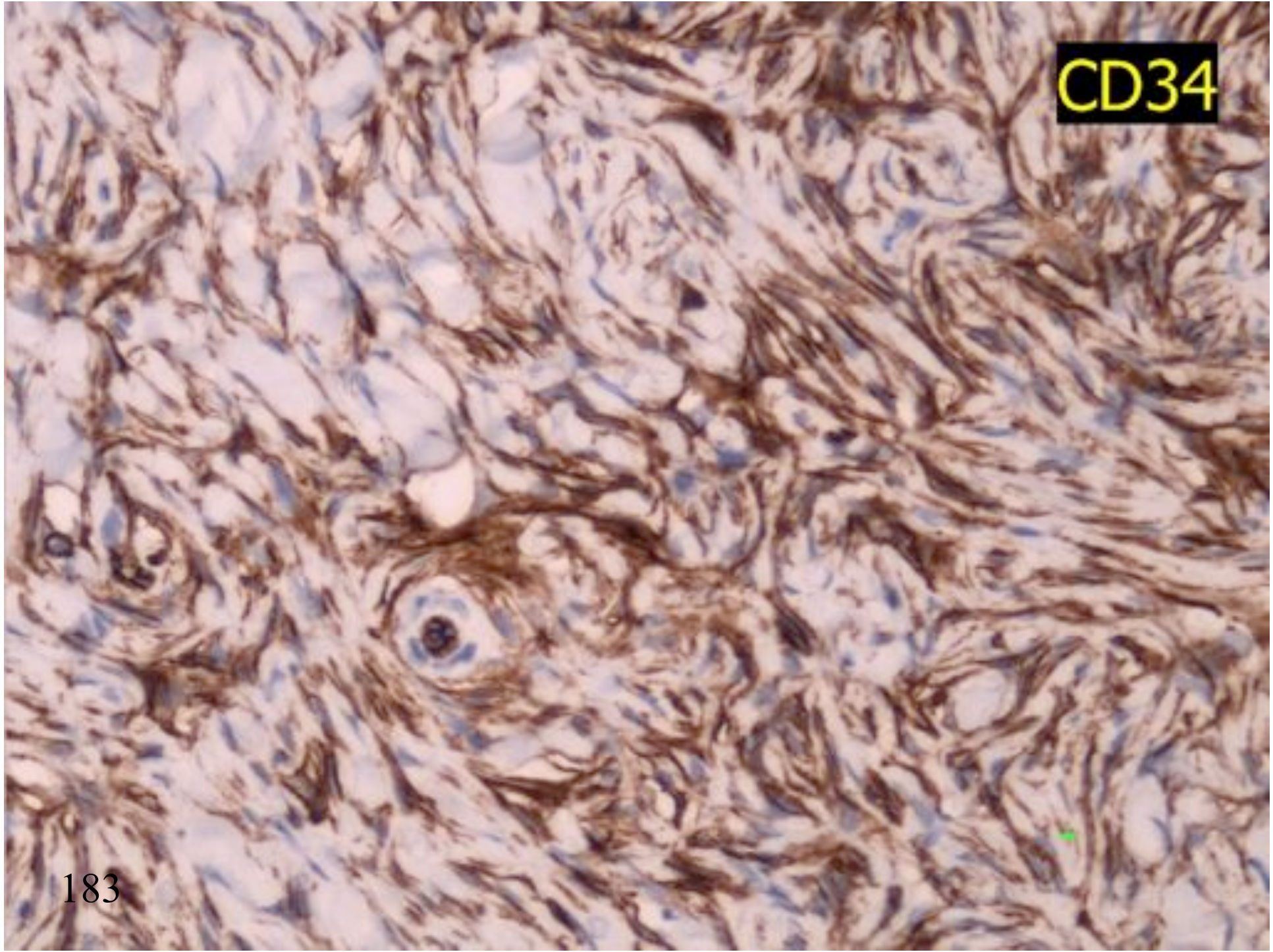




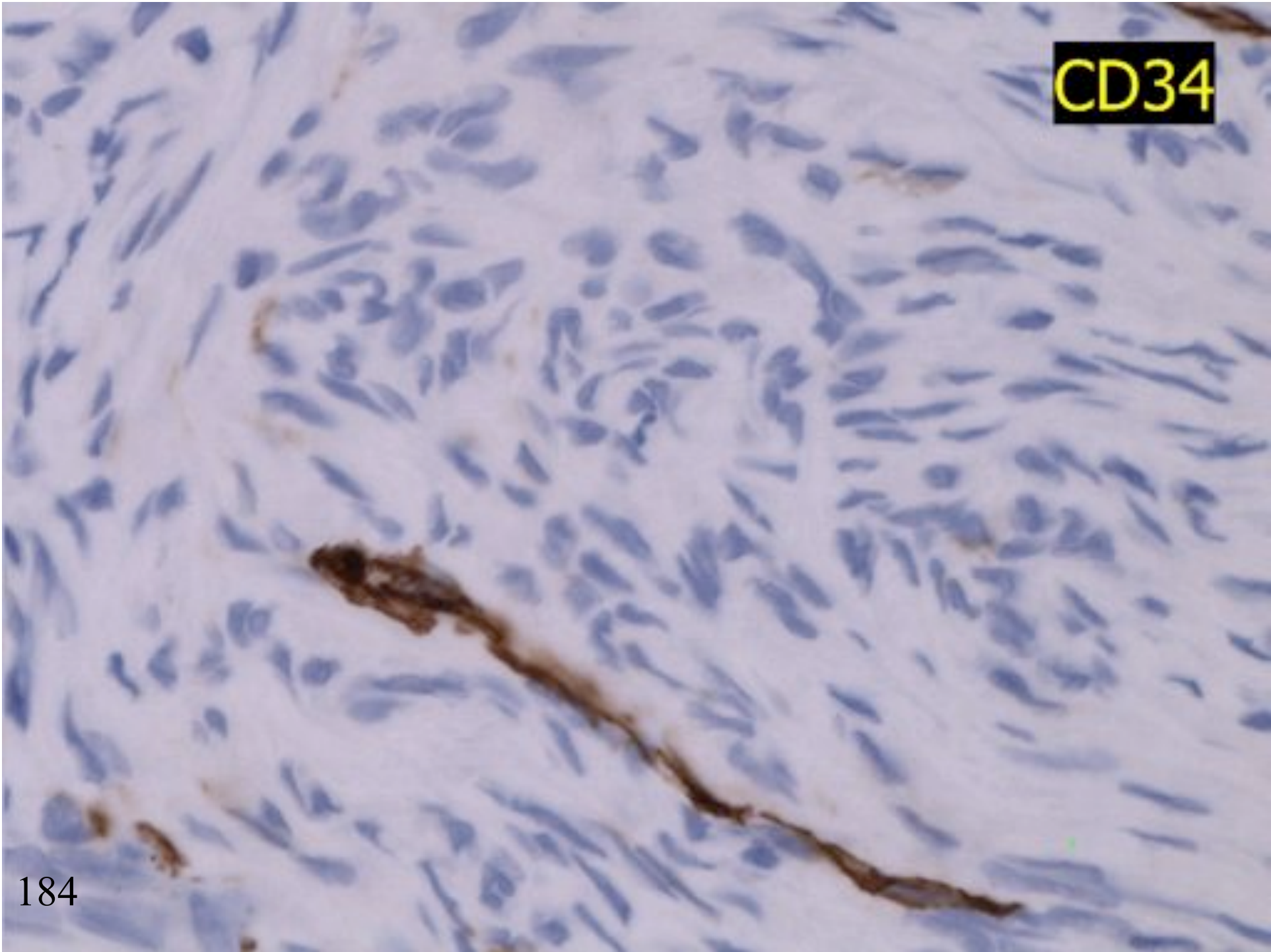
CD34



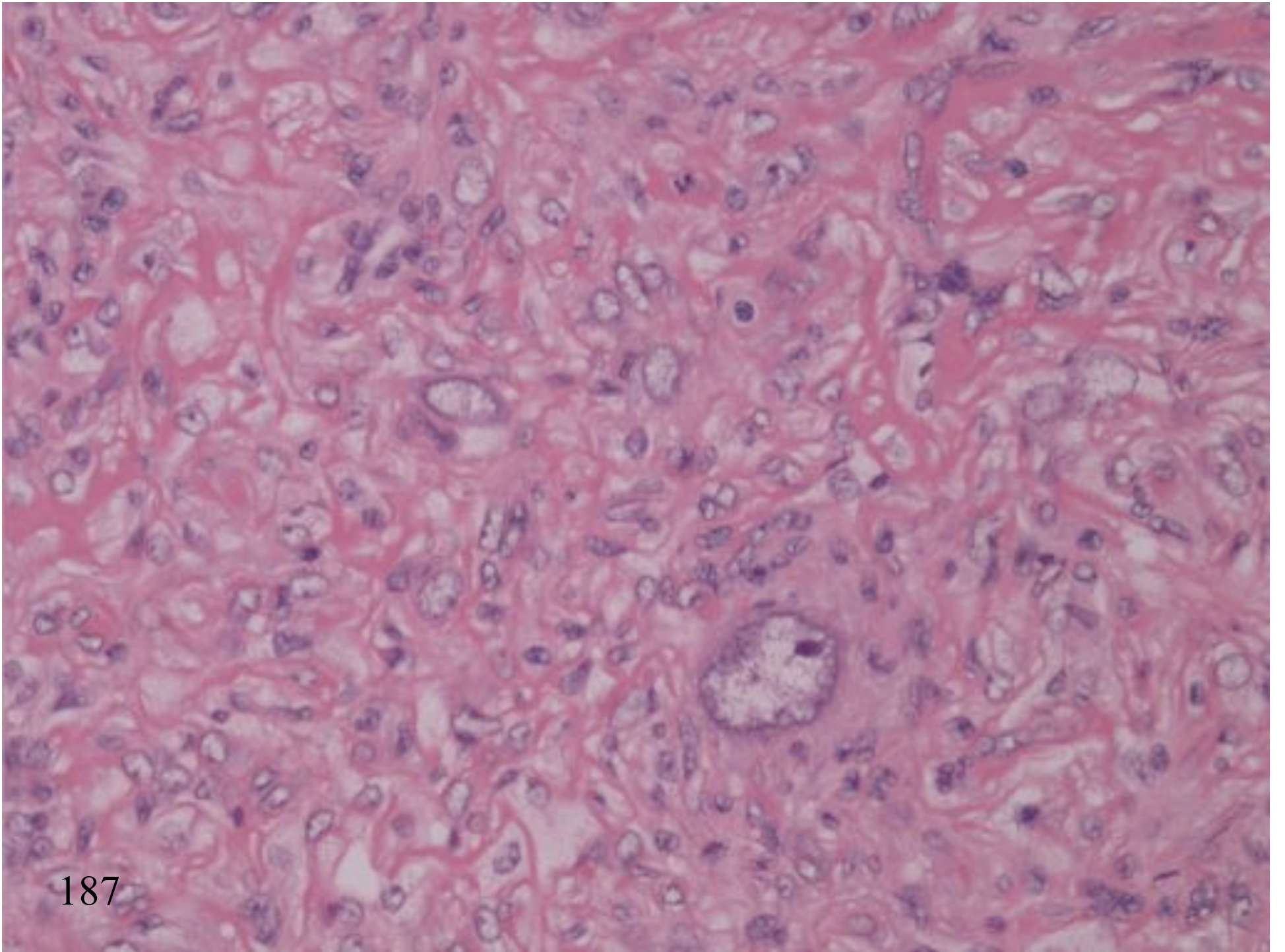
CD34

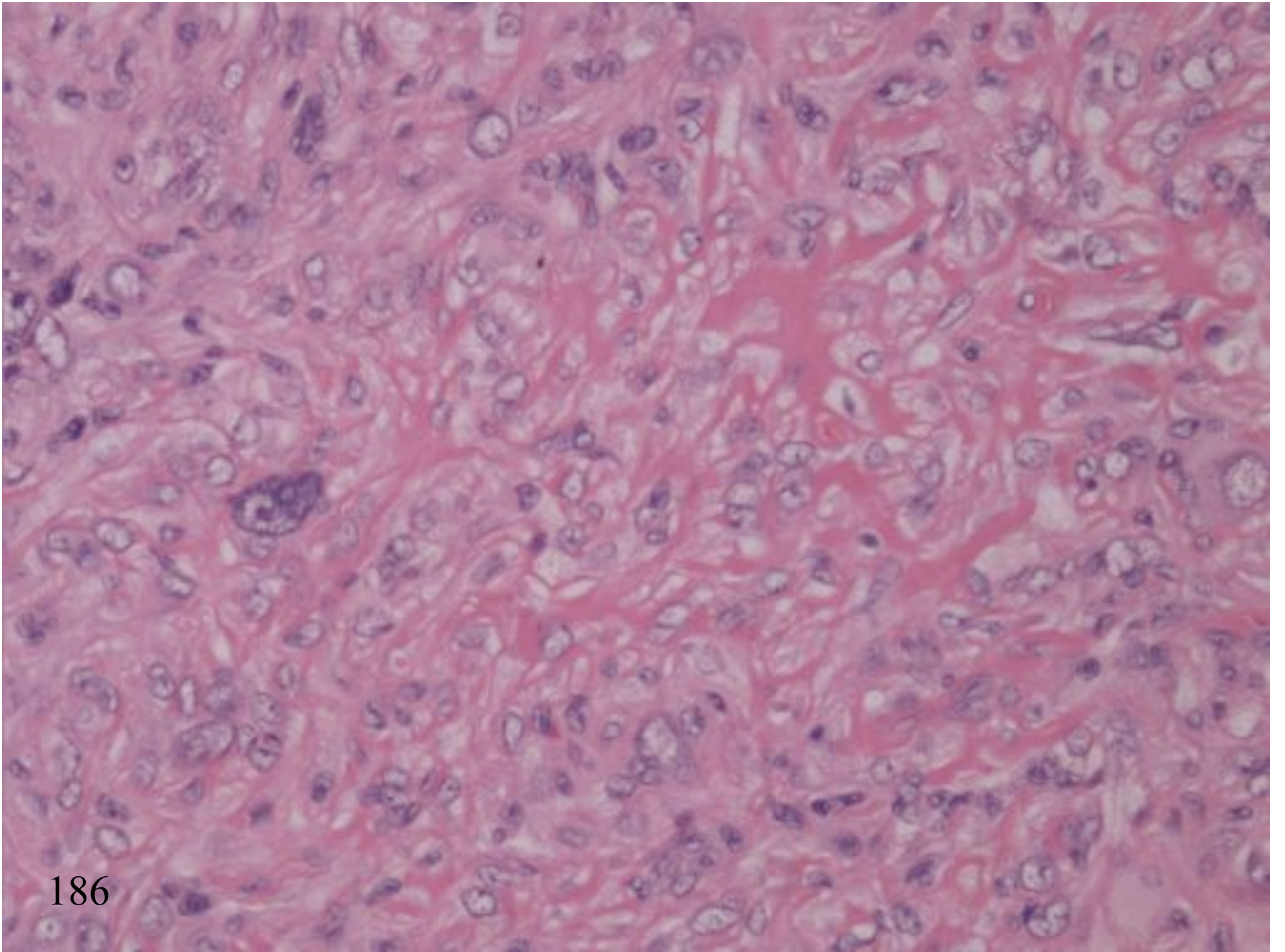


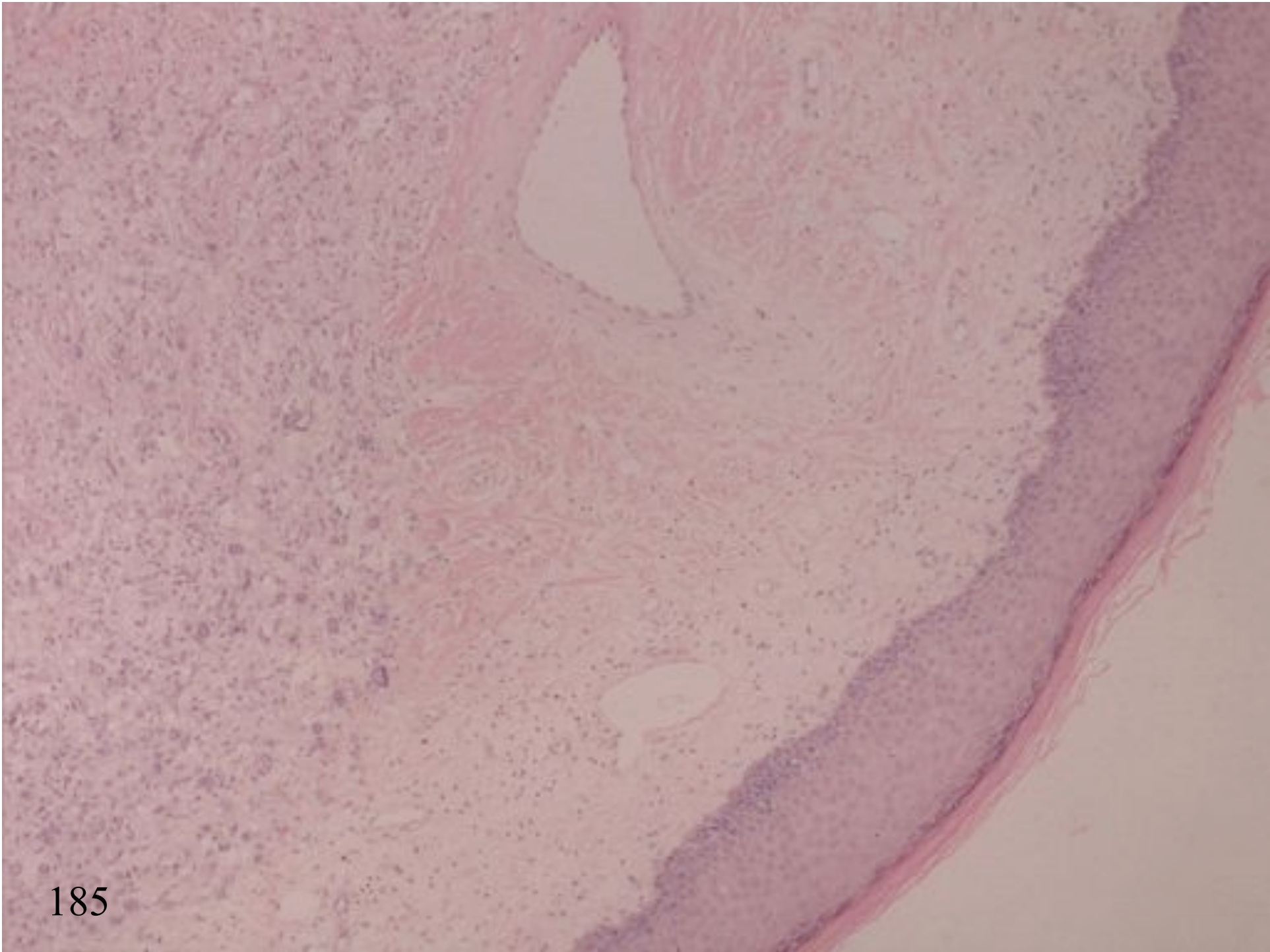
CD34



PLEOMORPHIC FH







FIBROHISTOCYtic PROLIFERATION SUMMARY

1. Cellular benign FH
2. Pleomorphic benign FH
3. Peripheral CD34 positive in benign FH
4. Diffuse neurofibroma as DFSP mimic

