

FIBROBLASTIC PROLIFERATIONS

FIBROBLASTS

- Spindled cells
- Produce extracellular fibres (collagen & elastin)
- Produce ground substance (glycosaminoglycans)

FIBROBLASTIC PROLIFERATIONS

- Wound healing/scar tissue/granulation tissue
- Tumour-like reactive proliferations
- Benign tumours (fibroma)
- Malignant tumours (fibrosarcoma)

Fibroblasts

Myofibroblasts

Smooth muscle cells

Cell shape

SPINDLED

SPINDLED

SPINDLED

Nucleus

TAPERED

TAPERED

CIGAR-SHAPED

Cytoplasm

BASOPHILIC

BASOPHILIC

EOSINOPHILIC

(Active)

(Active)

	Fibroblasts	Myofibroblasts	Smooth Muscle Cells
R.E.R.	++	+	Scanty
Pinocytosis	-	+	++
Bundles of Filaments	-	+	++
Dense bodies	-	+	++
Basal lamina	-	Incomplete	Complete

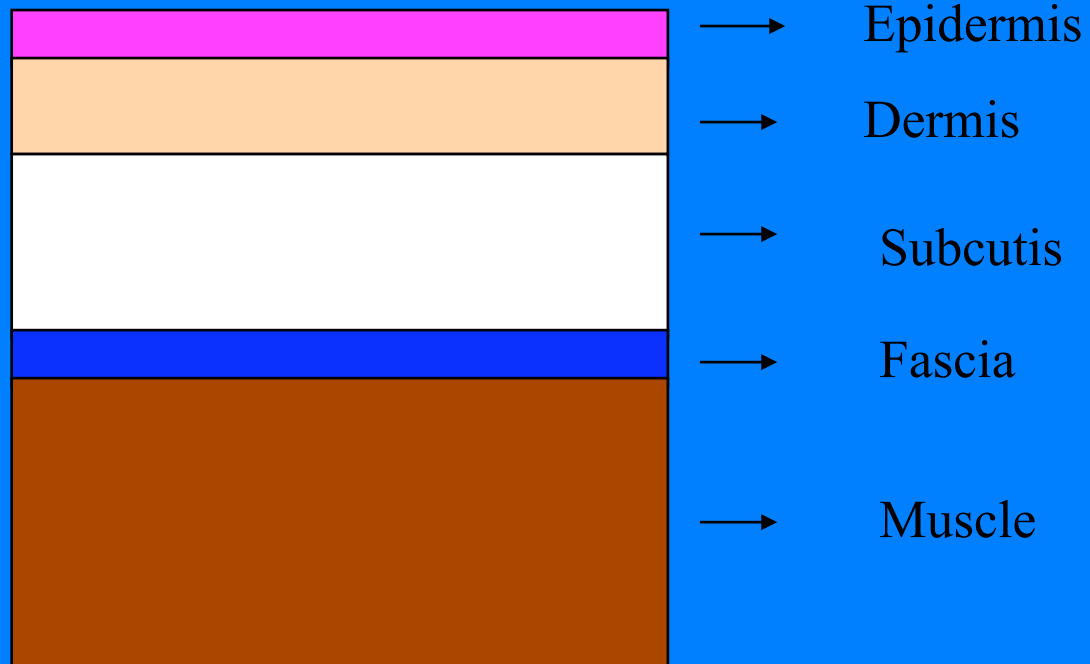
	Fibroblasts	Myofibroblasts	Smooth Muscle Cells
SMA	-	+/-	++
Calponin	-	+	++
Desmin	-	-/+	++
h. Caldesmon	-	-	++

MYOFIBROBLAST HETEROGENEITY

- Vimentin
- Vimentin / Actin
- Vimentin / Actin / Desmin
- Vimentin / Desmin

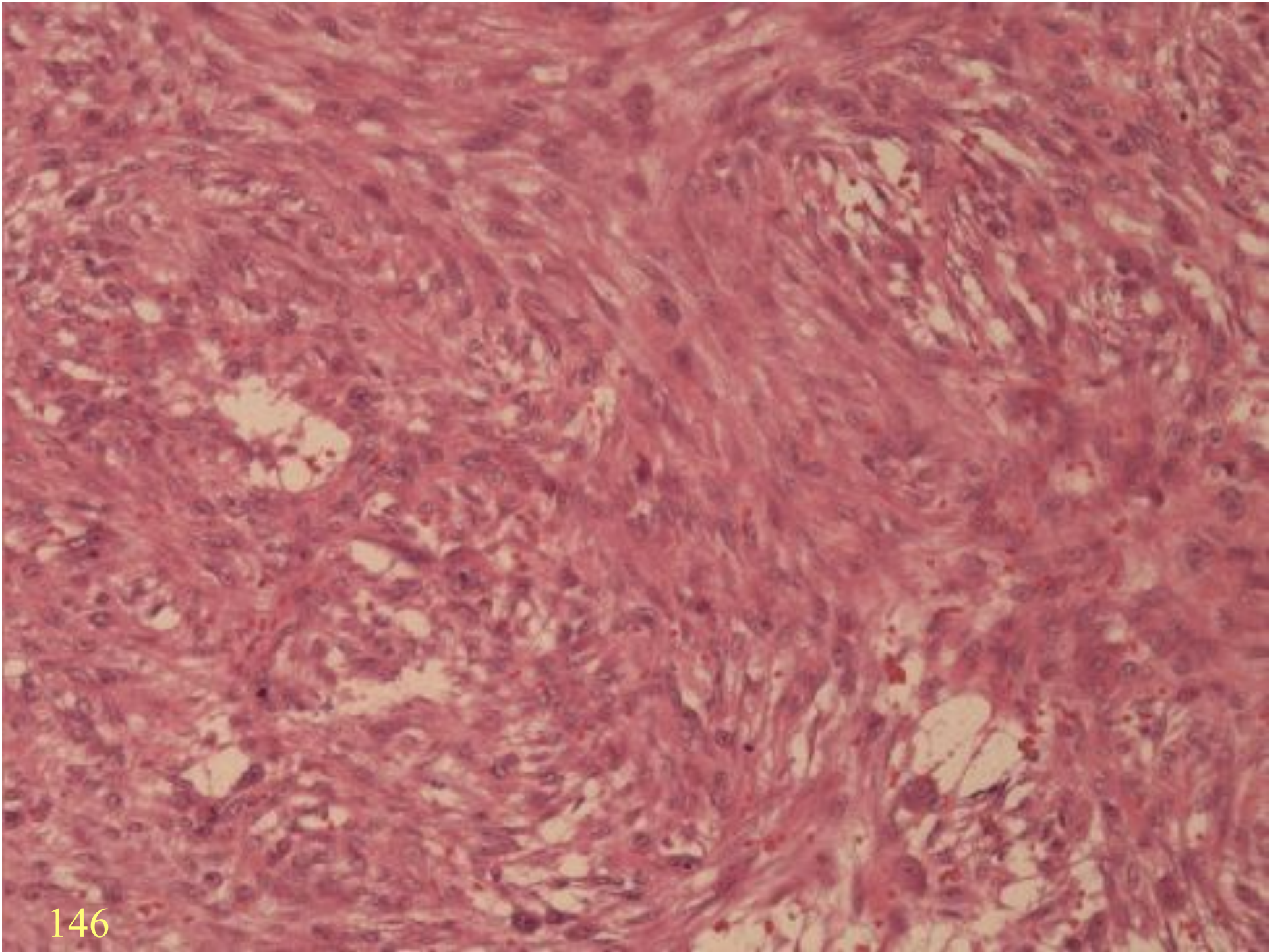
FIBROBLASTS

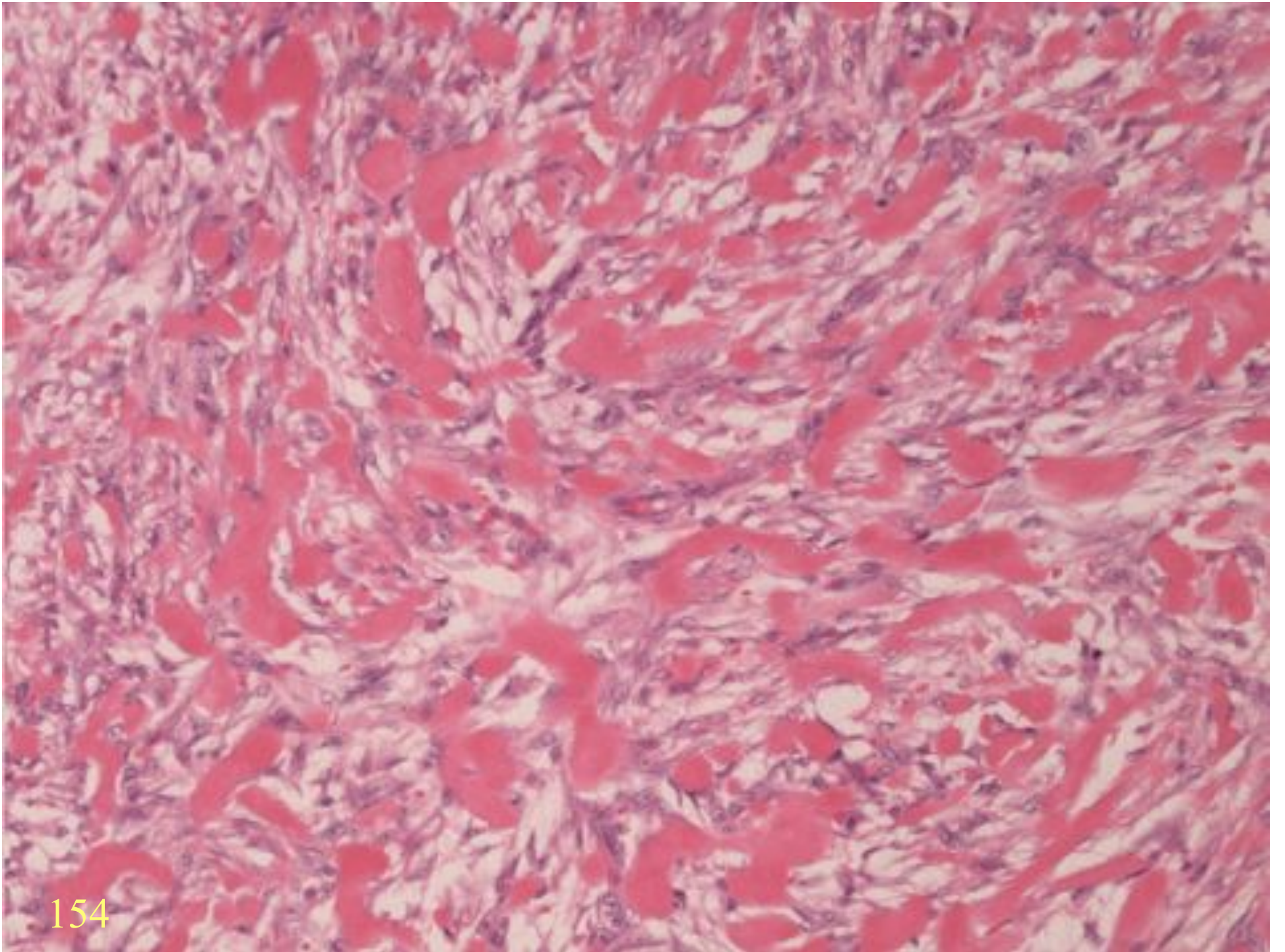
- Spindled cells
- Produce extracellular fibres (collagen & elastin)
- Produce ground substance (glycosaminoglycans)

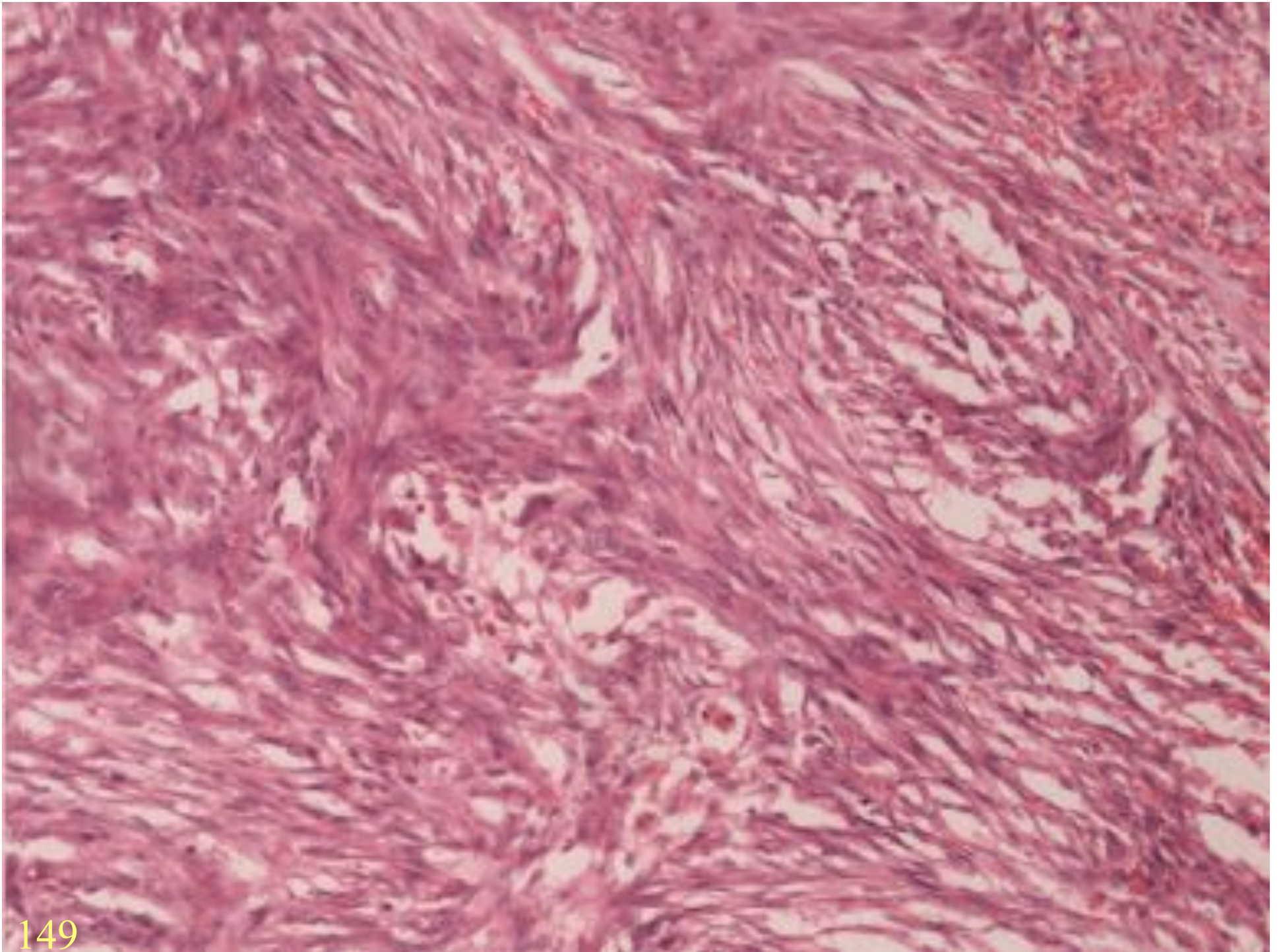


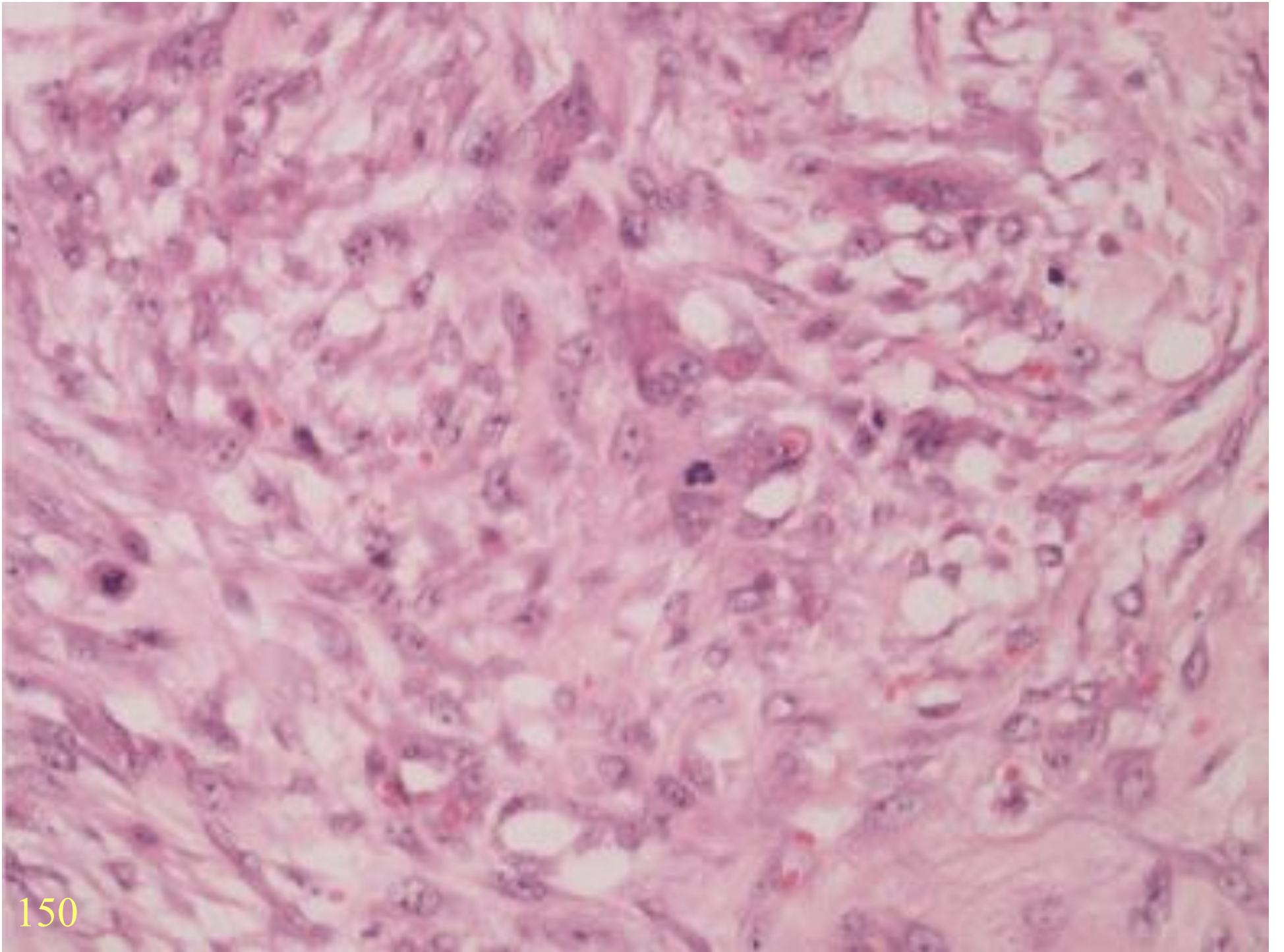
NODULAR FASCIITIS

- Young adults
- Growth over a few weeks
- Forearm
- Fascia, subcutis, muscle







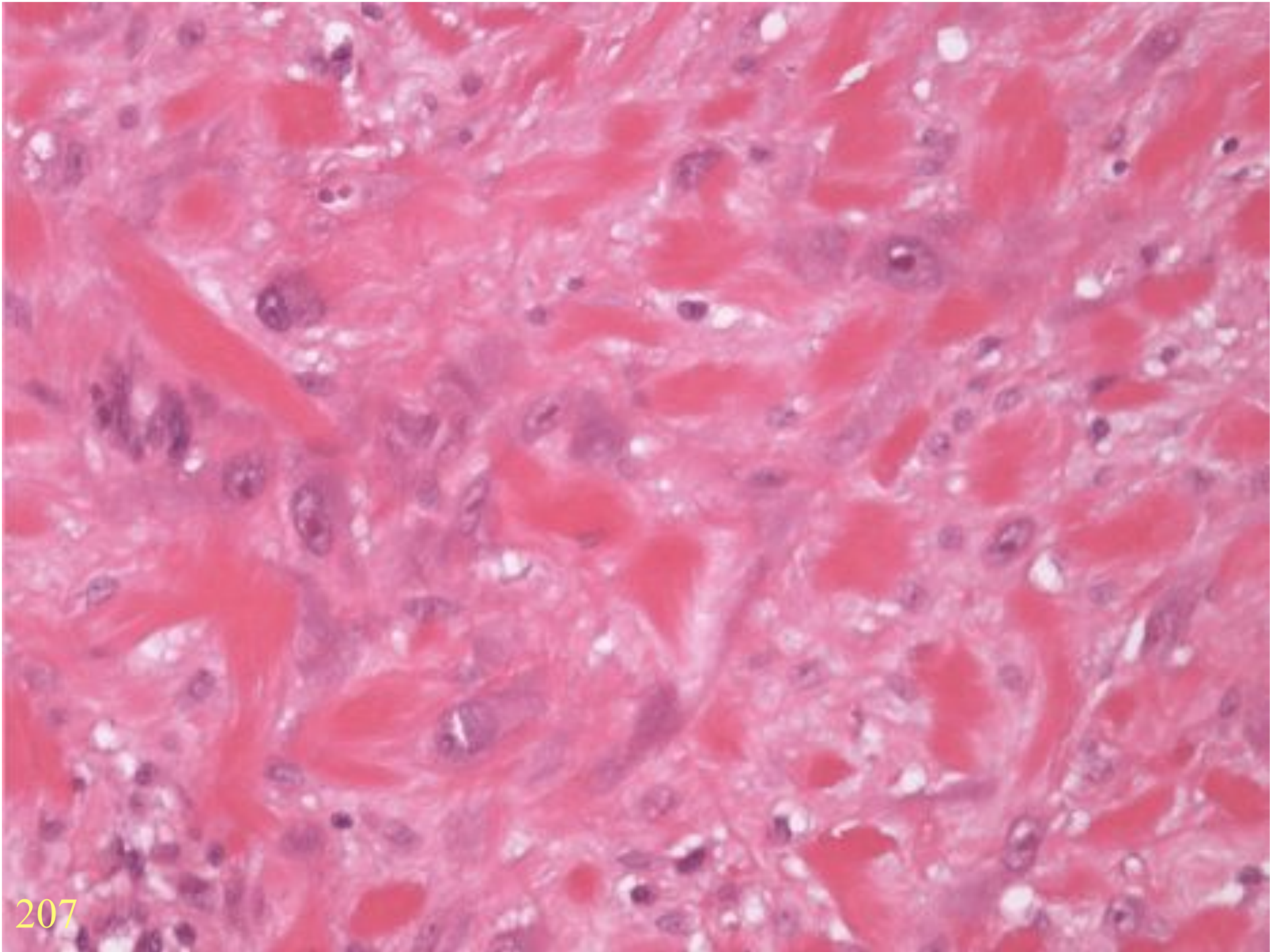


NF VARIANTS

- Dermal fasciitis
- Intravascular fasciitis
- Cranial fasciitis

PROLIFERATIVE FASCIITIS

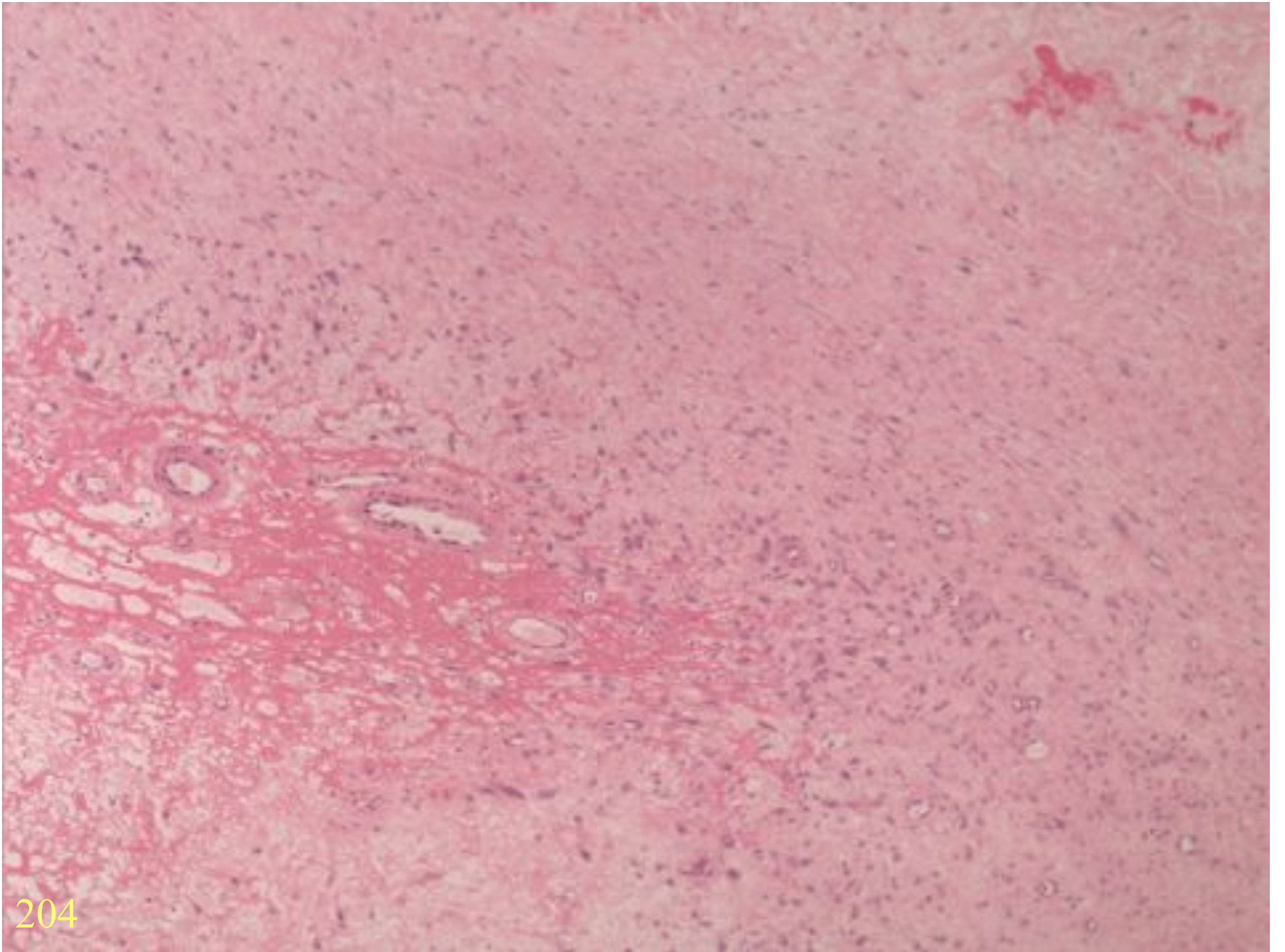
- Middle-aged adults
- Subcutis of extremities
- Rapid growth
- Proliferative myositis (flat muscles of trunk/shoulder)

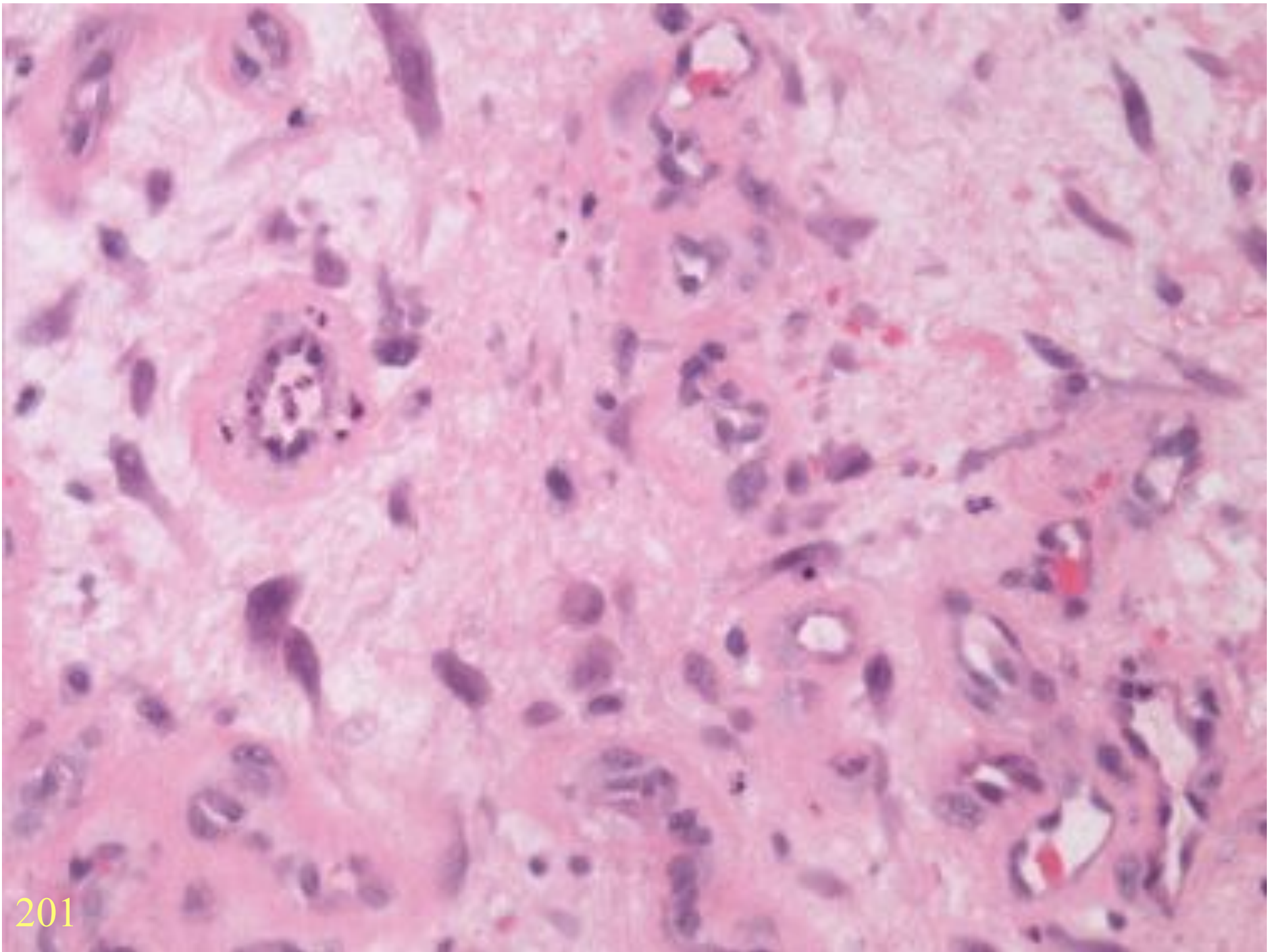


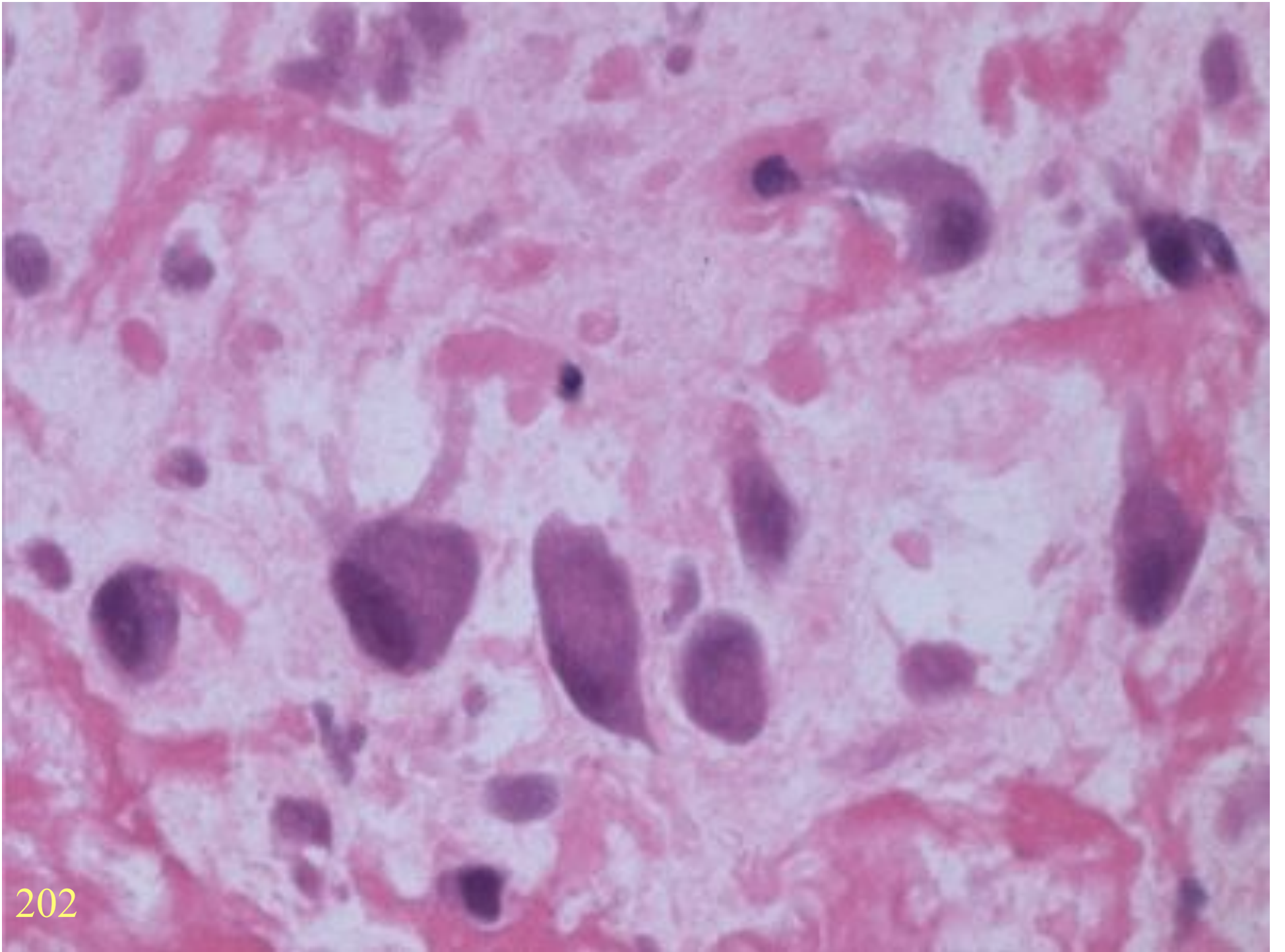
ISCHAEMIC FASCIITIS

(Atypical decubital fibroplasia)

- Elderly
- Pressure points
- Subcutis
- No ulceration

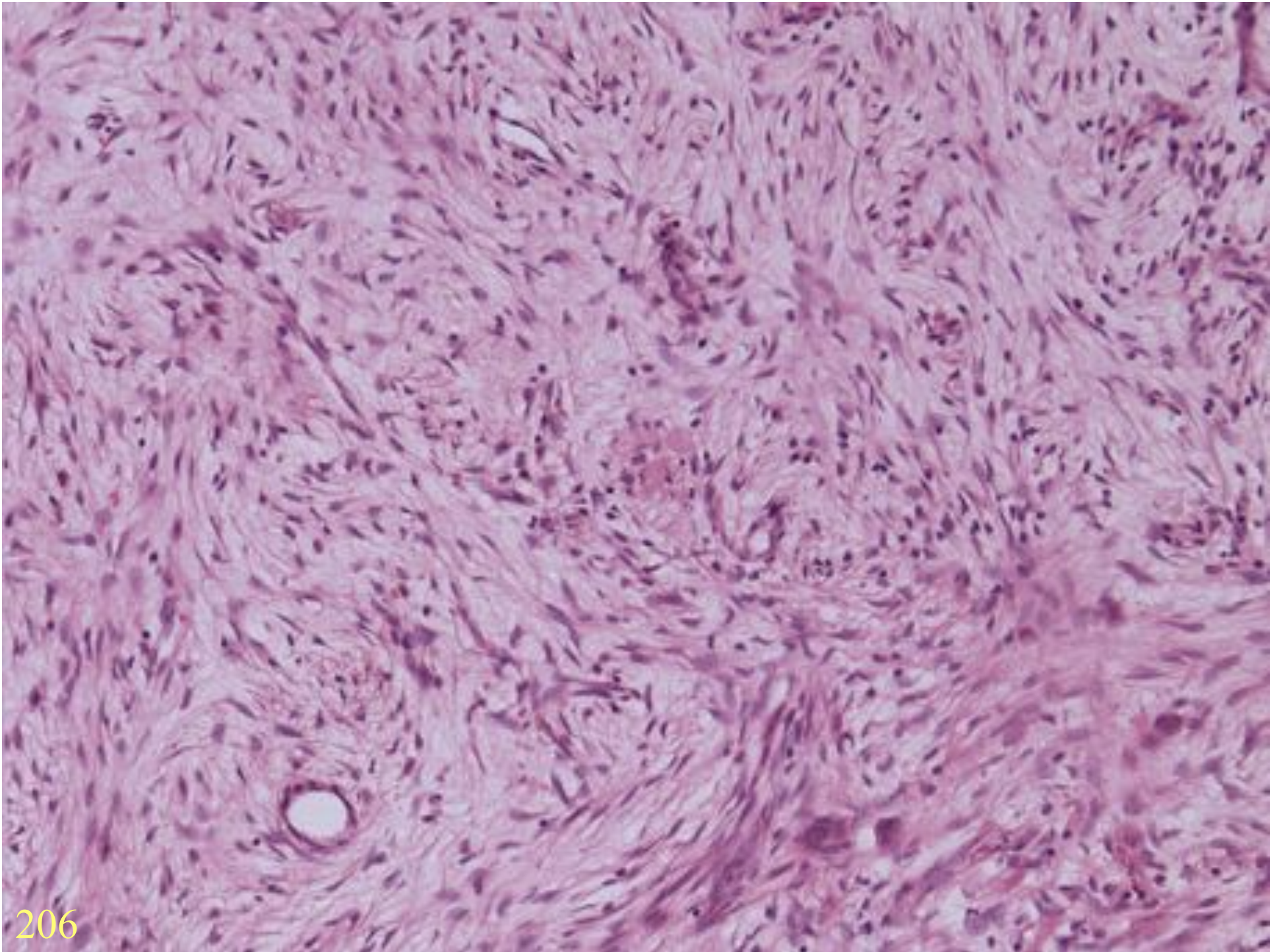


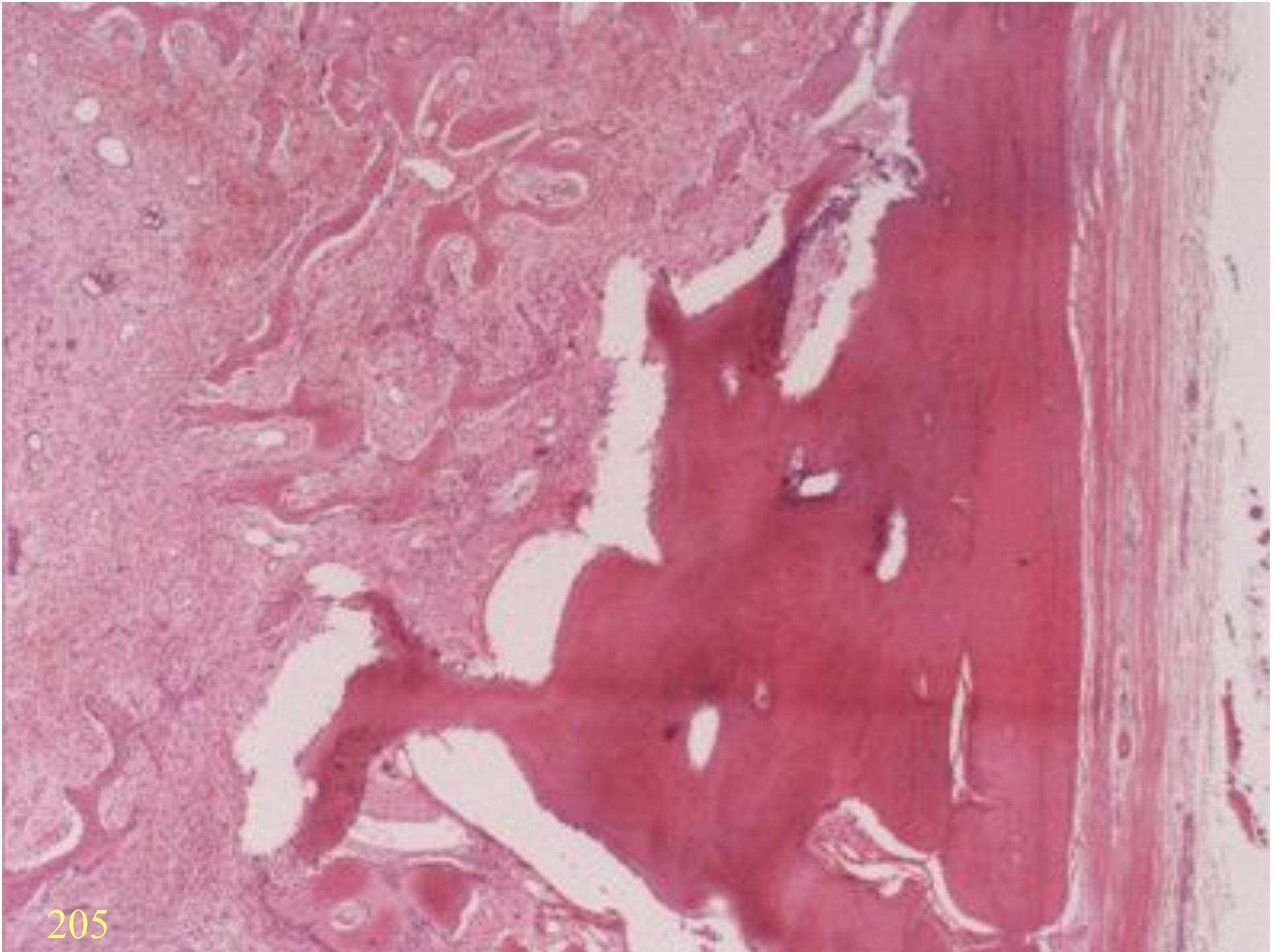




202

MYOSITIS OSSIFICANS





PSEUDOSARCOMATOUS MYOFIBROBLASTIC PROLIFERATIONS

- Urinary bladder
- 25% previous trauma
- Reactive fibroblasts
- Muscle markers positive
- Often cytokeratin positive
- Sometimes ALK positive

FIBROBLASTIC LESIONS

SUMMARY

- Nodular fasciitis
- Proliferative fasciitis
- Ischaemic fasciitis
- Pseudo-sarcomatous myofibroblastic proliferations