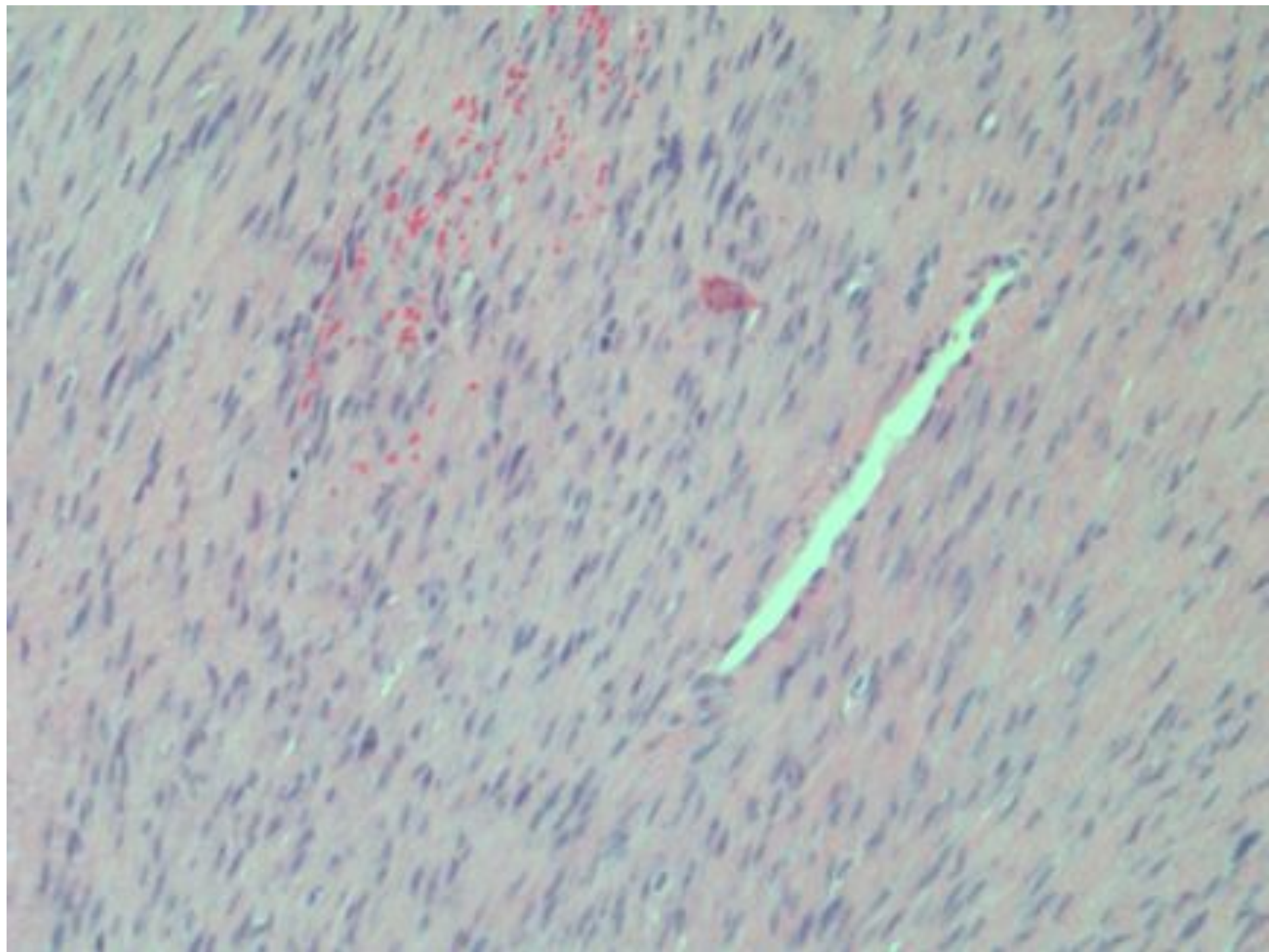


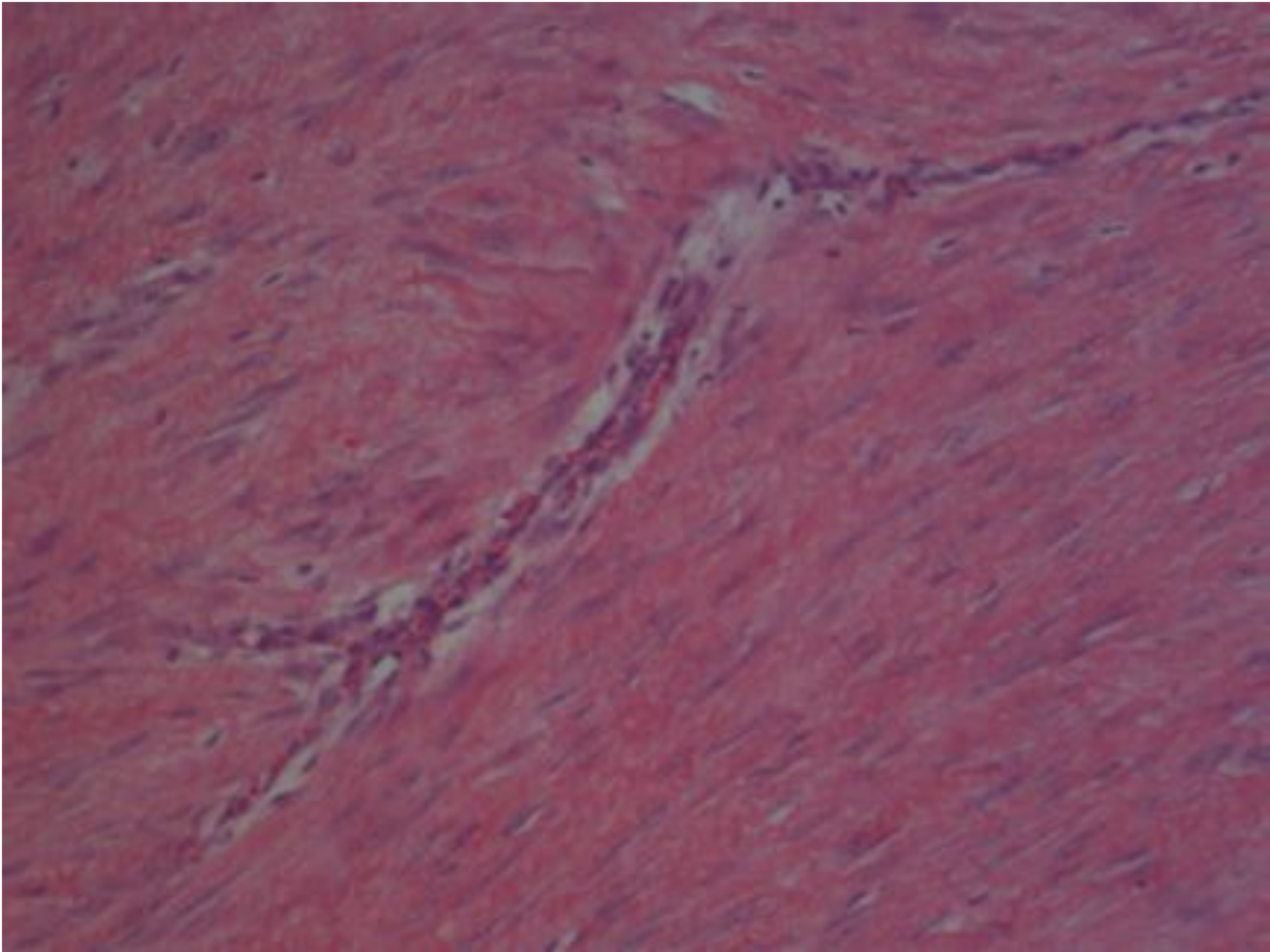
FIBROMATOSIS

- Superficial
- Deep



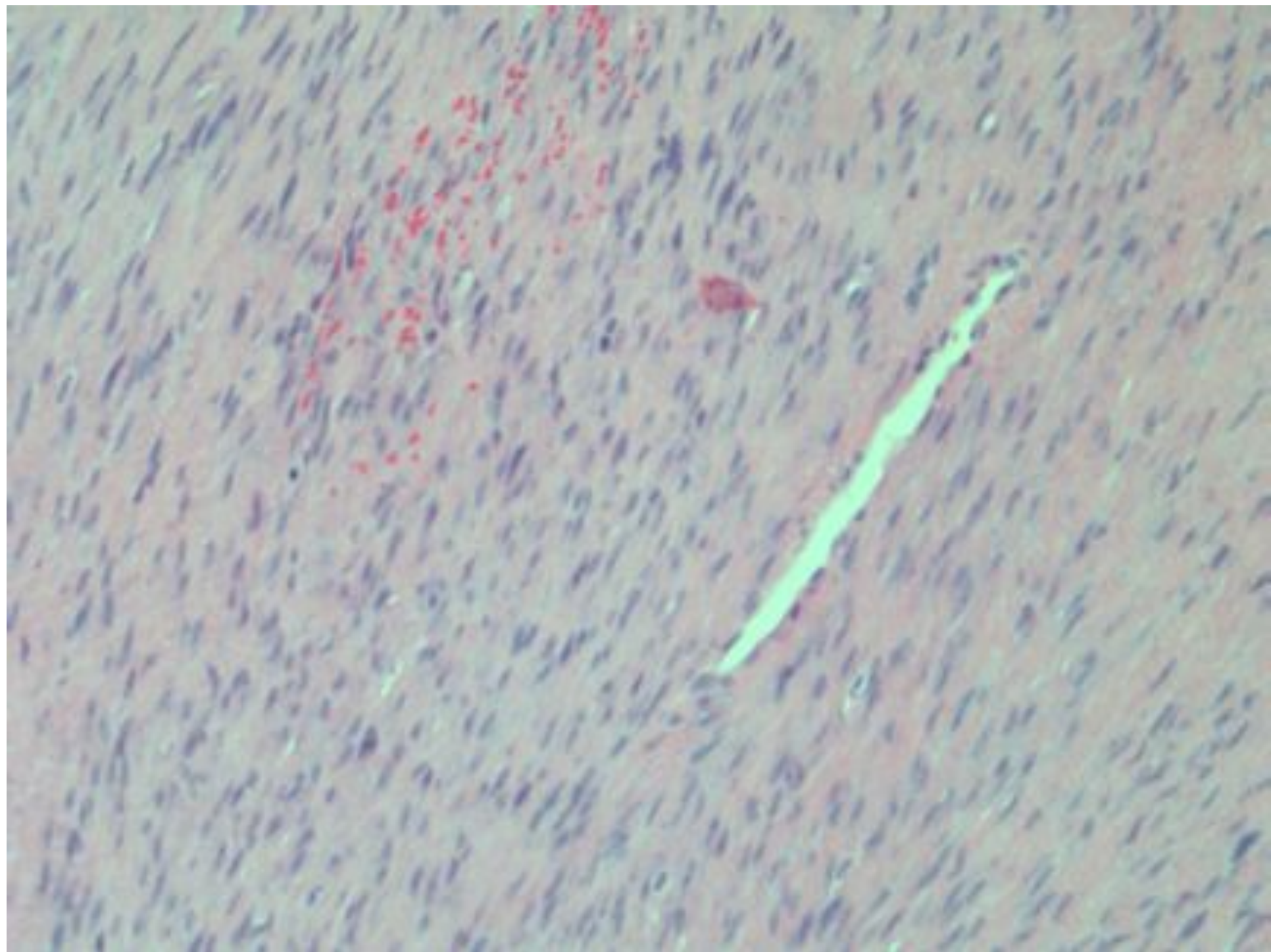
SUPERFICIAL FIBROMATOSIS

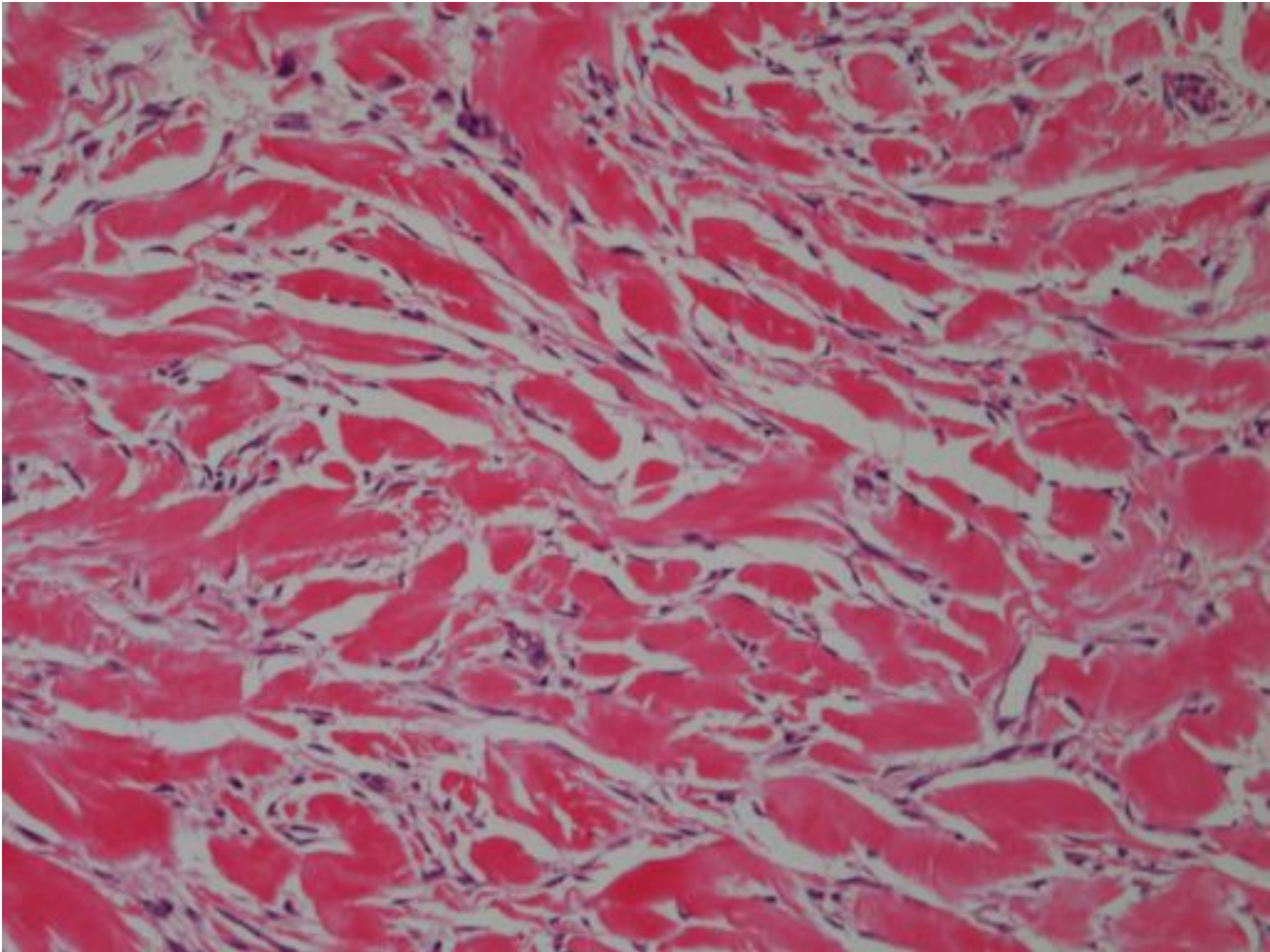
- Palmar (Dupuytren's Contracture)
- Plantar (Ledderhose's disease)
- Knuckle pads
- Penile (Peyronie's disease)



DEEP MUSCULO- APONEUROTIC (Desmoid) FIBROMATOSIS

- Extra-abdominal (shoulder, chest wall, thigh)
- Abdominal (mostly young women)
- Intra-abdominal (Gardner's Syndrome/FAP)
- Potentially aggressive – not all are



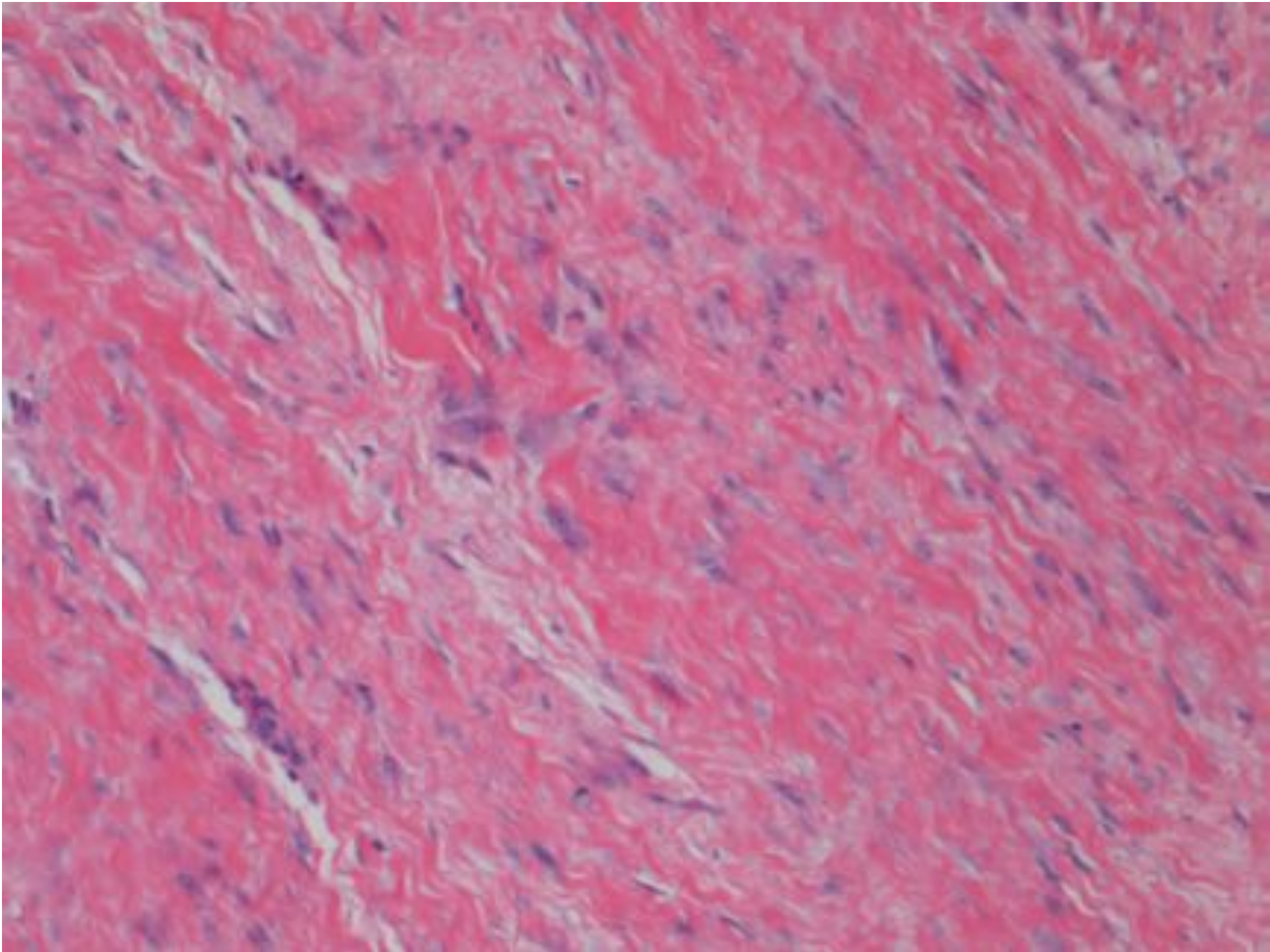


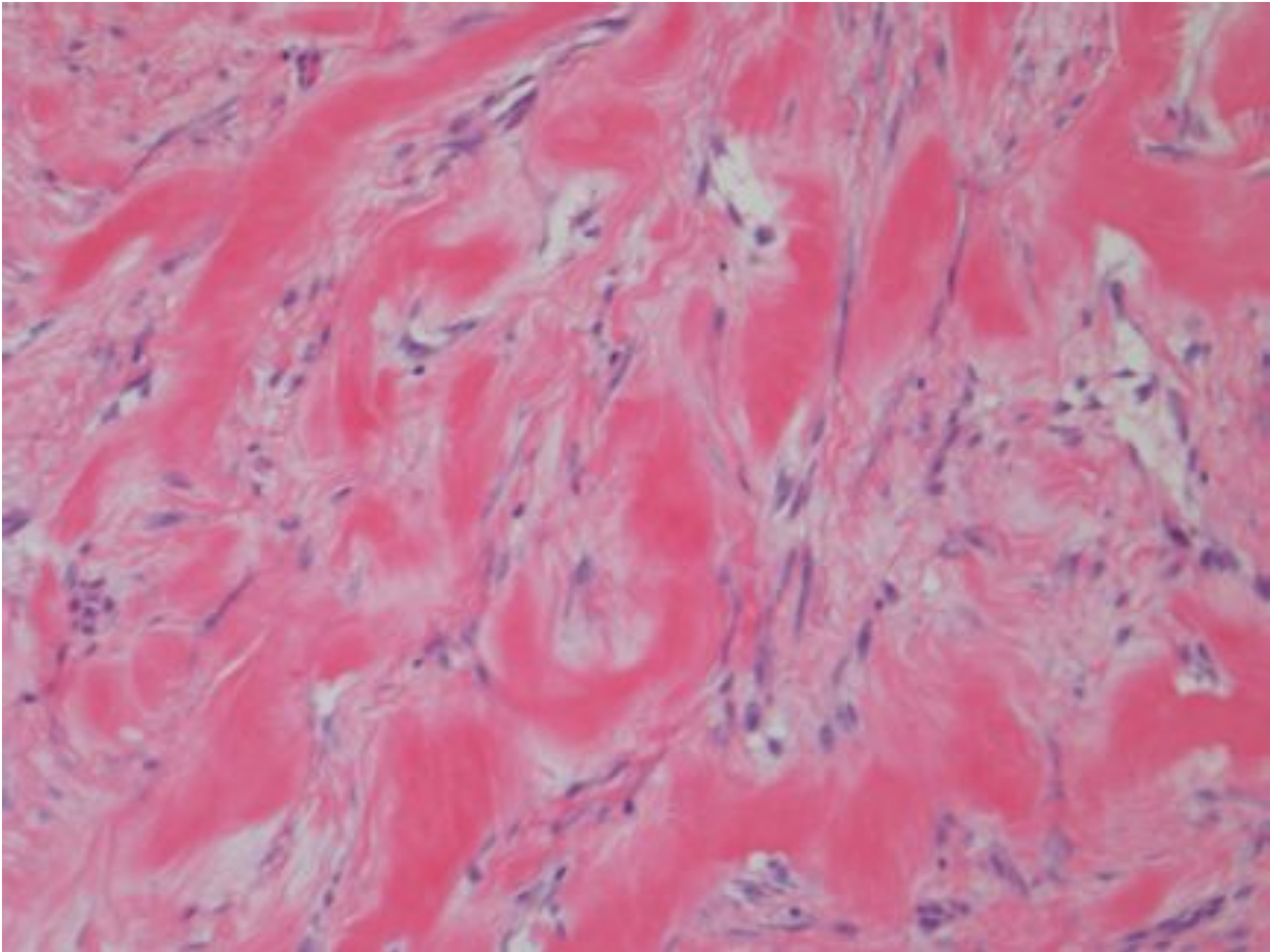
MULTICENTRIC FIBROMATOSIS

- 5% of extra-abdominal fibromatoses
- Typically in one anatomical region
- Second growth proximal to first growth

FIBROMATOSIS DIFFERENTIAL

- Fibrous scarring





INFANTILE DIGITAL
FIBROMATOSIS

