Disease of the Oesophagus

Dr Tim Bracey

MBChB PhD MRCS FRCPath

Consultant Pathologist

Lead Pathologist for Regional Oesophagogastric cancer Centre

Welcome to the Plymouth Oesophago-Gastric Cancer Centre

Plymouth Hospitals NHS
NHS Trust

Executive Summary

Patient experience, as defined by outcomes and satisfaction levels, is high at the Centre.

A total of 129 patients have undergone surgical resection in the last 12 months at the surgical centre. There were 94 oesophagectomy and 35 gastrectomy procedures performed, with in-hospital mortality rates of 1.1% and 5.7% respectively – 2.3% overall.

The National Oesophago-gastric Cancer Audit 2010 describes in detail the findings of the first national audit of oesophago-gastric cancer care in England and Wales, and provides useful benchmark data. The overall post-operative in-hospital mortality for 3,612 oesophageal and gastric resections from this audit was 5.1% in England and Wales. For the 2,200 oesophageal and 1,412 gastric resections nationally it was 4.5% and 6.0% respectively.

- One of the biggest units in the country
- All biopsies of suspected OG cancers/HG dysplasia from 5 hospitals reviewed with radiology and endoscopic findings

Disease of Oesophagus Outline

- Anatomy of oesophagus
- 2 case studies to illustrate common conditions and showing approach to forming differential diagnosis from presenting symptoms and signs
- I will be asking questions along the way, which will be highlighted in this colour

Anatomy of oesophagus

- How long is the oesophagus?
- How many cms is its distal limit on endoscopy?
- What are its upper and lower vertebral levels?
- What are the three anatomical levels where obstruction is most likely to occur?

Anatomy of oesophagus

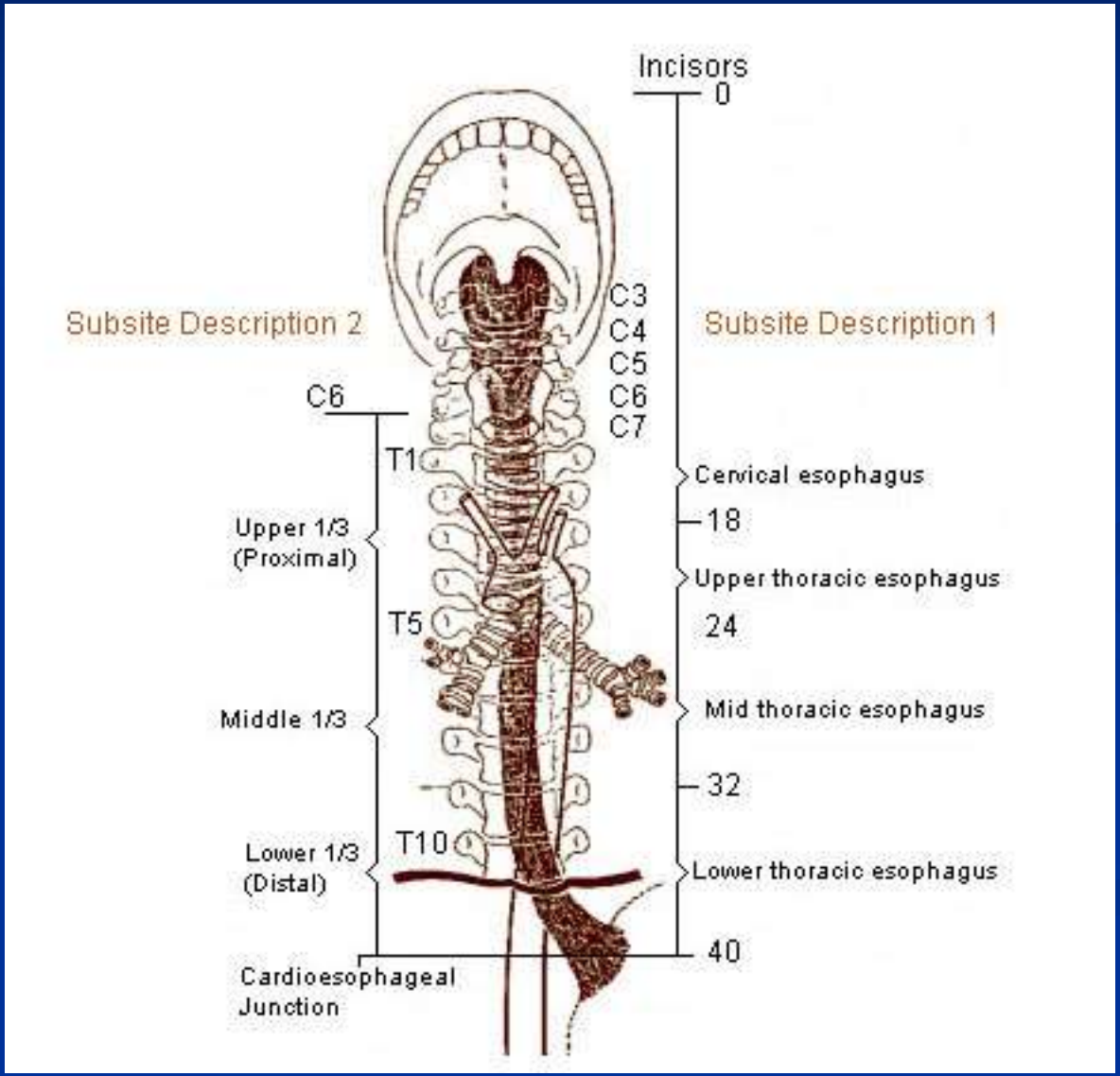

Anatomy (Continued)

- The oesophagus has three distinct areas of naturally occurring anatomic narrowing, where are they?
  - Cervical constriction
    - C6 cricoid cartilage
  - Bronchoaortic constriction
    - T4 sternal angle (“of Louis”)
  - Diaphragmatic constriction
    - T10/T11

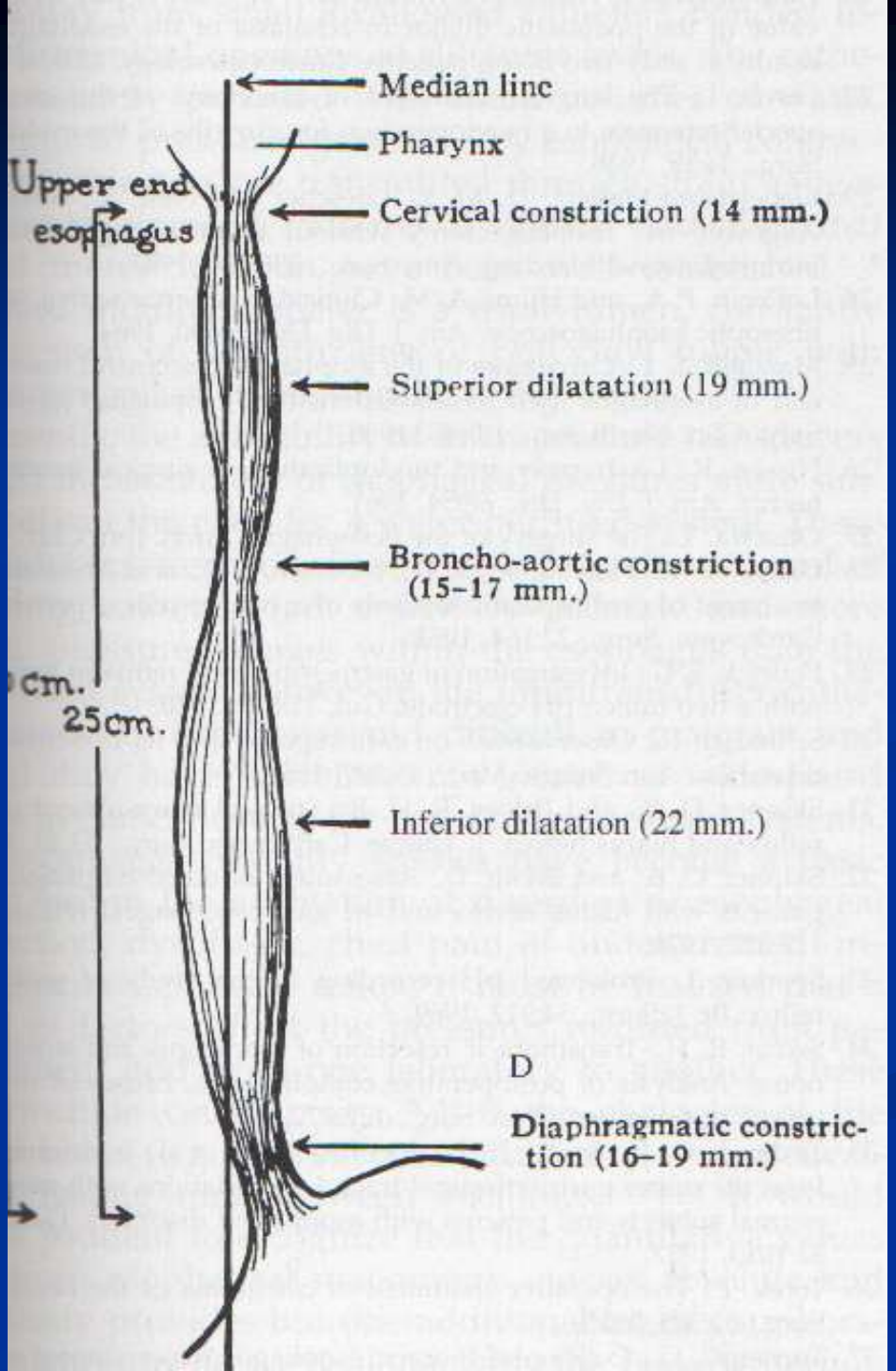

Anatomy (Continued)

- A mucosa-lined muscular tube
- Outer coat of longitudinal muscle that overlies a inner layer of circular muscle
- Upper (two-thirds) layer of muscle striated lower third smooth muscle
- The oesophageal mucosa consists of squamous epithelium except for the distal 1-2 cm
- What is the lining of the distal 1-2cm?
  - Columnar mucus secreting (gastric type) epithelium
  - ….this will become important later!

What are the layers of the normal oesophagus?

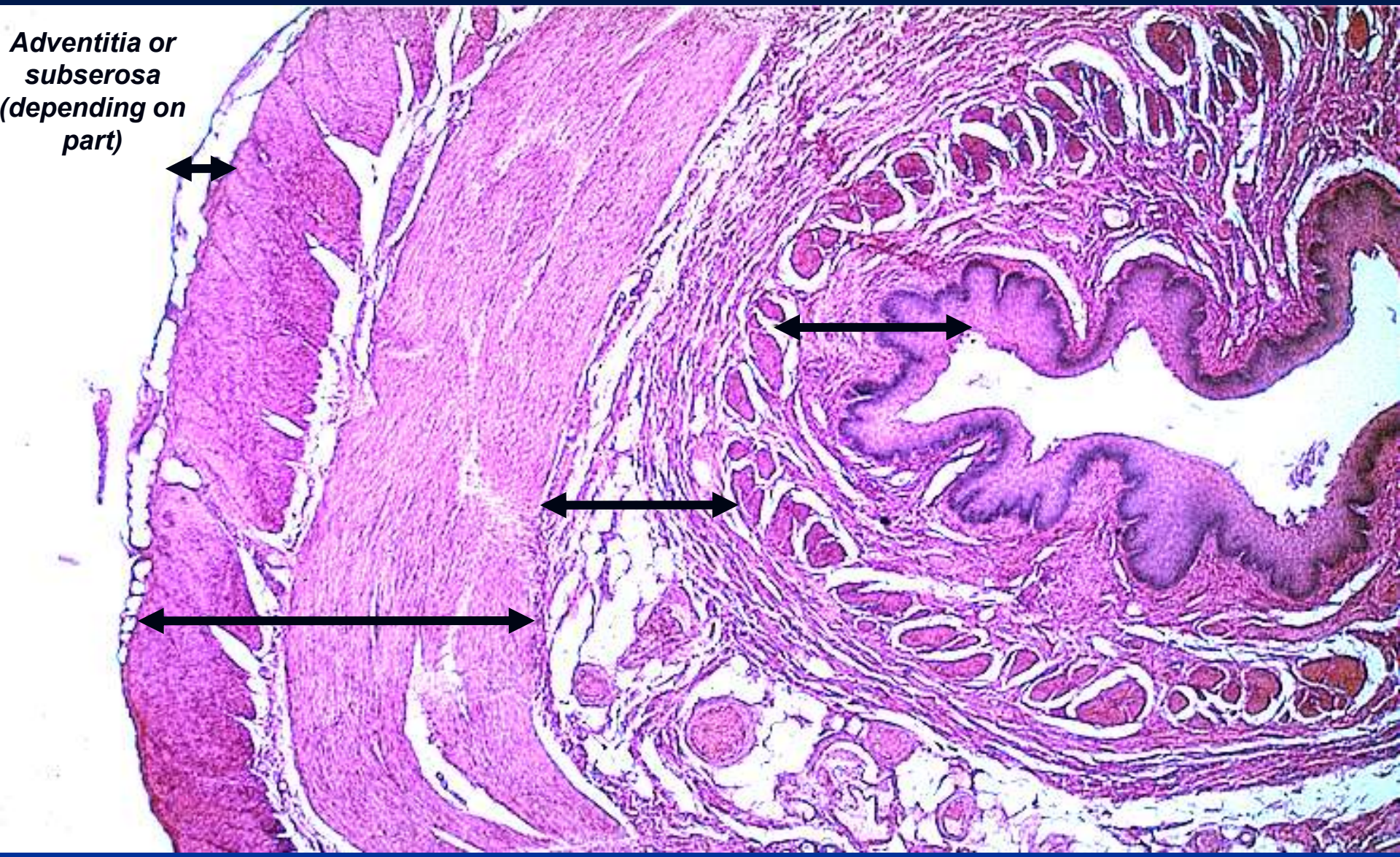

What are the layers of the normal oesophagus?

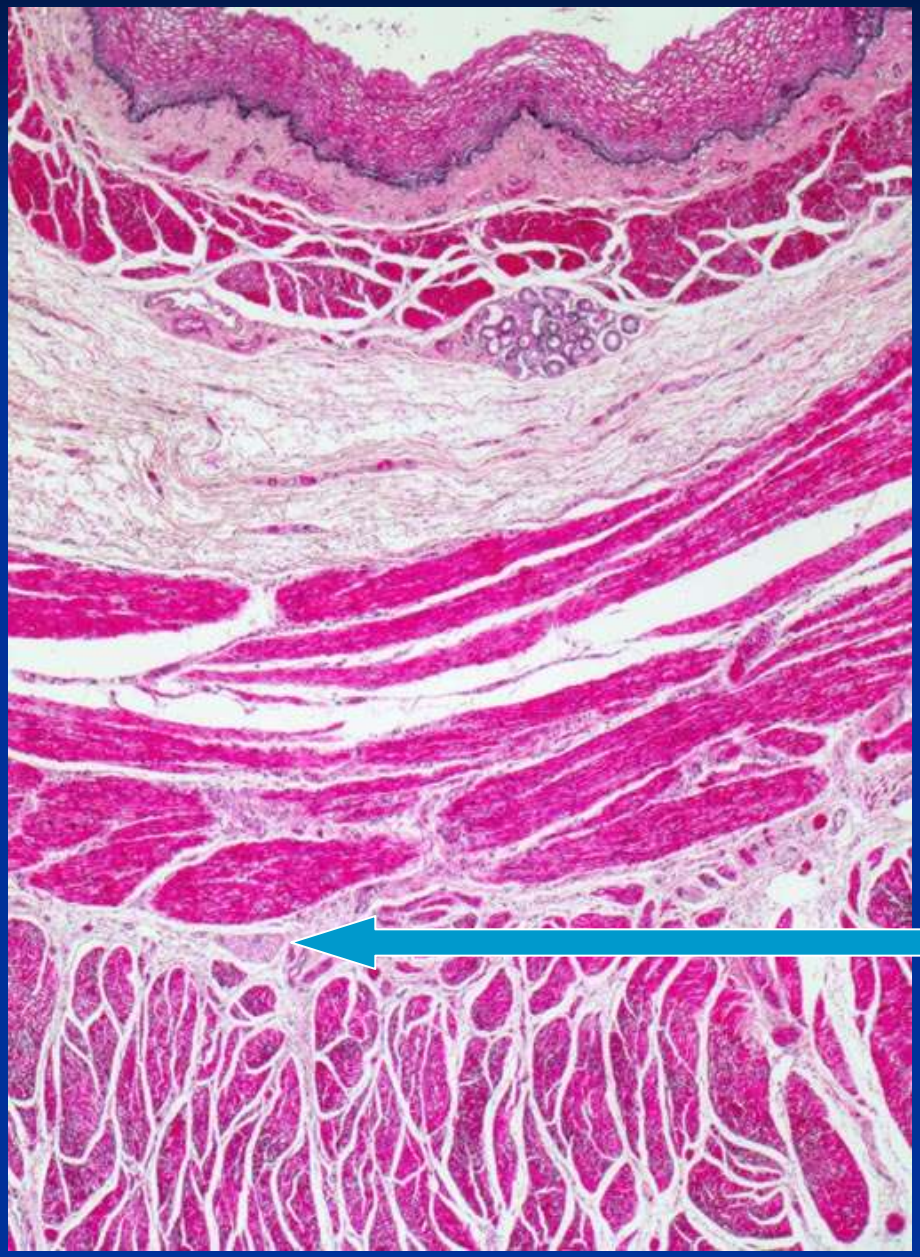

What is the name of this plexus of nerve fibres?

Myenteric plexus

What is the venous drainage of the oesophagus and why is it important clinically?

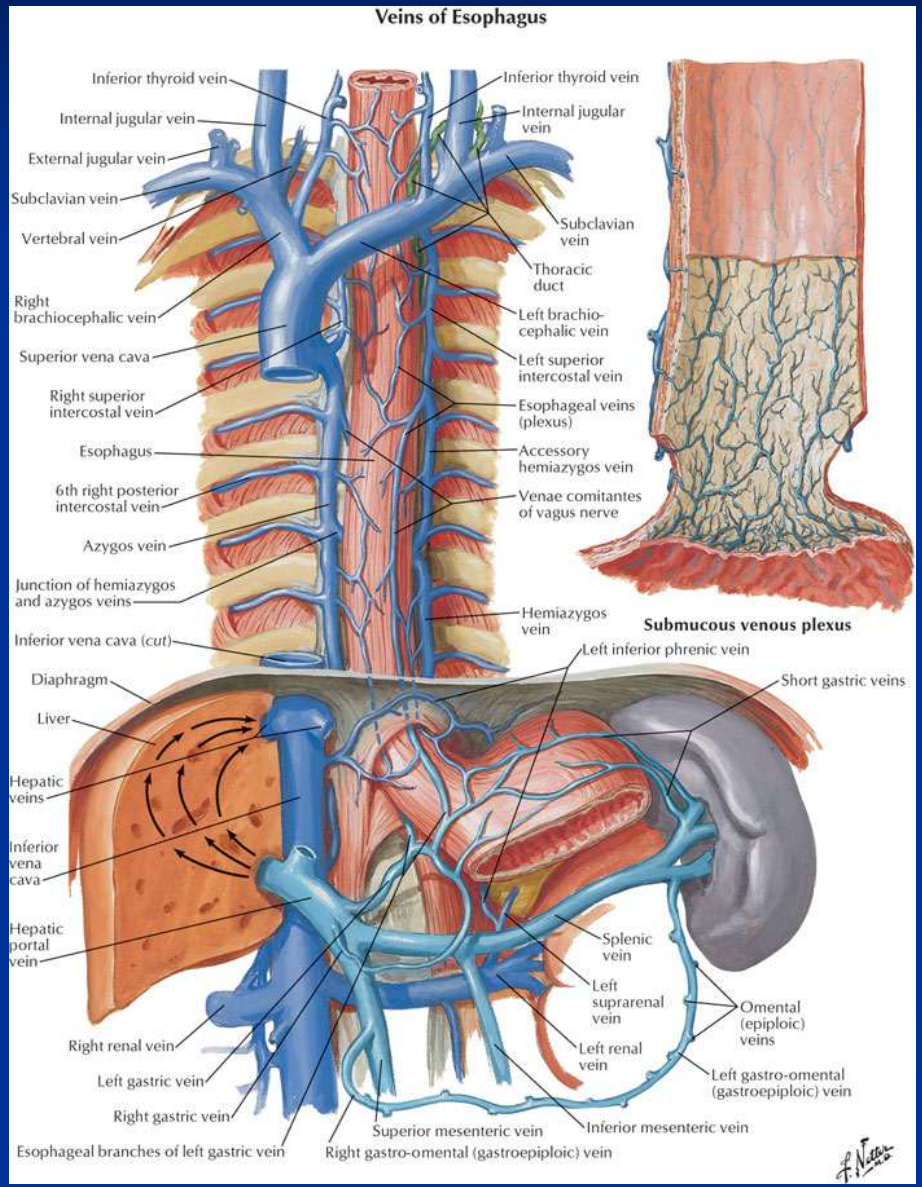

- Upper oesophagus drains into tributaries of azygous vein (systemic circulation)
- Lower portion drains to portal vein. Lower oesophagus is site of *porto-systemic anastamosis*
- Raised portal pressure can lead to…
  - Oesophageal varices
  - Clinical consequences?

Case study 1

- 40 year old male presents with regurgitation of food and dysphagia
- No weight loss

- What are the main differential diagnoses?
- What would you do?
- ABC, full history and examination
- Arrange relevant investigations

Case study 1

- What are the main causes of difficulty swallowing?
  - Congenital
  - Physical obstruction
  - Functional (‘motility disorders’)
  - Infectious / Inflammatory
  - Neoplastic
    - Benign
    - Malignant

How would you investigate the above possibilities?

Case study 1

- Barium swallow showed dilated proximal oesophagus and abrupt tapering “bird-beak” appearance at LOS
- Suggestive of oesophageal achalasia
- What is the next step?

Case study 1

Achalasia:
•Inability of LOS to relax with swallowing due to reduced no. of ganglion cells in myenteric plexus

Etiology: Unknown in most cases
Chaga's disease: Common in South America
•Patient usually present with progressive dysphagia, Wt loss, regurgitation, chest pain.
•CXR: wide mediastinum with air/fluid levels.
•Barium swallow will show "Bird-beak" sign or "Rat Tail" sign .
•Endoscopy is important to rule out neoplasia (pseudoachalasia).
•Treatment is LES balloon dilatation or myotomy.
•There is 5% risk for developing Sq cell carcinoma.

Case study 1

- In this case, biopsy showed mild reflux oesophagitis and no evidence of infectious agent or of malignancy
- The patient was referred for further investigation

Other benign conditions causing dysphagia

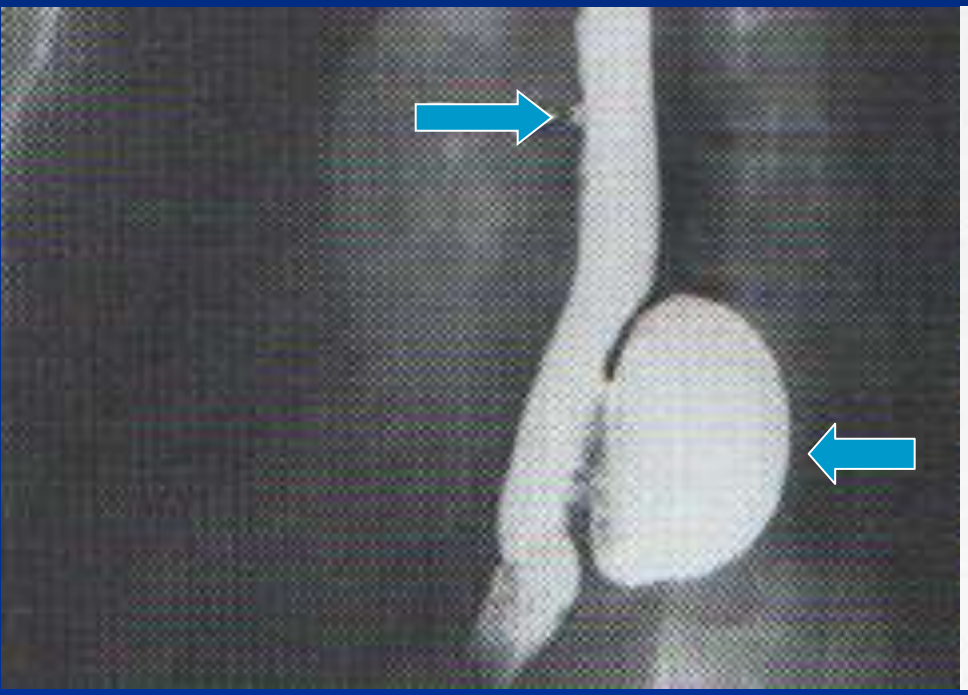

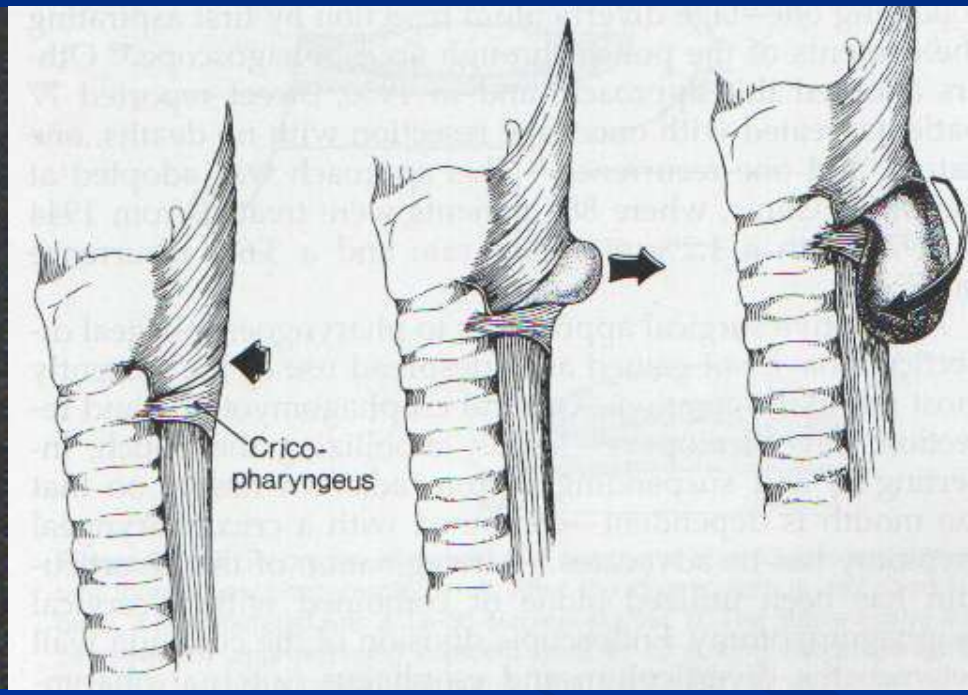

Pharyngoesophageal Diverticula

- The most common oesophageal diverticulum
- Occurs between the ages of 30-50 (believed to be acquired)
- Arise between the fibres of the pharyngeal constrictor muscles
- Complaints are of dysphagia, effortless regurgitation of food or pills sometimes consumed hours earlier
- Sometimes a gurgling sensation in the neck after swallowing
- Surgery is implicated in symptomatic patients regardless of the size of the diverticula

What is this disorder and what is its main clinical consequence?

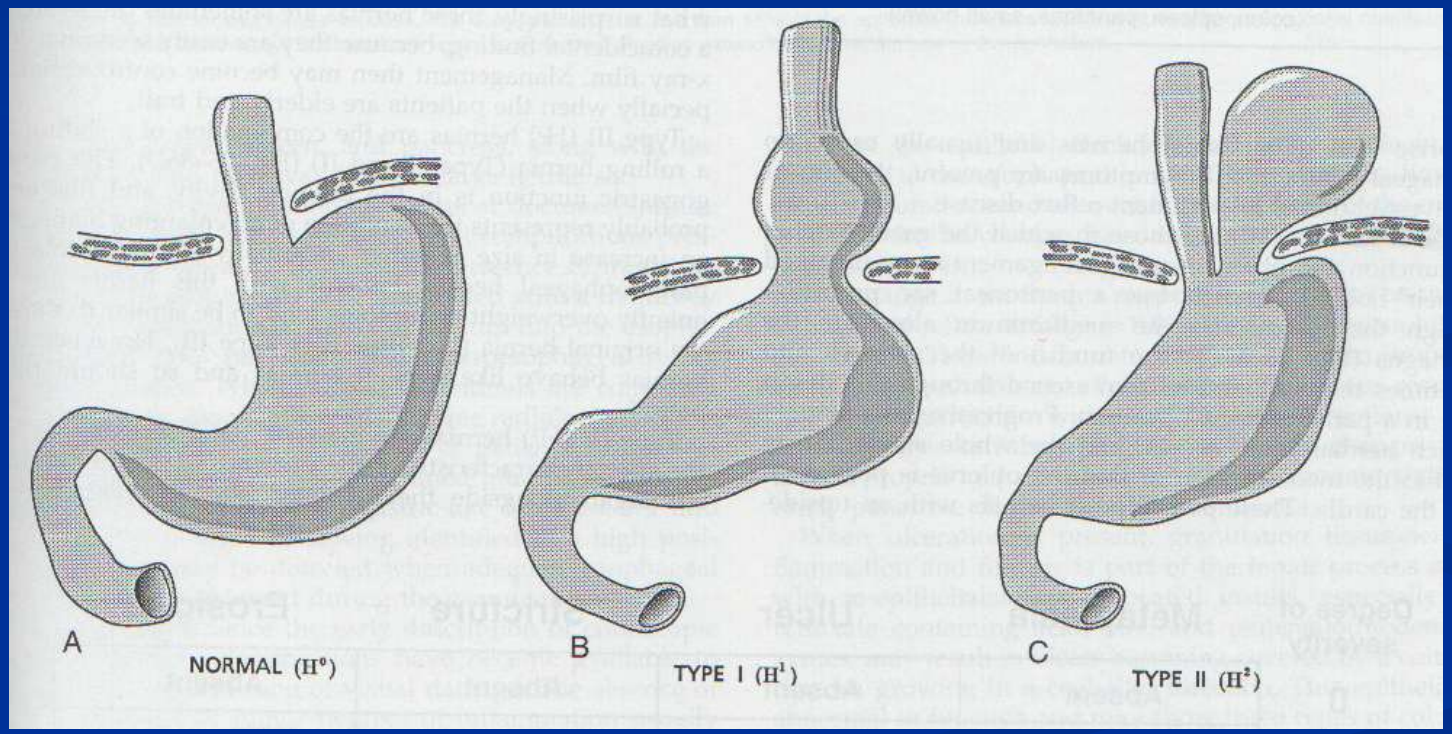

What infections affect the oesophagus?

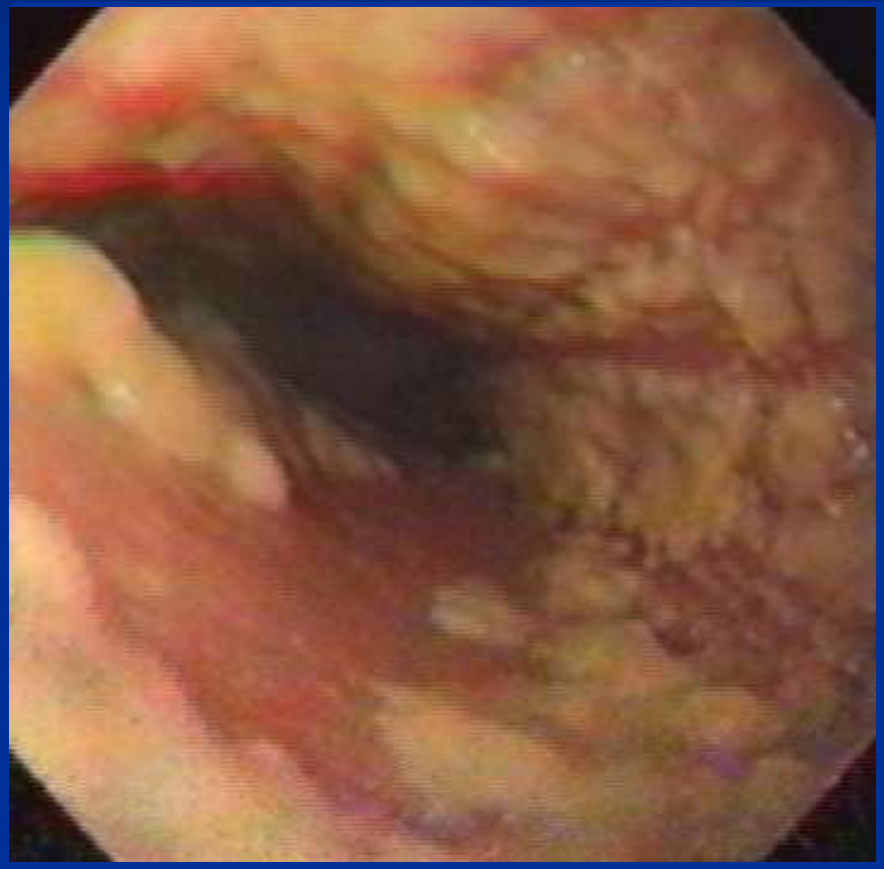

Candida oesophagitis

Note "hyphae" and spores

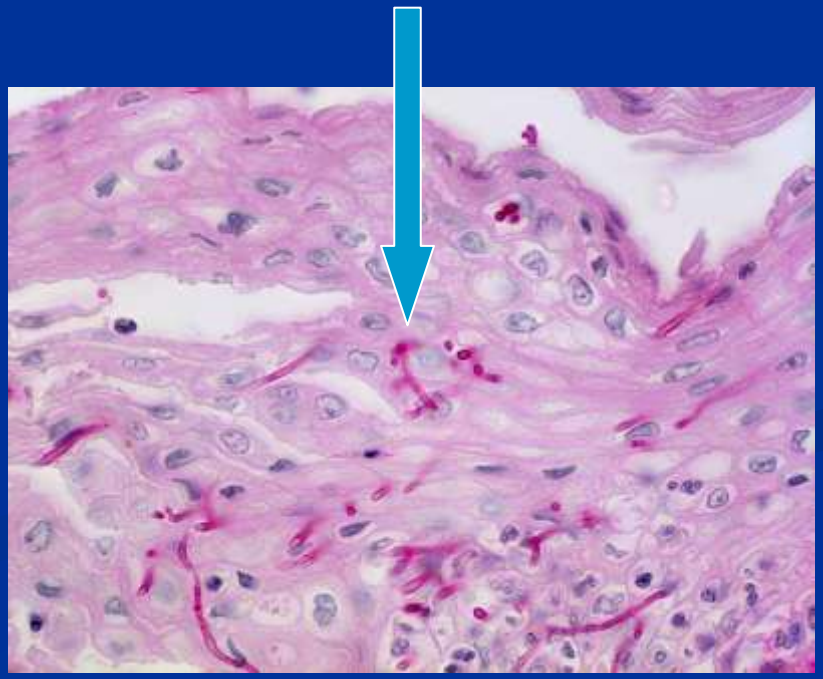

What infections affect the oesophagus?

HSV oesophagitis

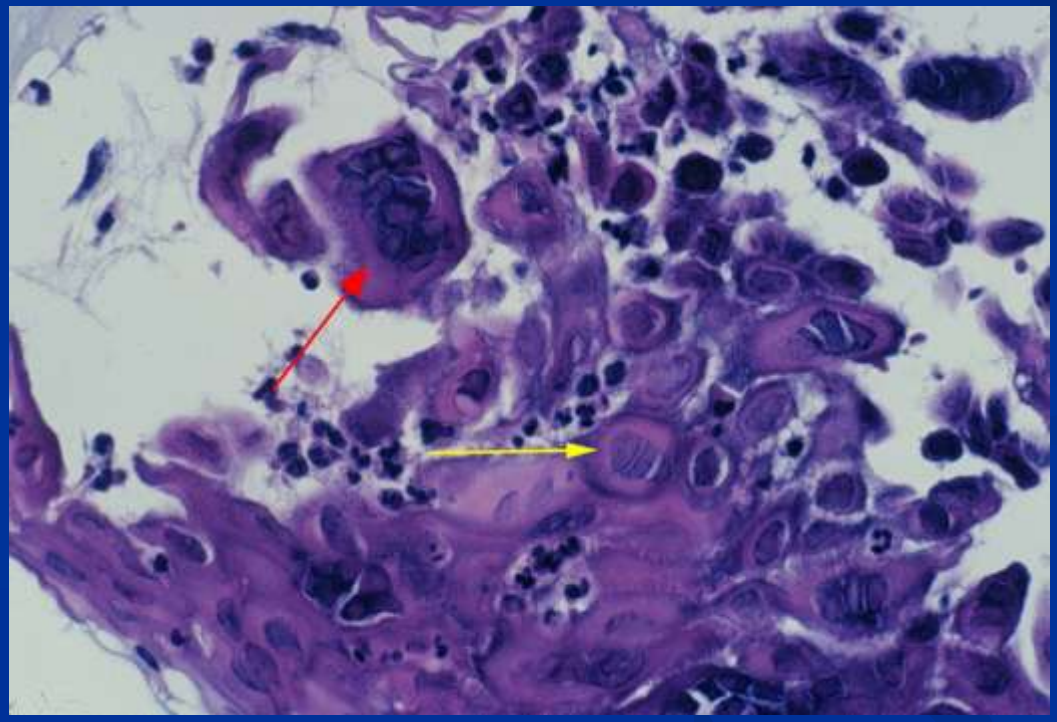

"ground glass nuclear inclusions"

What is this non-infective cause of oesophageal ulceration?

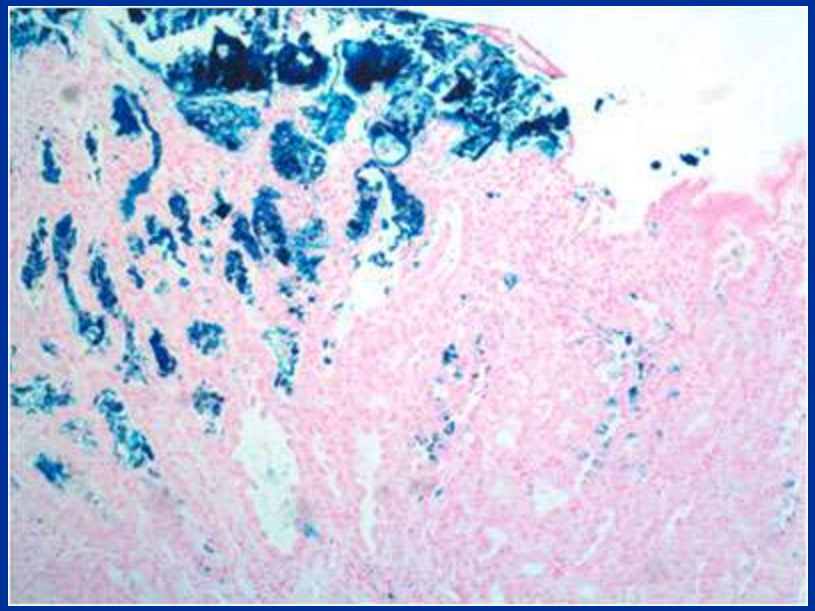

Hint: This is a Perls Prussian Blue stain

Case study 2

- 55 year old white male presents with 7 years history of “heartburn”
- He has been taking ranitidine with some relief
- What is the most likely diagnosis?
- What do you do next?

Case study 2

- An upper endoscopy examination revealed some reddish discoloration and friability of the lower oesophageal region
- Biopsies taken from 36 and 38cm

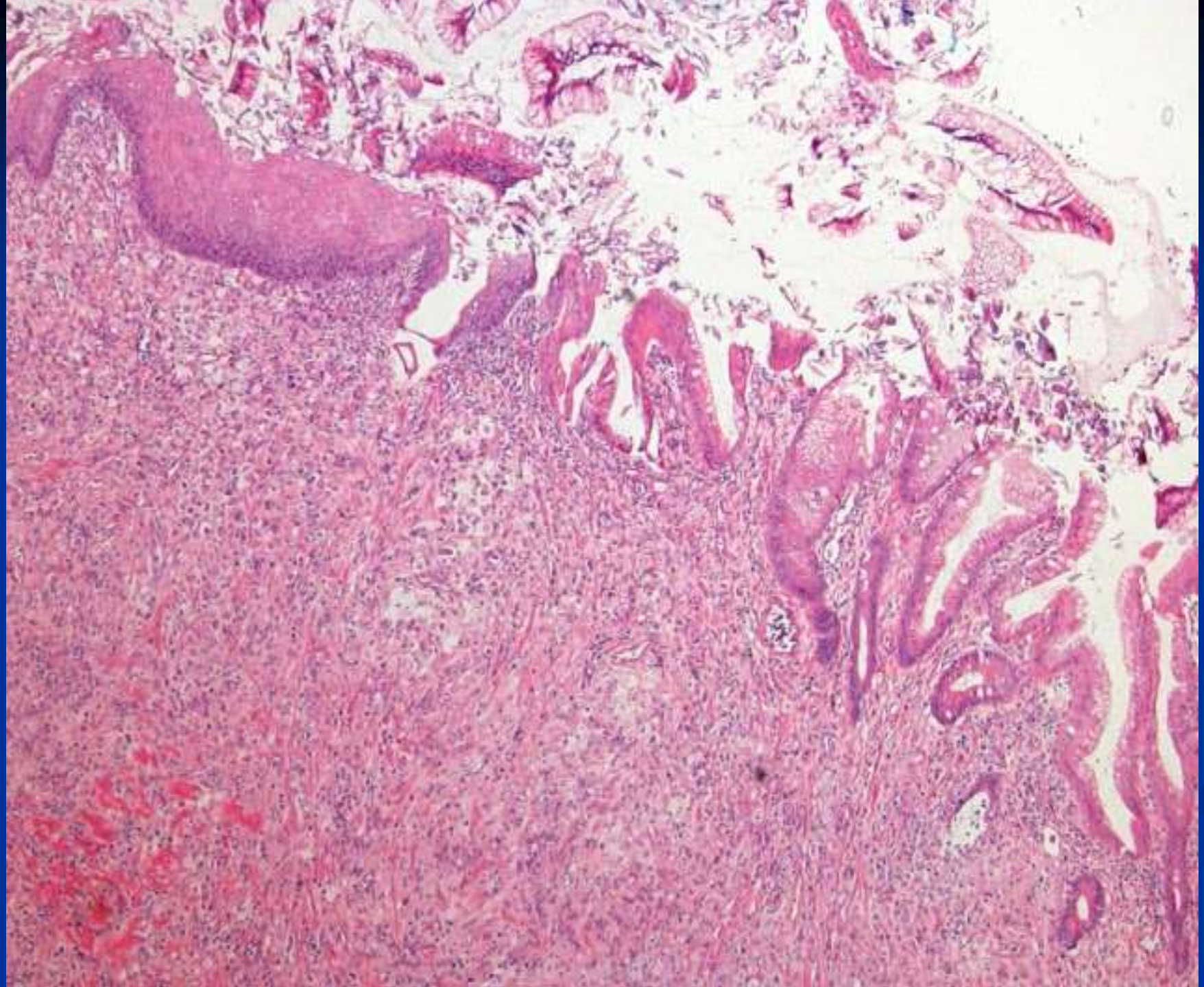

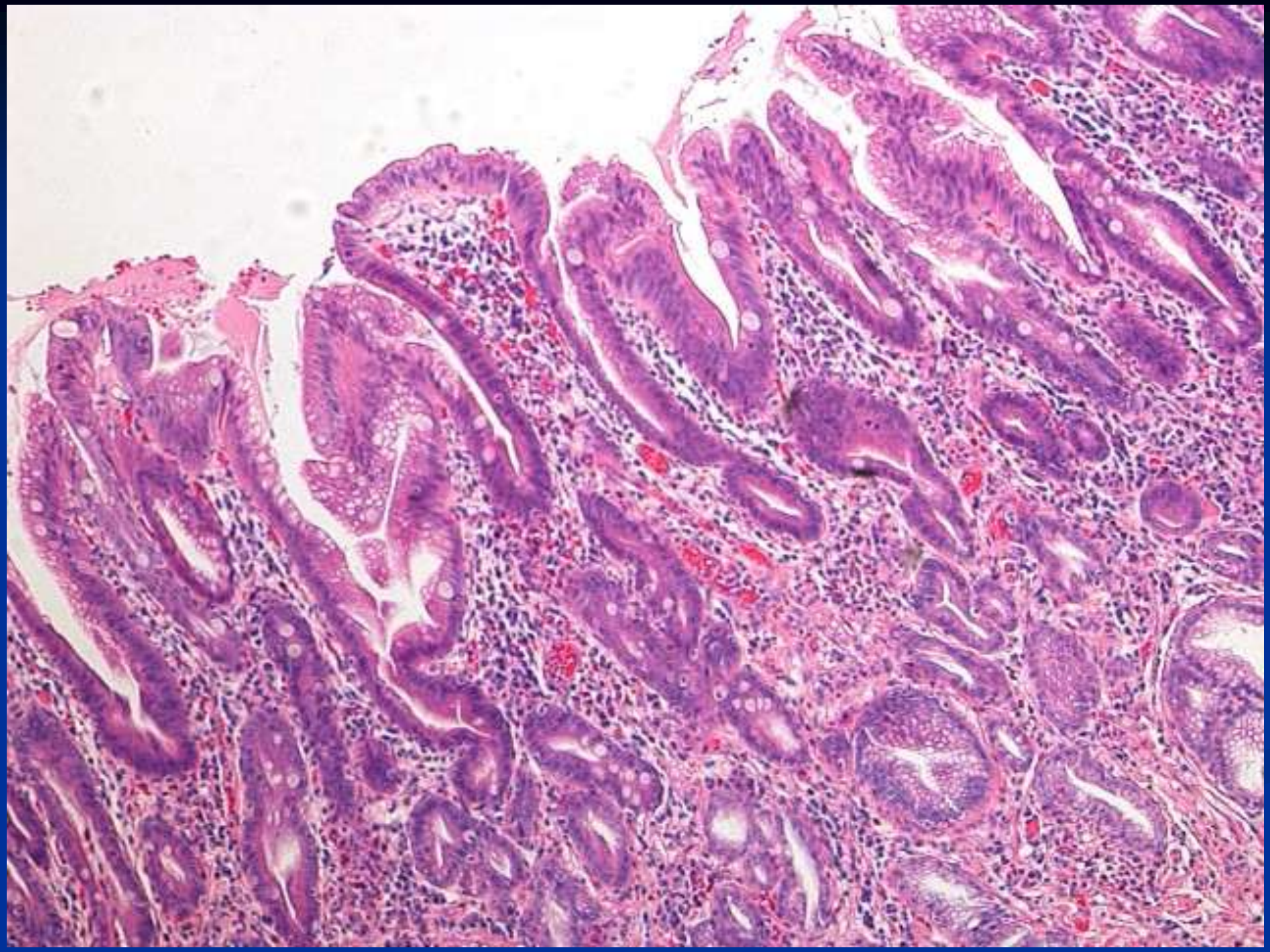

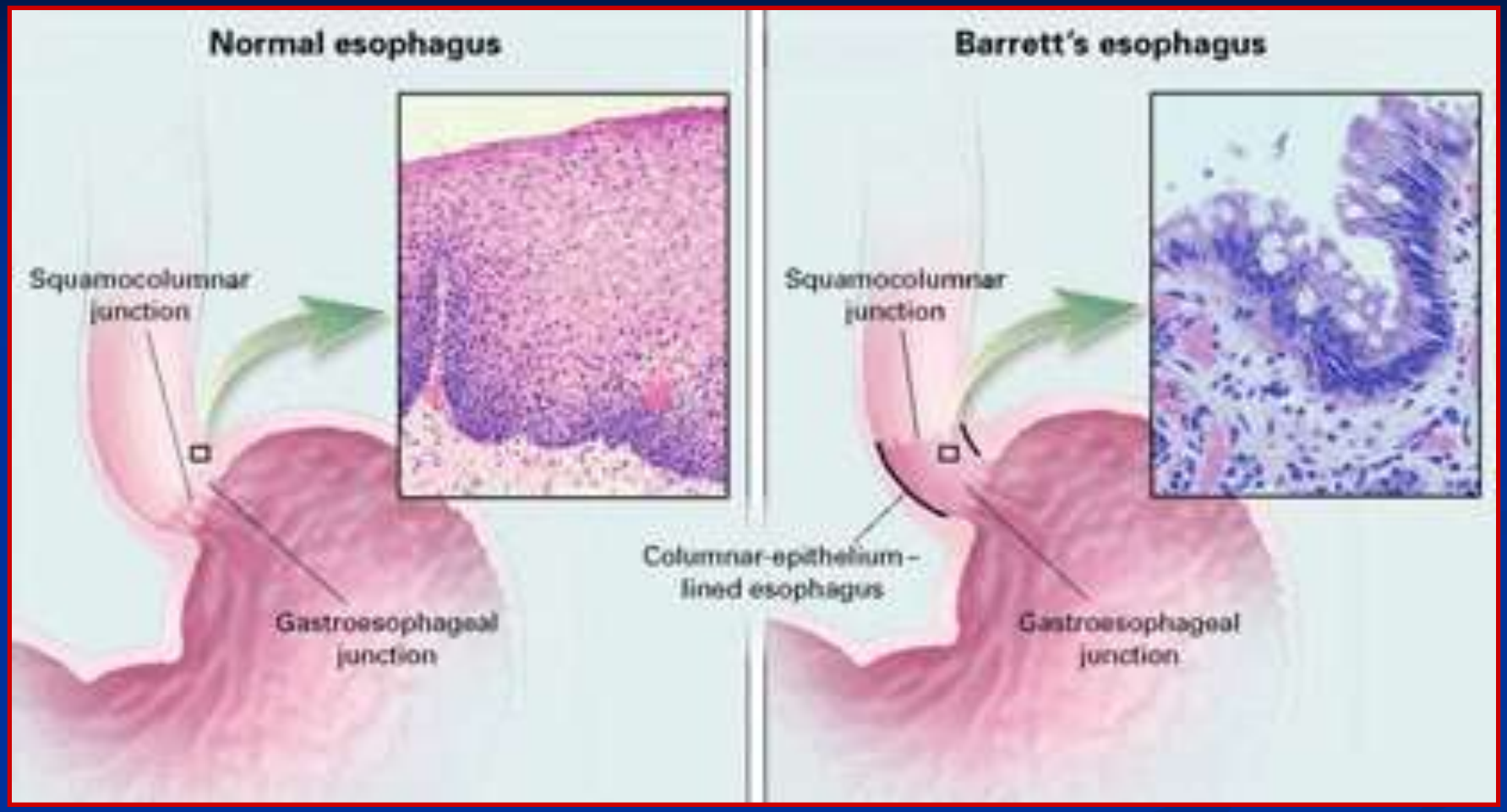

NEJM 2002; 346: 836-842

Histology of Barrett's oesophagus

- Columnar epithelium and specialized intestinal metaplasia

Courtesy of Dr. C. Mel Wilcox

Pathogenesis of Barrett's oesophagus

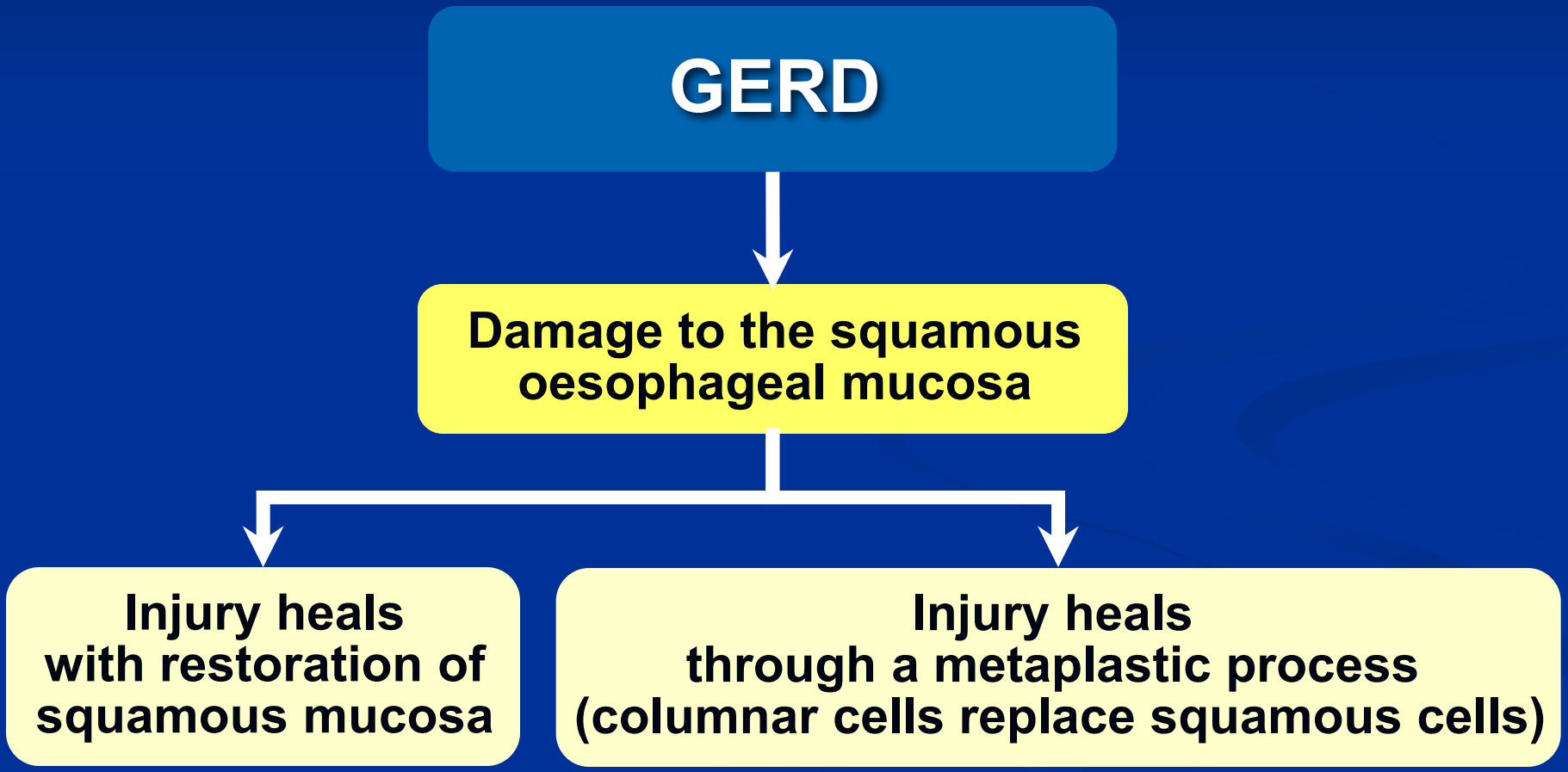

How common is Barrett's oesophagus?

- 6-12% of patients who undergo OGD for GORD.
- Incidental finding in ~1% of patients who undergo OGD
- Most cases go undetected in the general population [Autopsy data]. ~ 5% of patients with Barrett's currently remain undiagnosed

Why do we care about Barrett's oesophagus?

- Patients with Barrett's have an increased risk of developing oesophageal adenocarcinoma.
- Over the past 30 years, the incidence of squamous cell cancer of the oesophagus has stayed constant, while the incidence of adenocarcinoma has increased 6-fold! This is an increase that exceeds that of any other cancer.
- Today, adenocarcinoma accounts for more than half of oesophageal cancers.
- Patients with Barrett's have about a 30-40 fold increased risk of adenocarcinoma of oesophagus

What is the rationale for surveillance for Barrett's Oesophagus (OGD with Bx)

- Endoscopic surveillance can detect dysplasia in BO, which is a further marker of cancer risk:

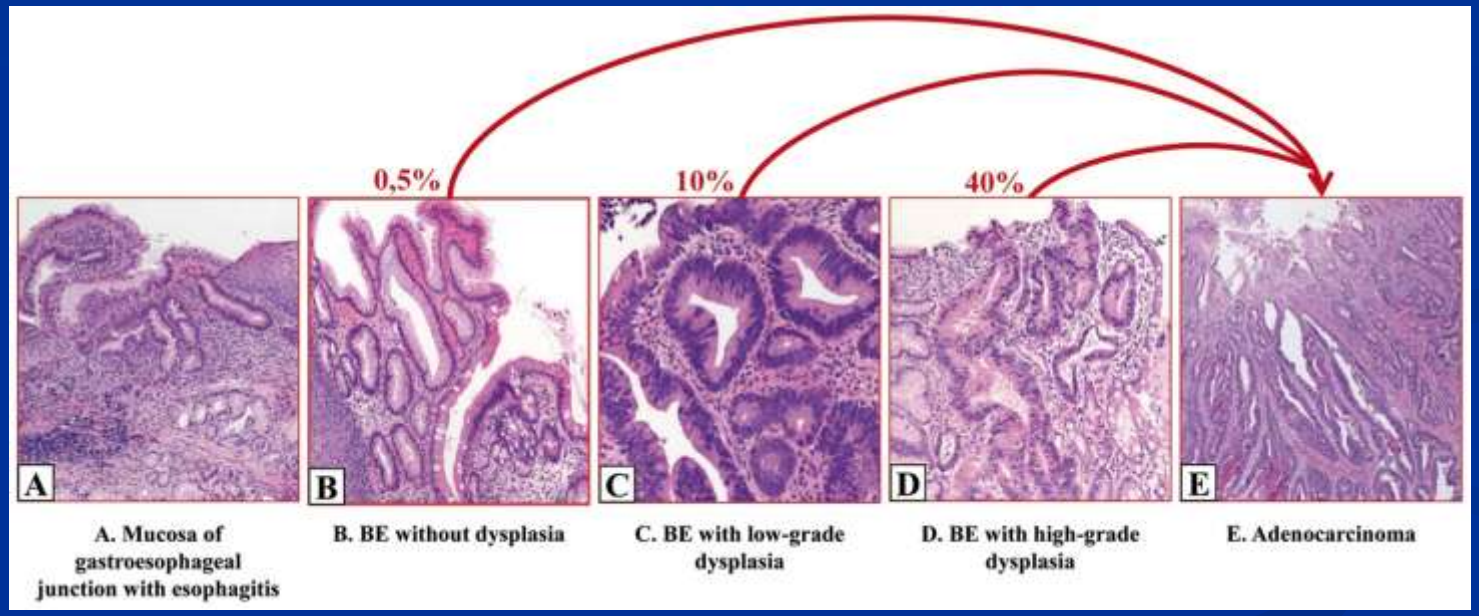

- Asymptomatic cancers detected during surveillance are less advanced than those which present with symptoms. [If wait for symptoms, 5-year survival only 14%.]

Dysplasia results in an abrupt change in morphology compared to adjacent epithelium

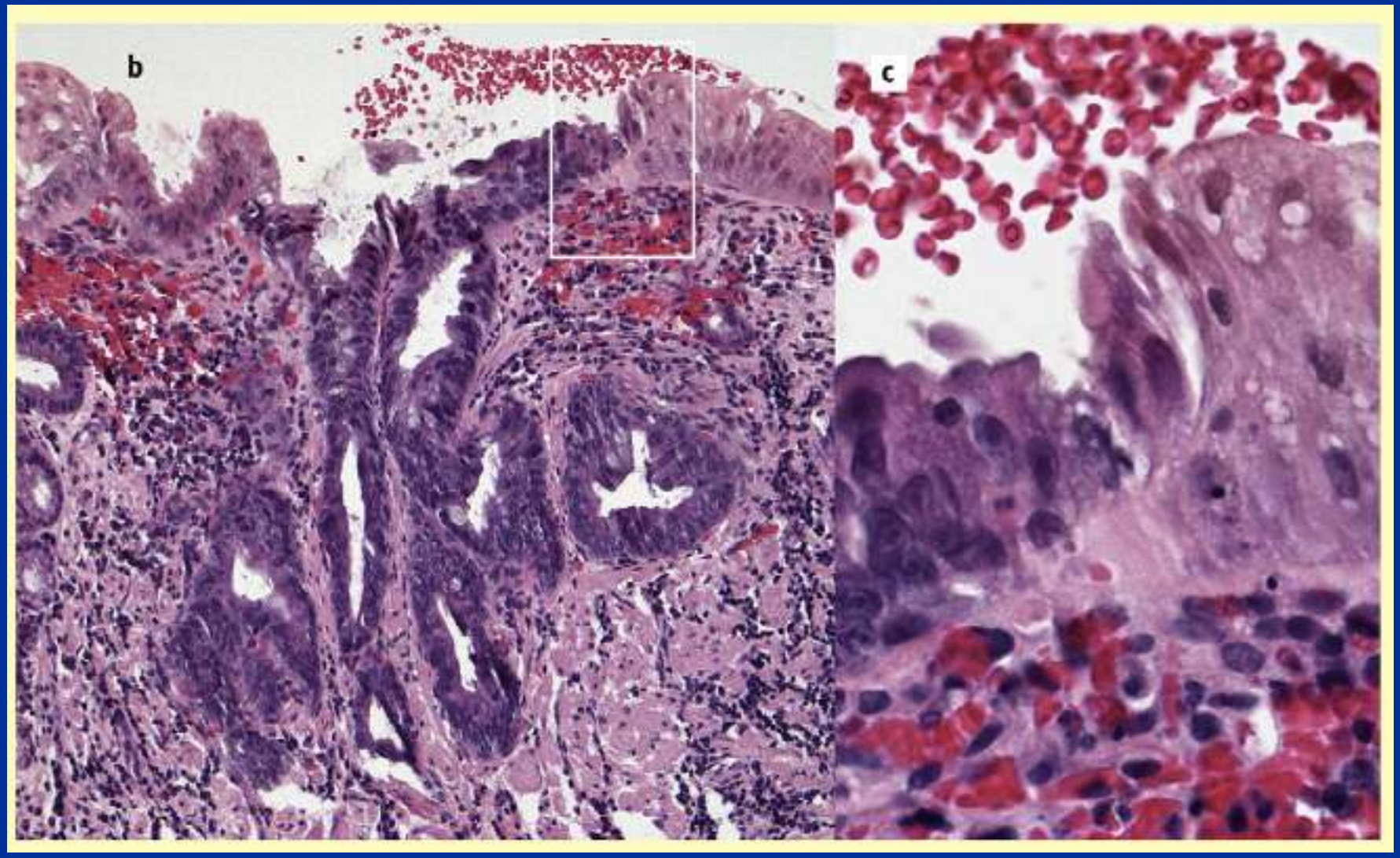

EMR (endoscopic “mucosal” resection

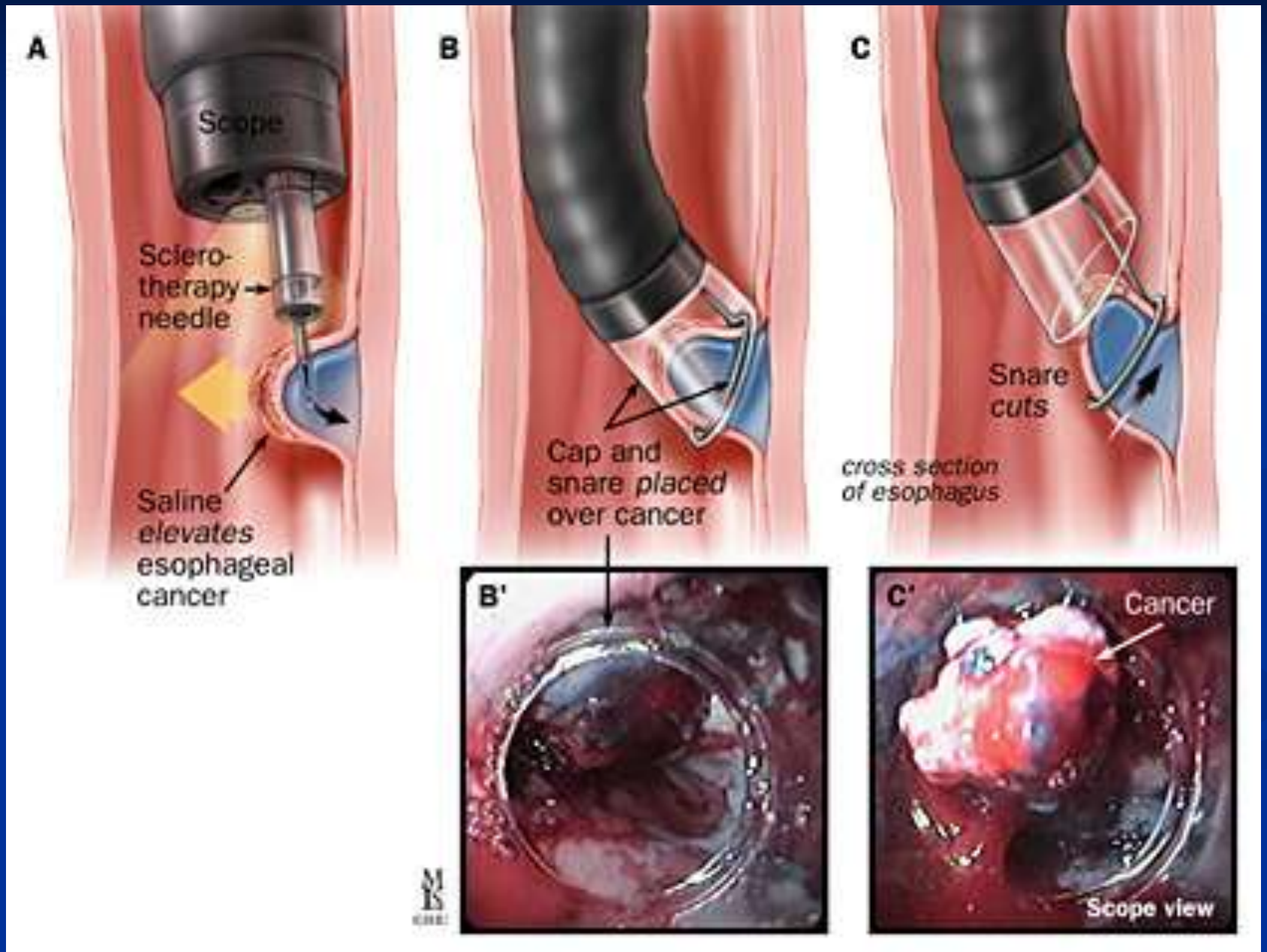

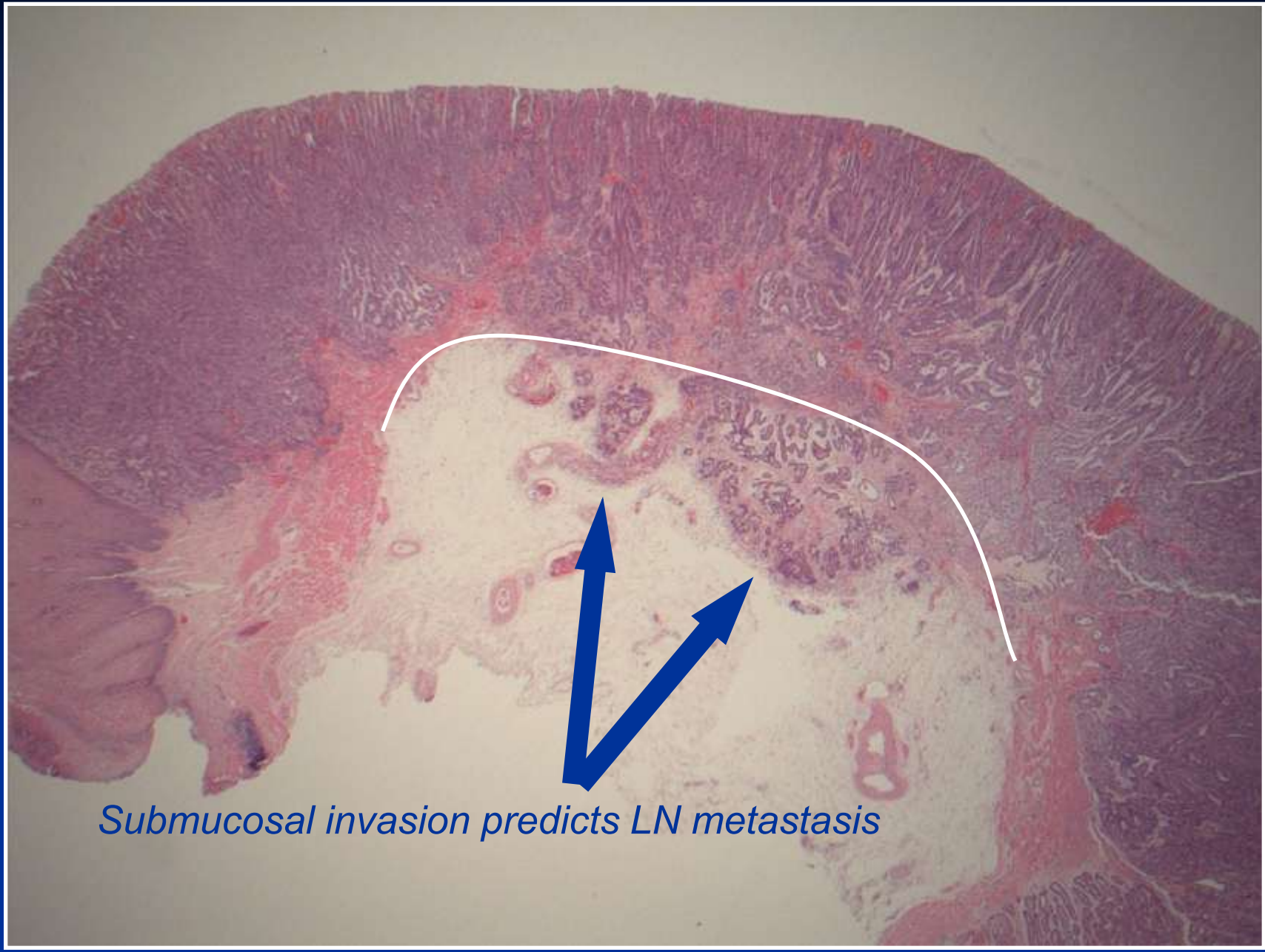
Submucosal invasion predicts LN metastasis

What is the name of this procedure for “burning” Barrett’s?

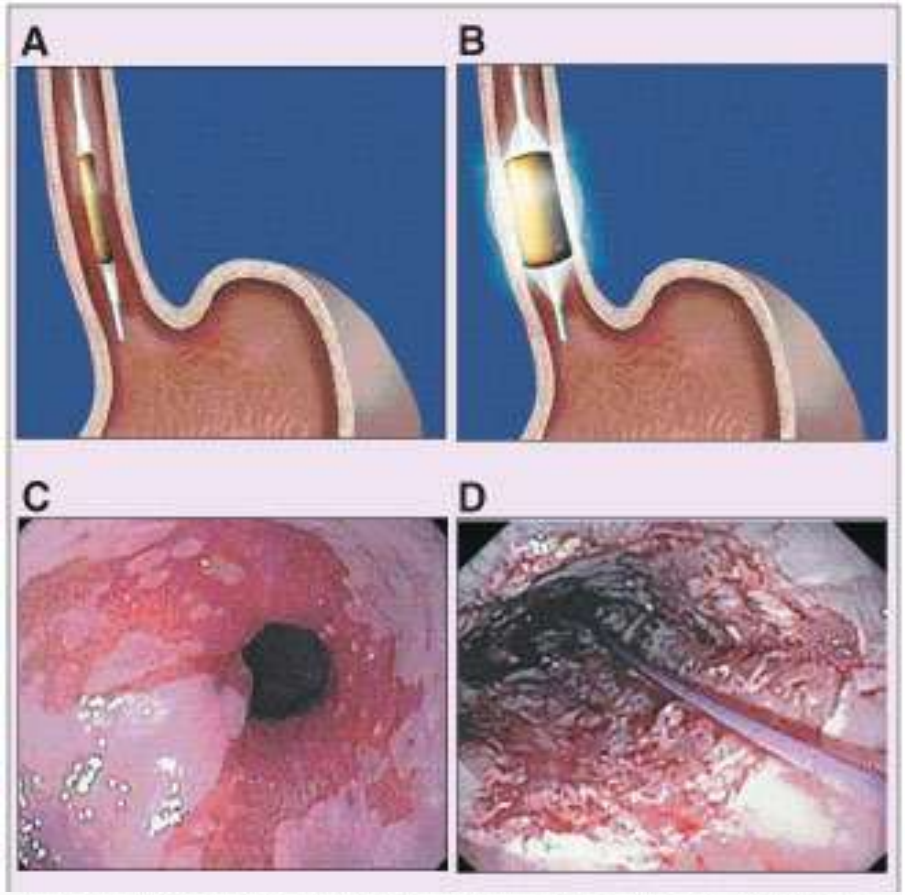

Figure 4: Radiofrequency Ablation of Barrett’s Esophagus—(A) After appropriate sizing, the radiofrequency ablation (RFA) catheter is advanced into appropriate position over a guidewire. **(B)** The balloon is expanded and radiofrequency energy is applied. **(C)** Preoperative appearance of Barrett’s esophagus prior to RFA. **(D)** Circumferential mucosal ablation pattern achieved with the BARRX RFA probe.

RFA is indicated for persistent *flat* dysplasia and high risk long segment Barrett’s

Case study 3

- 70 year old male with history of reflux, on PPI
- Presents with increasing dysphagia, weight loss and jaundice
- What would you do next?
- ABC, history and examination
- Bloods – FBC shows Hb 7.6 U+E normal

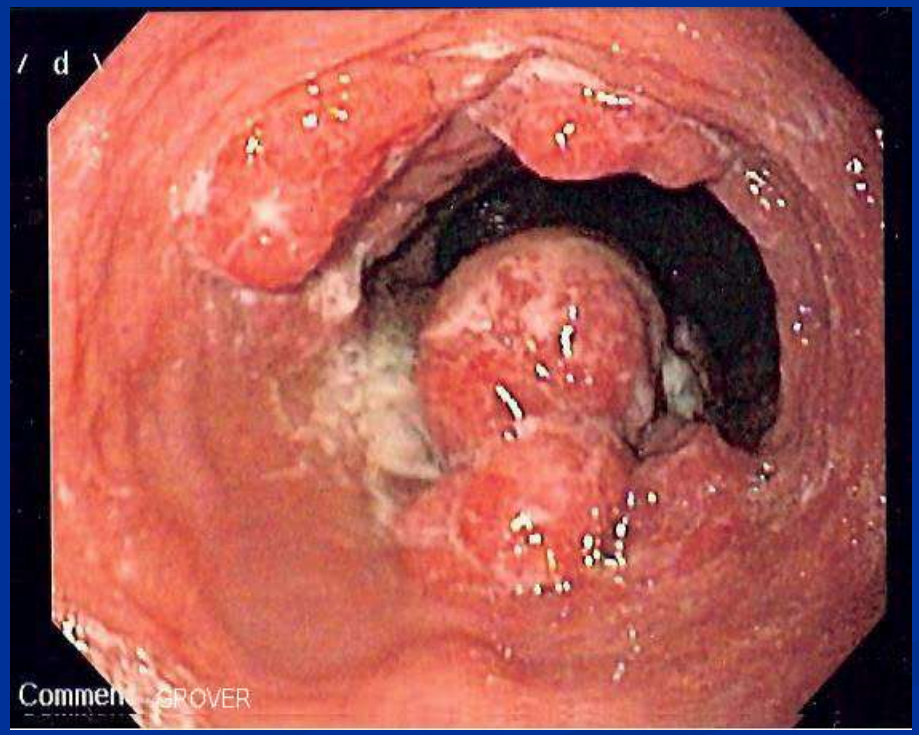
/ d \
Comment
GROVER

What is your differential diagnosis of a tumour in the oesophagus?

- Benign
  - Leiomyoma – smooth muscle tumour (like a uterine fibroid)
- Borderline malignant potential
  - GIST (gastrointestinal stromal tumour)
- Malignant
  - Carcinoma
    - Adenocarcinoma, SCC, small cell carcinoma
  - Lymphoma
  - Other rarities

What symptoms / signs might you find in a patient with oesophageal cancer?

- General / Systemic
  - Wt loss
  - Anaemia
  - Jaundice
  - Lymphadenopathy
  - Respiratory symptoms
- Specific
  - Progressive dysphagia
  - Odynophagia
  - Aspiration
  - Haematemesis (direct or fistulation)
  - Dysphonia

What are the main risk factors for oesophageal cancer?

- Age
- Gender (male)
- Reflux oesophagitis
- Obesity (reflux)
- Barrett's oesophagus
- Smoking and alcohol
- Geography (100x more common in some countries)
  - China, Singapore, Caspian sea area
  - Nitrosamines – fish, acidic / caustic foods/drinks
- Plummer-Vinson syndrome and other rarities

Case 3

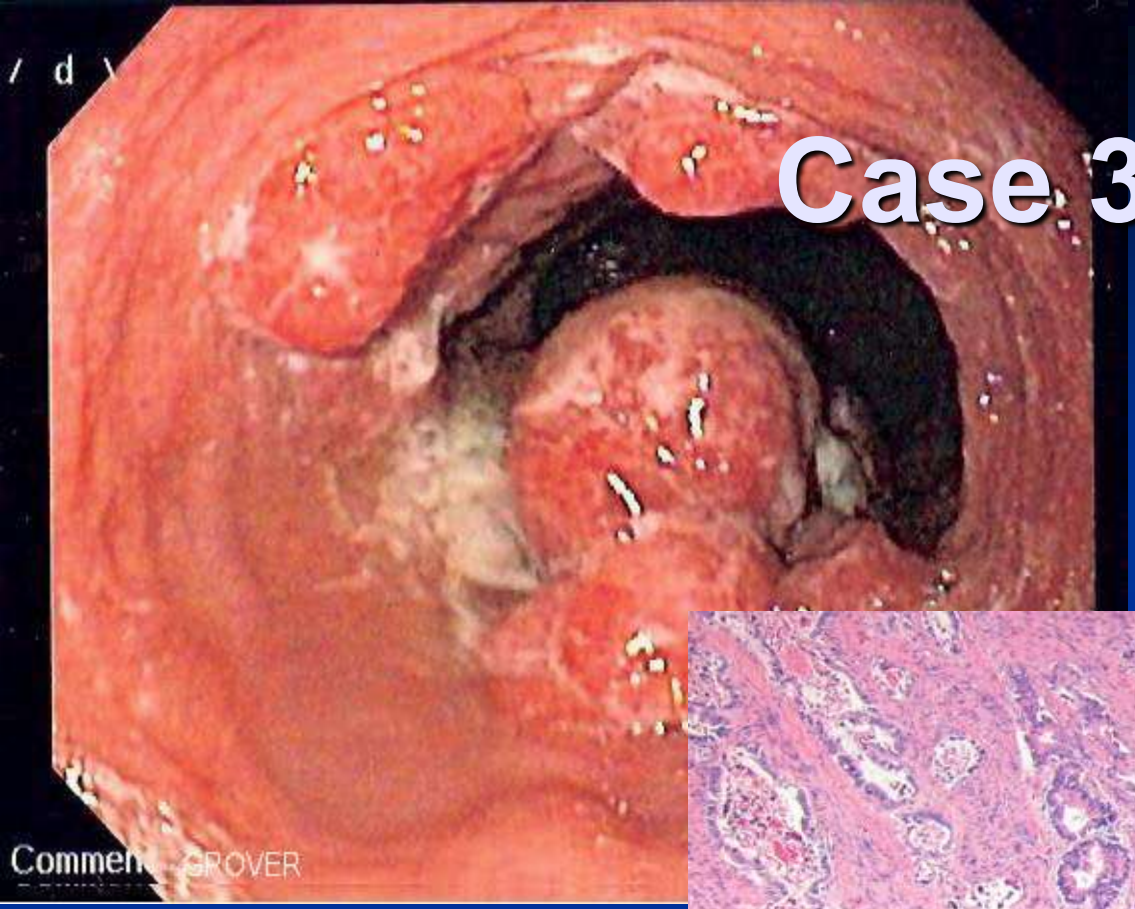

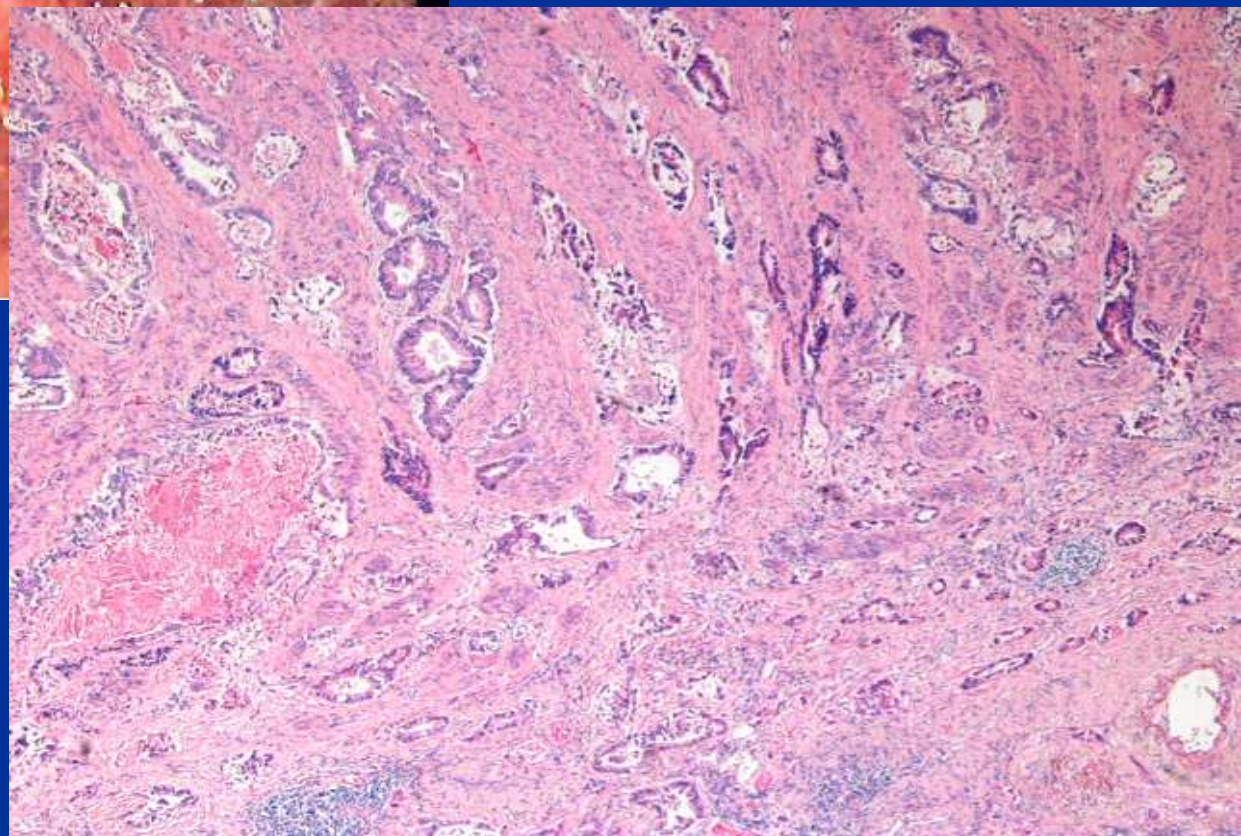

Case 3

- Biopsy showed invasive adenocarcinoma on the background of Barrett's mucosa with high grade dysplasia
- What are the treatment options for oesophageal cancer?
- Conservative / Palliative
- Medical / Oncological
- Surgical
- oesophagectomy, gastrectomy, *(or EMR)*
- Where should this decision be made?

  MDT meeting

Case 3

- CT chest and abdomen showed extensive local and metastatic spread with multiple liver metastases
- Patient opted for stent to control symptoms

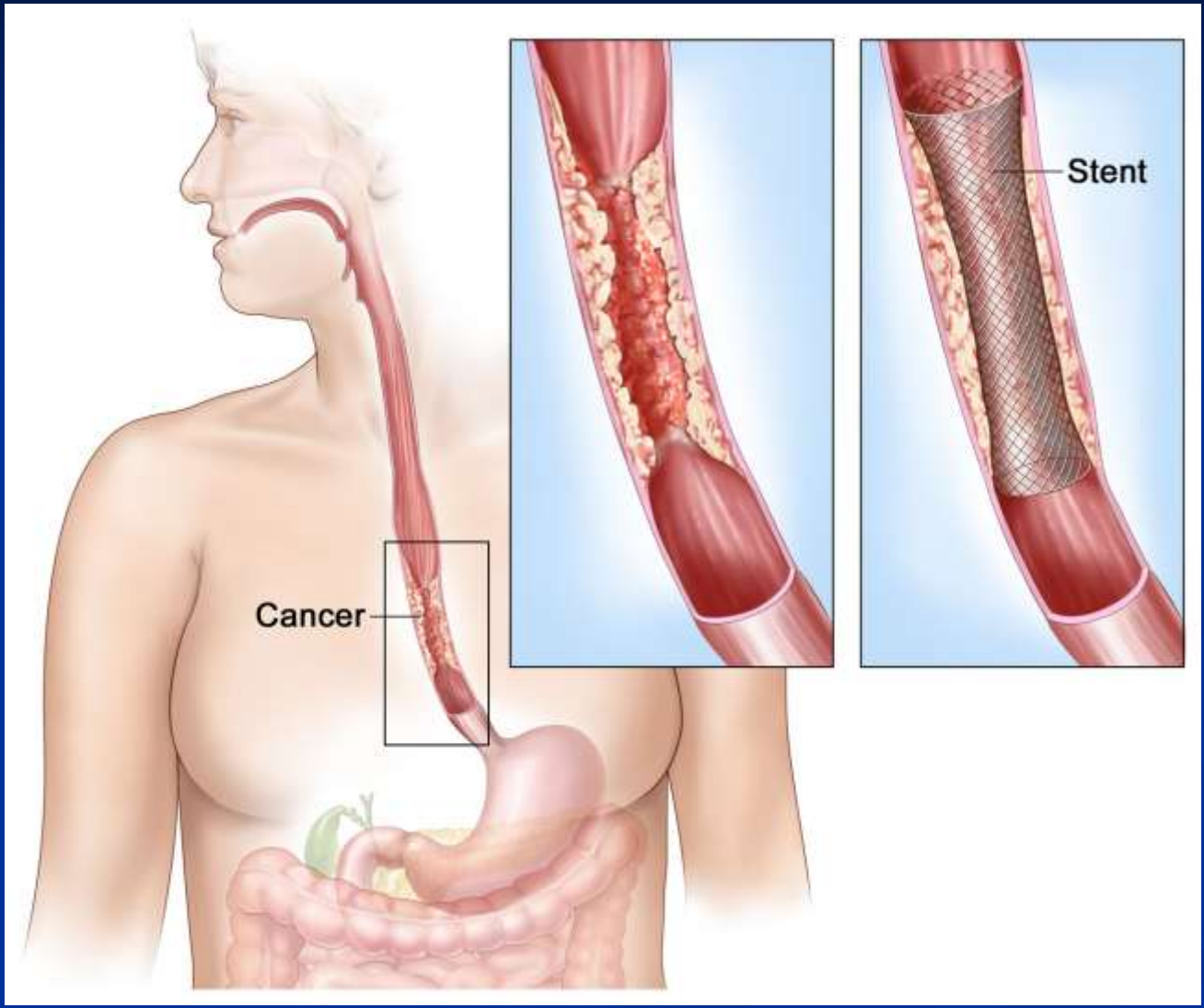
Cancer
Stent

Patient died postoperatively

What do you see in the chest?

Case 3 - postmortem

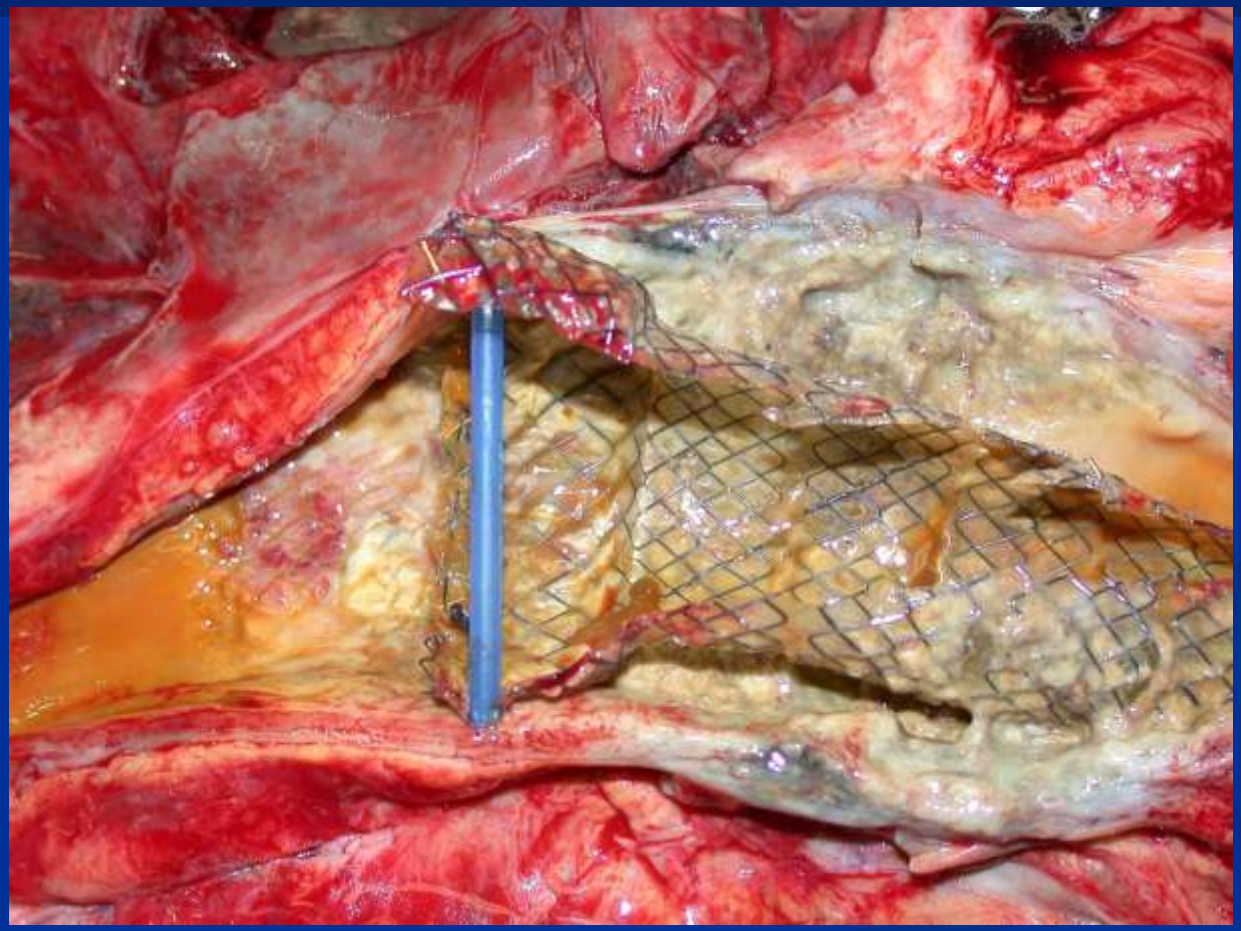

What do you see?

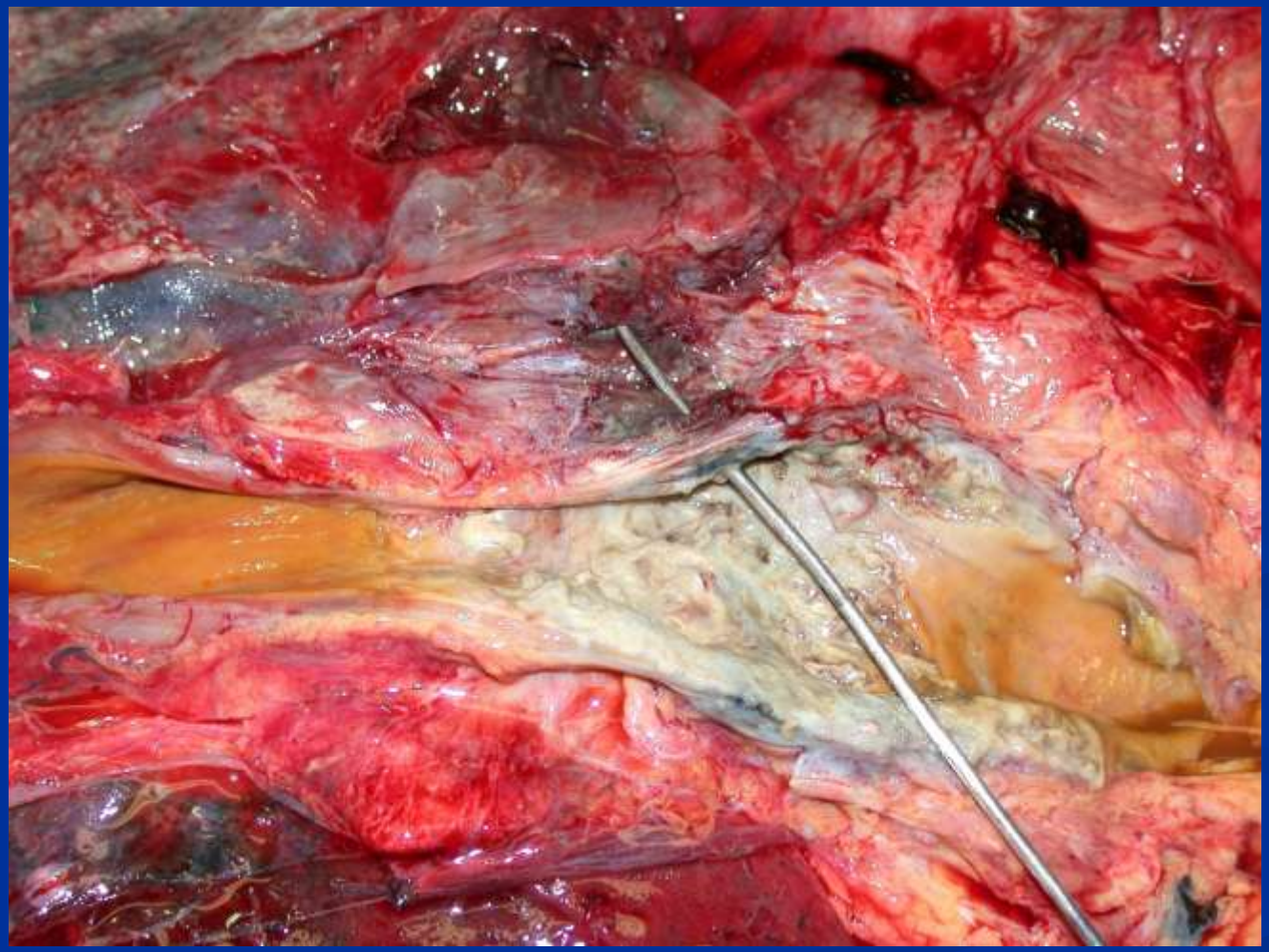

What is this?

Summary

- Anatomy of the oesophagus
- Differential diagnosis of dysphagia
- Case study 1 – benign oesophageal motility disorder (achalasia)
- Case study 2 - Barrett's oesophagus, importance of surveillance for dysplasia and carcinoma
- Case study 3 – Advanced oesophageal adenocarcinoma died after stent insertion

Any questions?

- Presentations will be posted on the following website with password “amyloid” needed to access the protected files
- http://www.pathkids.com
- Many of the diagrams / photos in this presentation are protected by copyright laws. Do not publish or display elsewhere thankyou!