Oesophagus and Stomach

Dr Tim Bracey MBChB PhD FRCPath
Consultant Pathologist
Derriford Hospital
October 2012

this powerpoint will appear on Pathkids.com soon

Images without the Pathkids logo are courtesy of Prof Marco Novelli (UCH)
Please do not republish any of these photos without permission of pathkids.com

Executive Summary

Patient experience, as defined by outcomes and satisfaction levels, is high at the Centre.

A total of 129 patients have undergone surgical resection in the last 12 months at the surgical centre. There were 94 oesophagectomy and 35 gastrectomy procedures performed, with in-hospital mortality rates of 1.1% and 5.7% respectively – 2.3% overall.

The National Oesophago-gastric Cancer Audit 2010 describes in detail the findings of the first national audit of oesophago-gastric cancer care in England and Wales, and provides useful benchmark data. The overall post-operative in-hospital mortality for 3,612 oesophageal and gastric resections from this audit was 5.1% in England and Wales. For the 2,200 oesophageal and 1,412 gastric resections nationally it was 4.5% and 6.0% respectively.

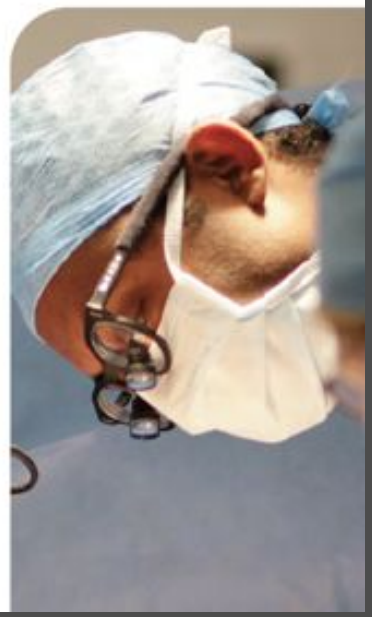

- One of the biggest units in the country
- All biopsies of suspected OG cancers/HG dysplasia from 5 hospitals
- The previous lead pathologist for this service resigned just after I was appointed!

Outline

- Basic anatomy and histology, cutup and instructive cases
- Oesophagus with case studies to illustrate concepts and reporting criteria
- Stomach
- Datasets
- TNM changes
- Biological spectrum of endocrine tumours
- Nothing too obscure!

Don’t be overwhelmed!

Anatomy of oesophagus

- How long is the oesophagus?
- How many cms is its distal limit on endoscopy?
- What are its upper and lower vertebral levels?
- What are the three anatomical levels where obstruction is most likely to occur?

What are the layers of the normal oesophagus?

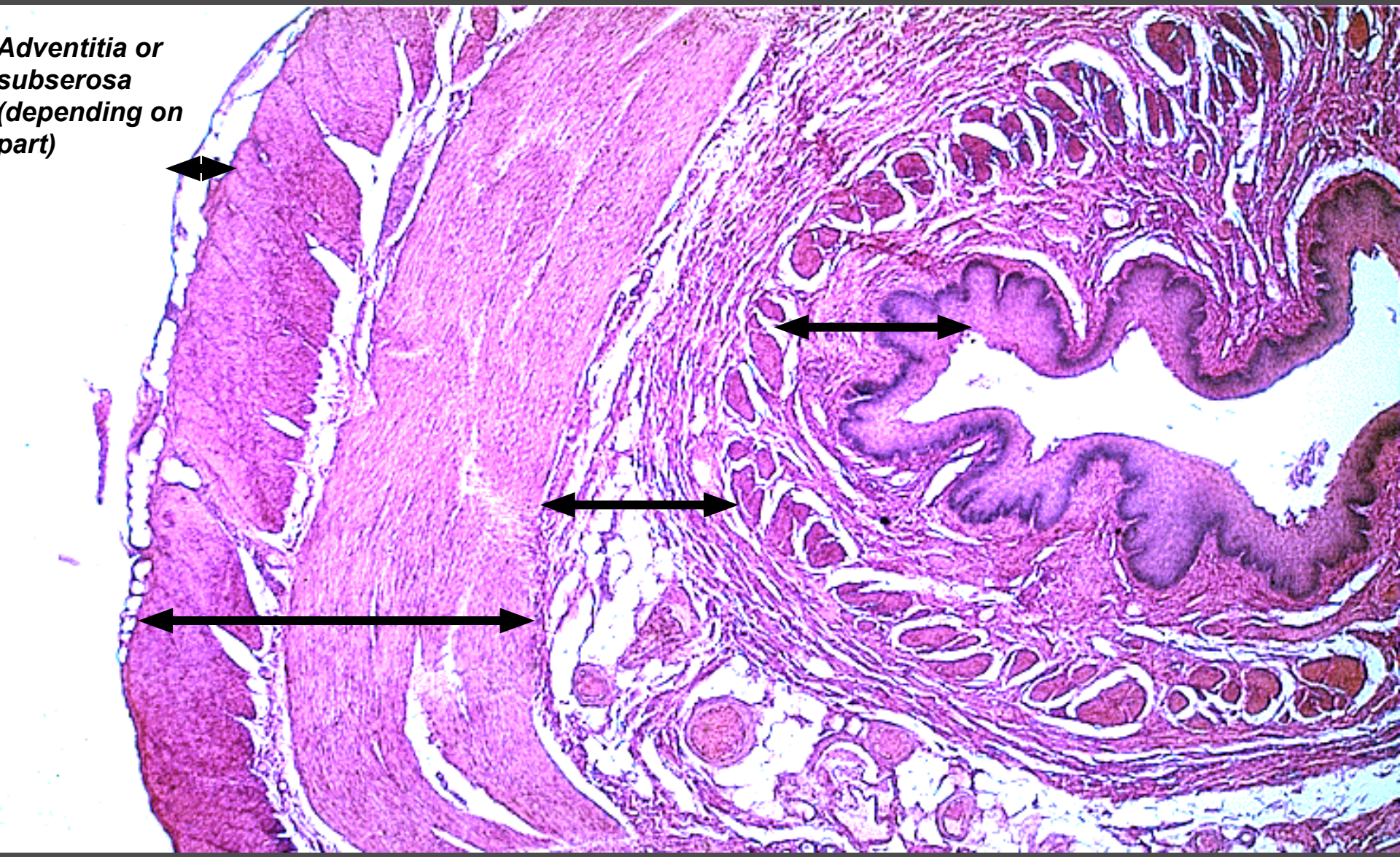

What is the venous drainage of the oesophagus and why is it important clinically?

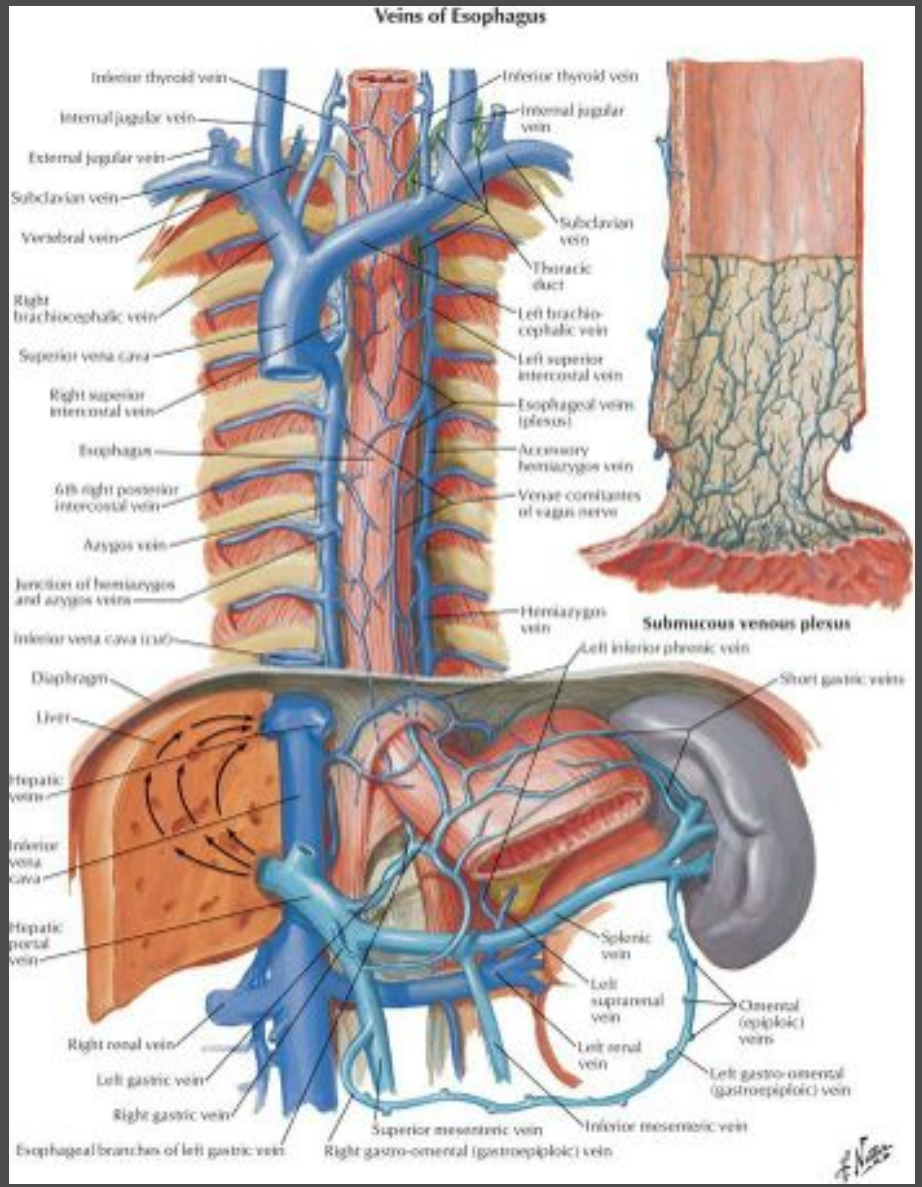

- Upper oesophagus drains into tributaries of azygous vein (systemic circulation)
- Lower portion drains to portal vein. Lower oesophagus is site of *porto-systemic anastamosis*
- Raised portal pressure can lead to…
  - Oesophageal varices

A
B
C
D

Case study 1

- 56 year old male severe oesophagitis
- History of renal transplant
- Mid oesophageal stricture
- Multiple biopsies

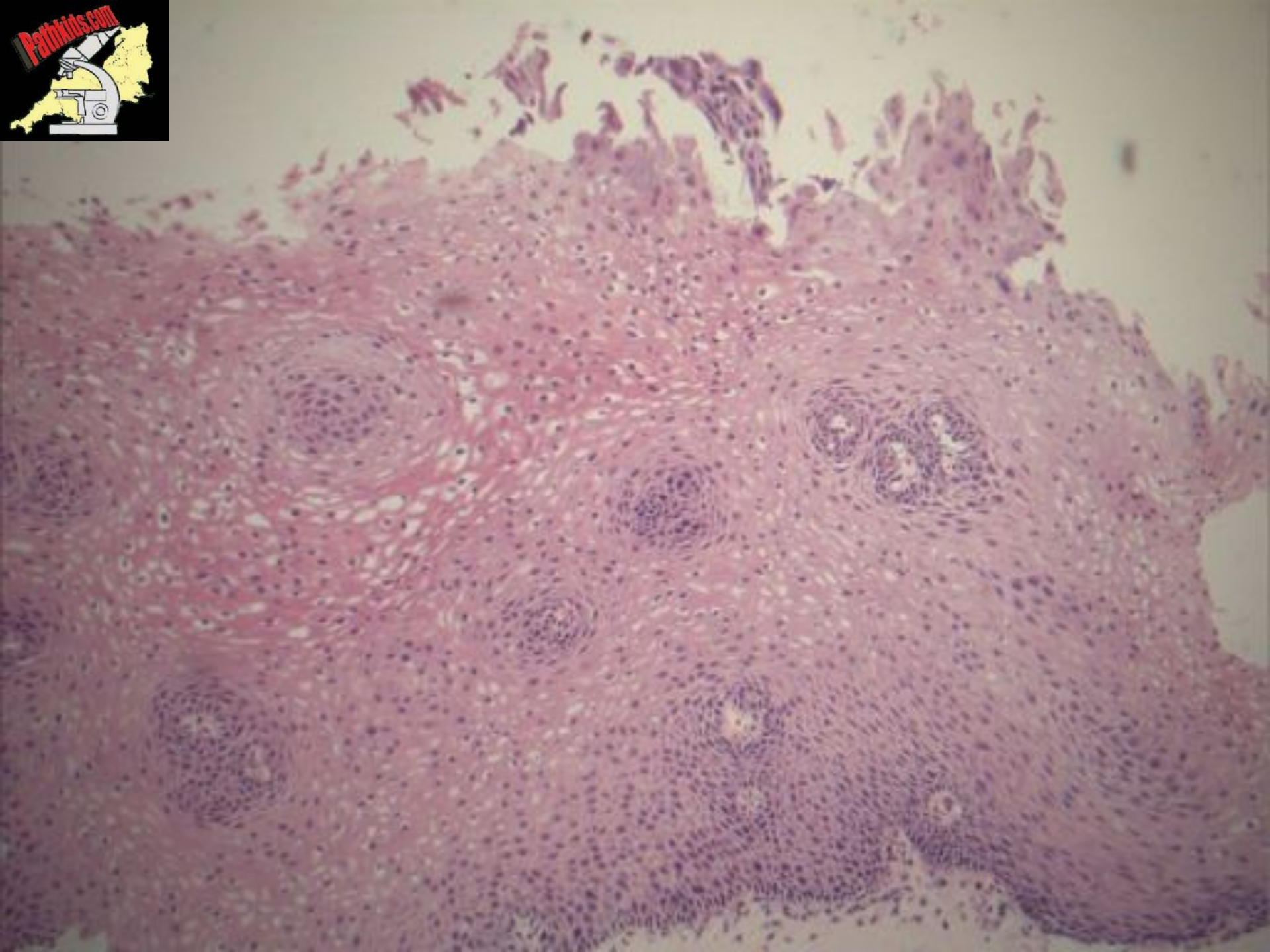
PathKids.com

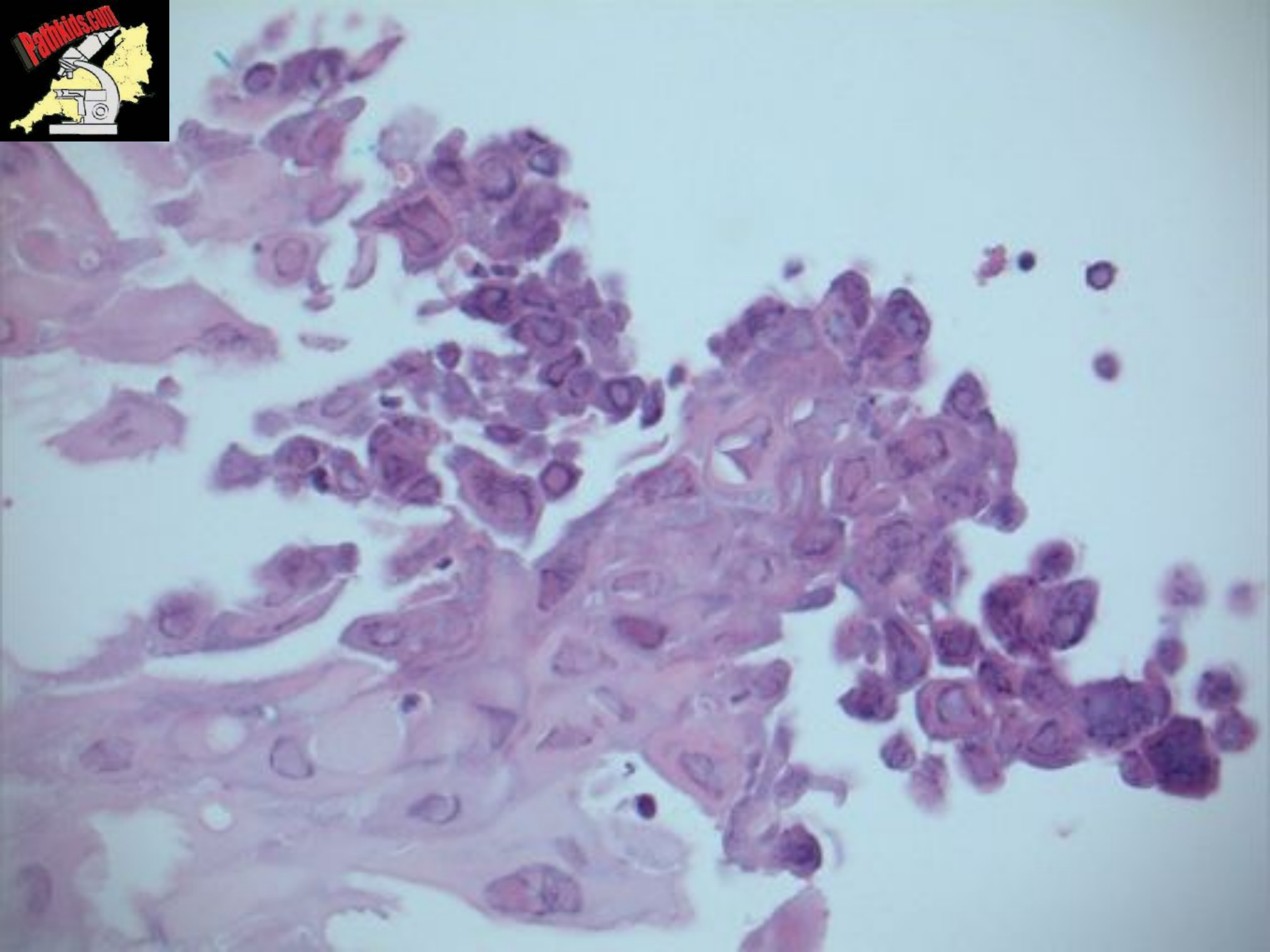
PathKids.com

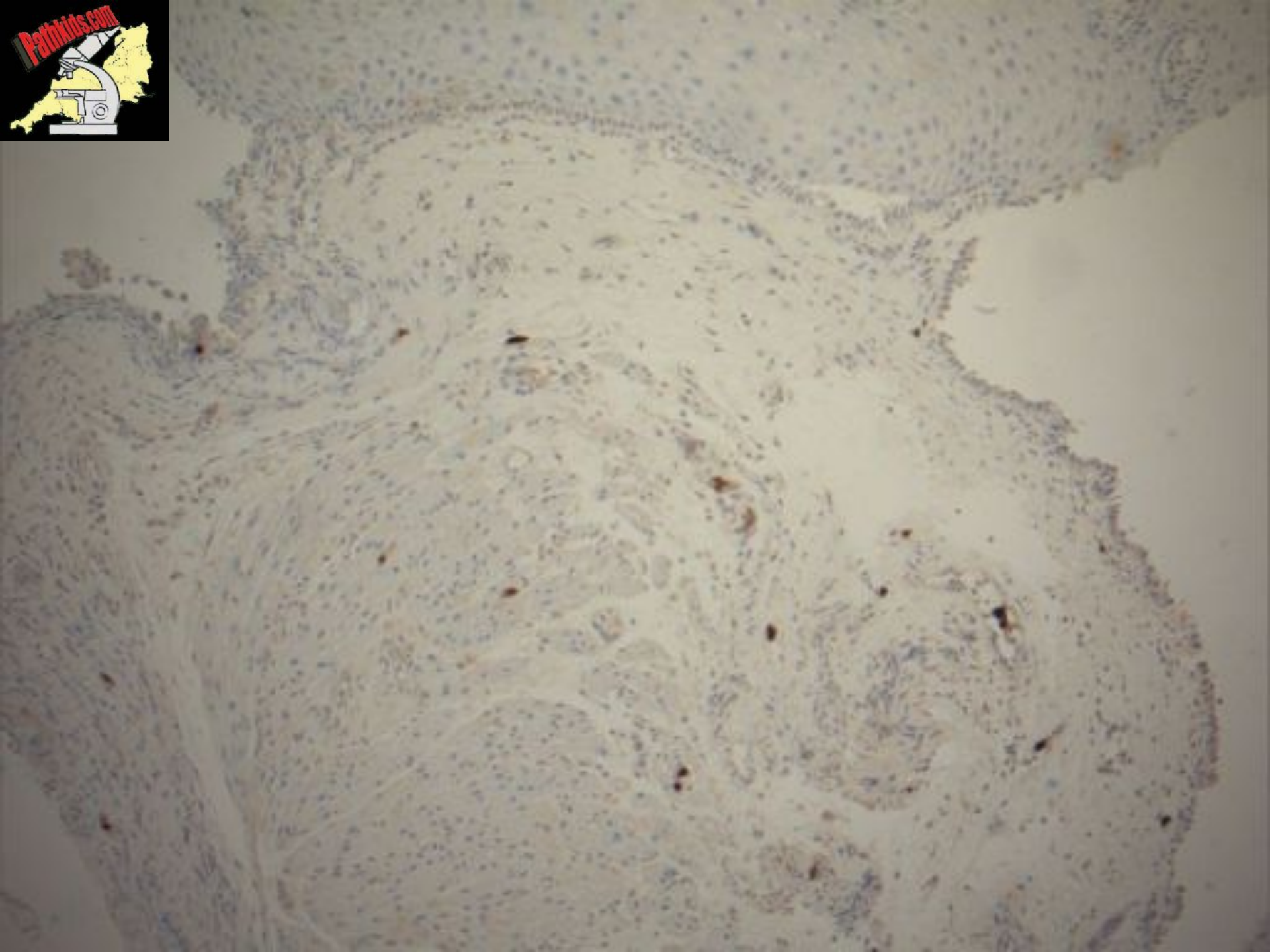
PathKids.com

Case study 1

- 56 year old male severe oesophagitis
- HSV oesophagitis with CMV coinfection
- Result of immunosuppression
- HSV most common infective oesophagitis after candida

Classical HSV features

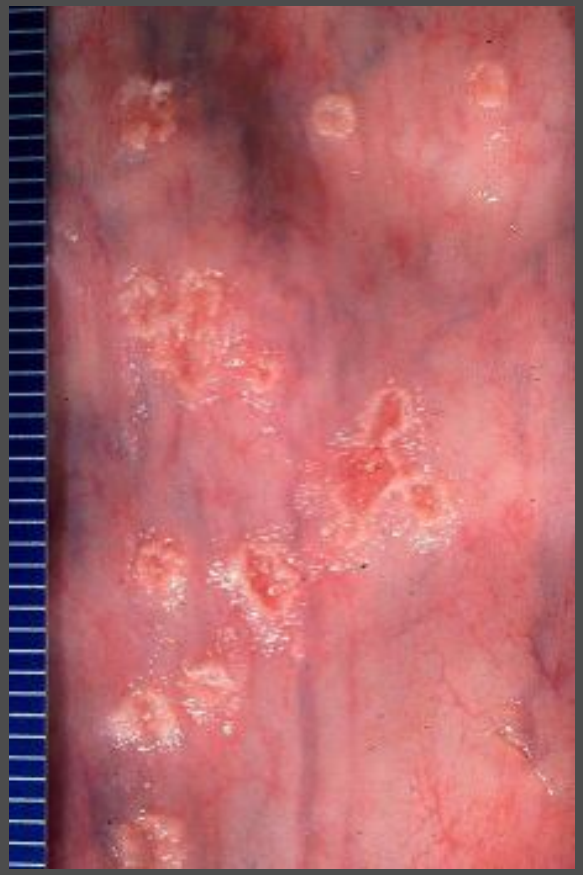

HSV oesophagitis

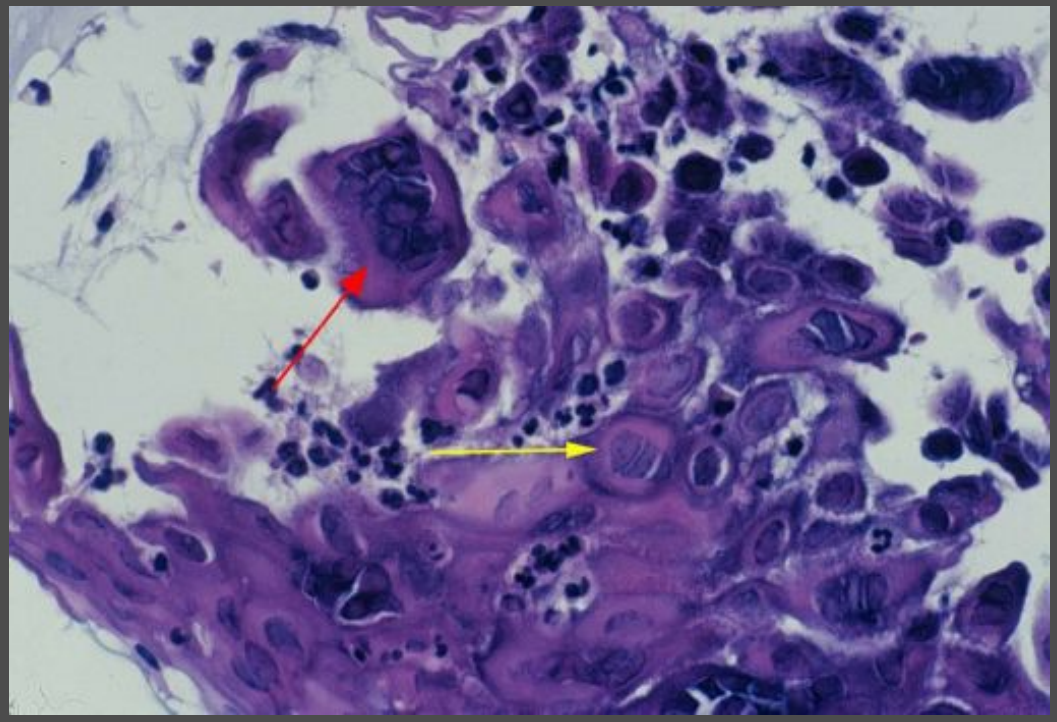

“ground glass nuclear inclusions”

Classical candida oesophagitis

Candida oesophagitis

Note “hyphae” and spores

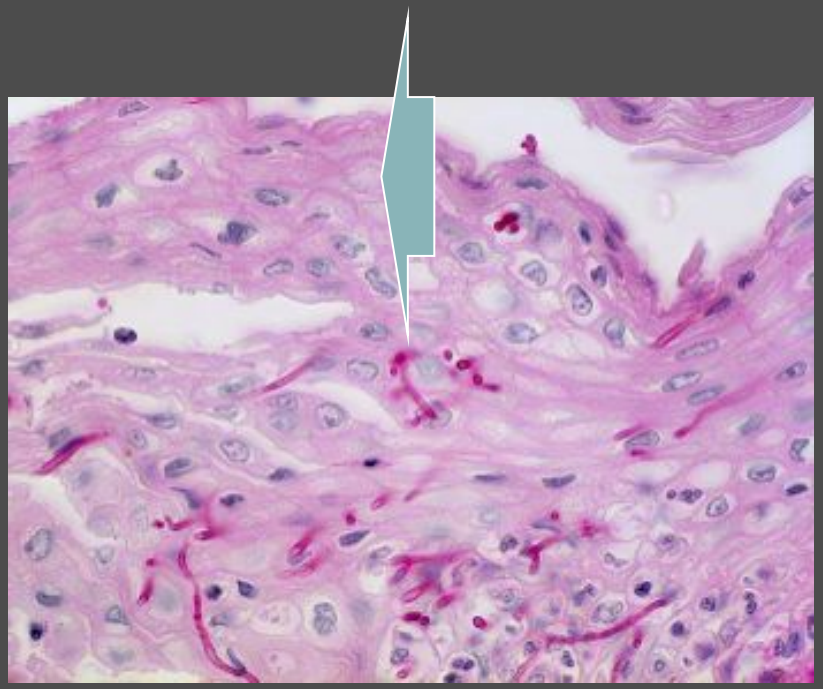

Iron Pill oesophagitis

Pigment in ulcer slough

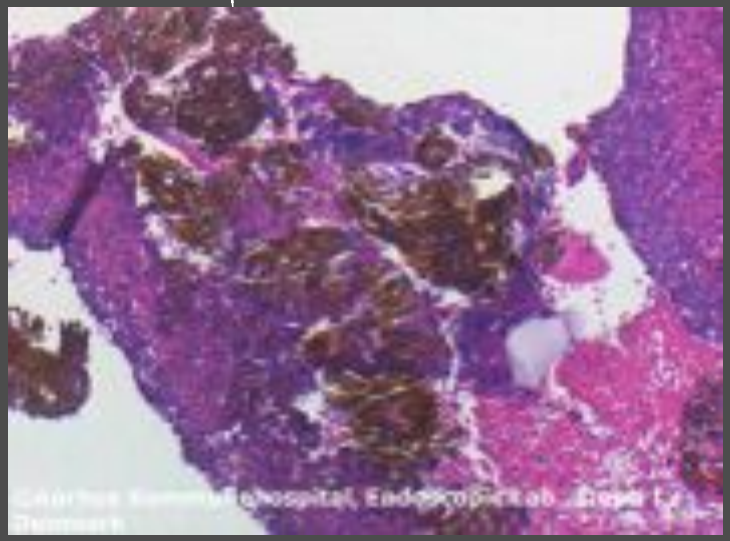

Case study 2

- 24 year old man with dysphagia

Eosinophilic oesophagitis

Trachealisation
“Feline oesoph

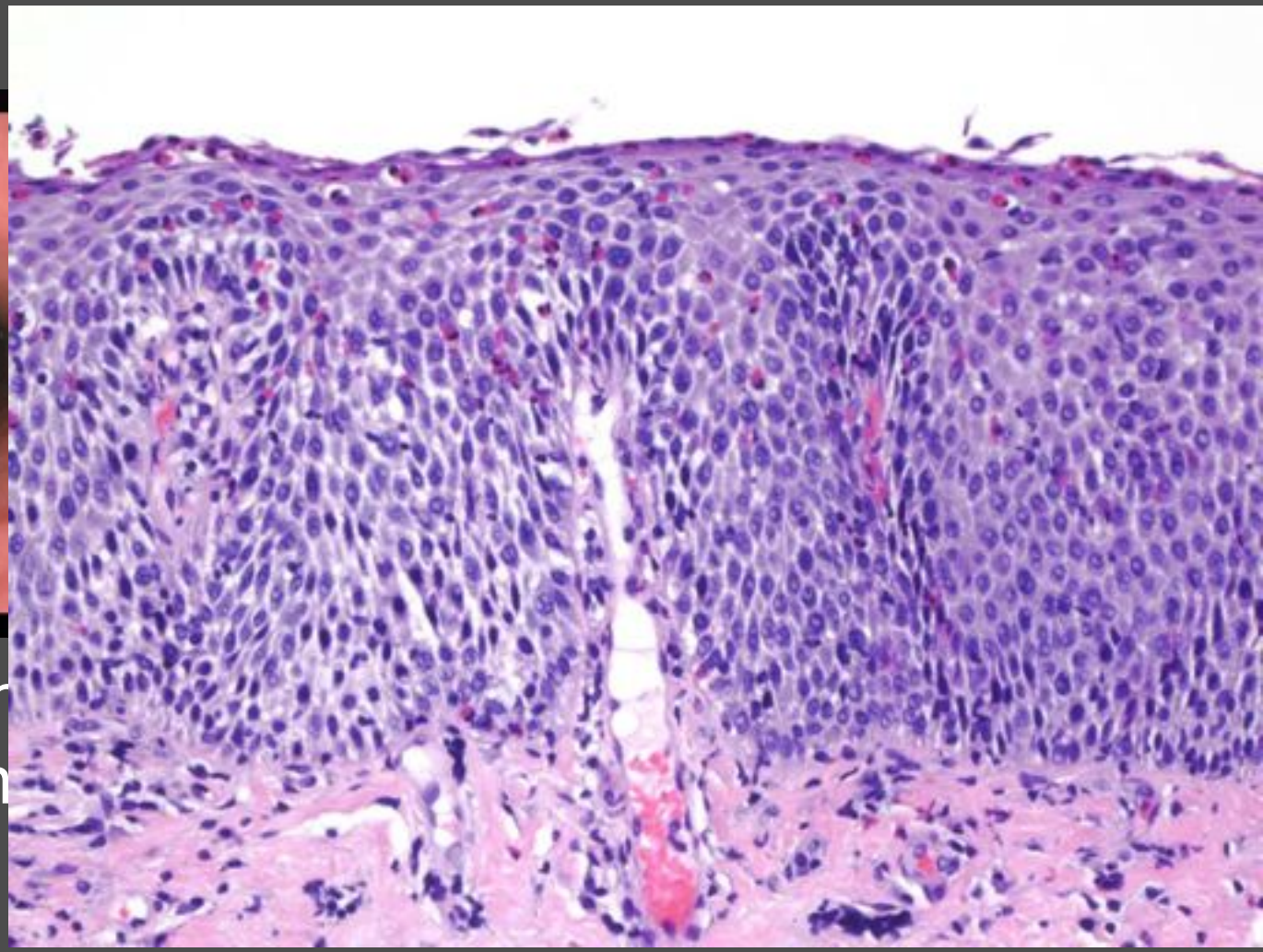

Remember criteria and potential overlap with GORD!

Oesophagectomy cutup

Indication – cancers with curative intent! Very rarely for refractory HG dysplasia

Fresh or fixed?

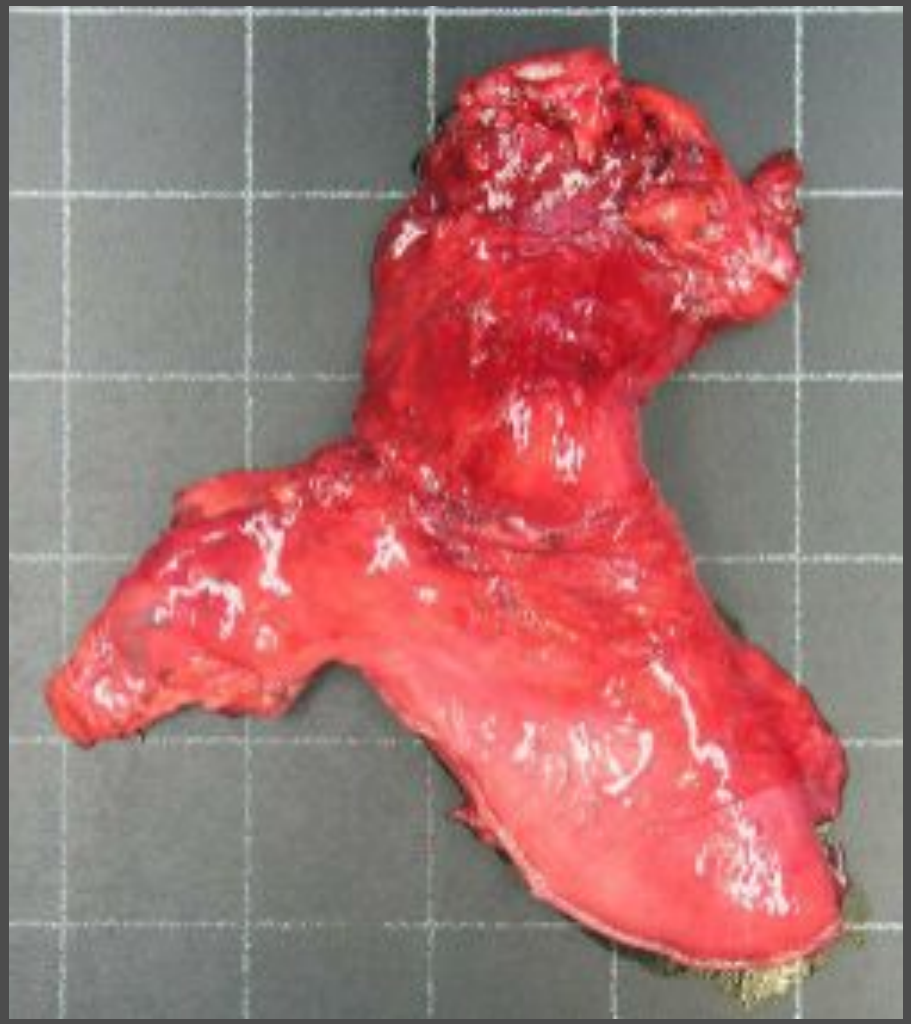

- Open gastric end (cut along staples) + pin on cork board

24107-02

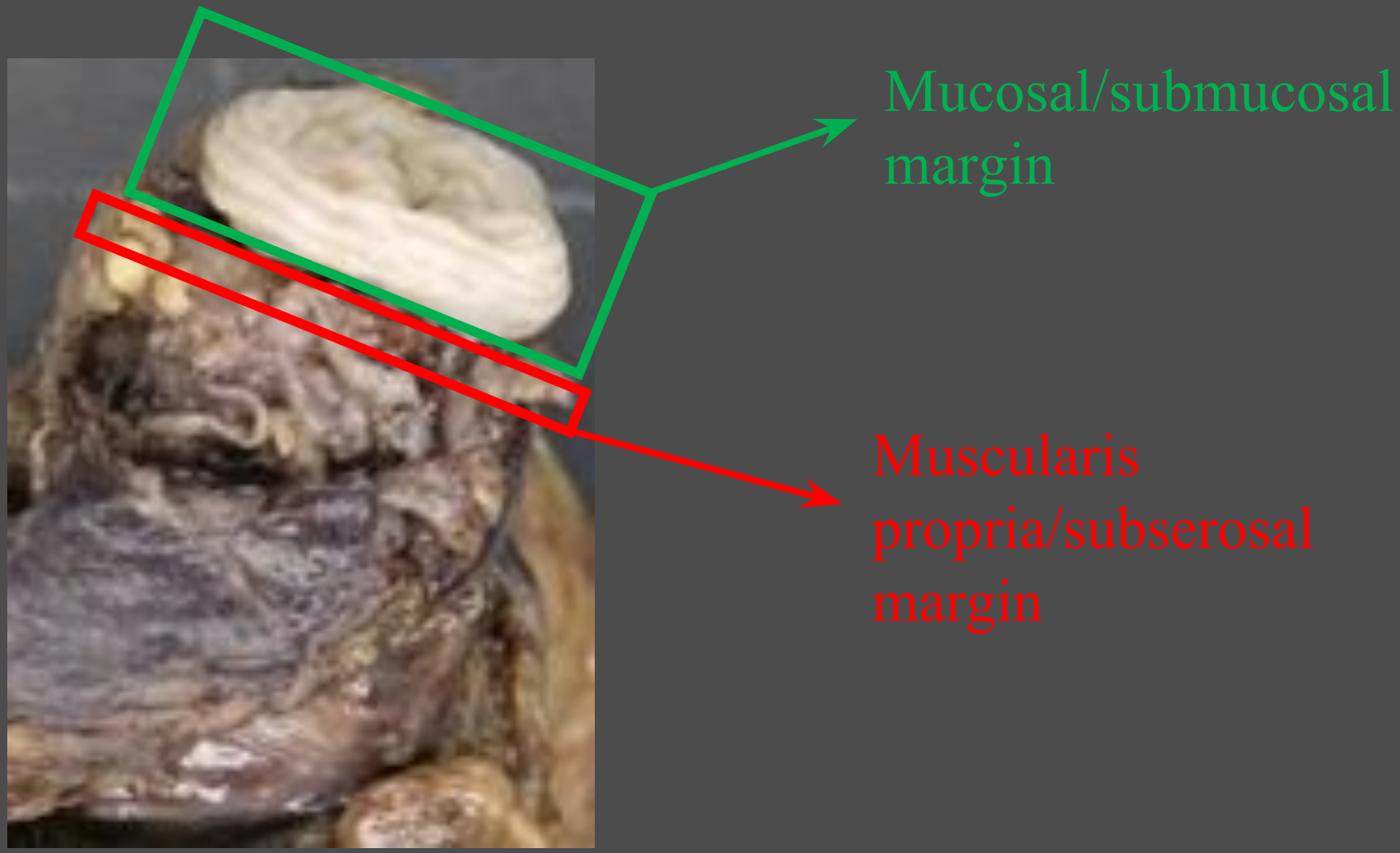

Proximal margin assessment in non-pinned specimens

- Ink circumferential margin

Circumferential margin vs serosa

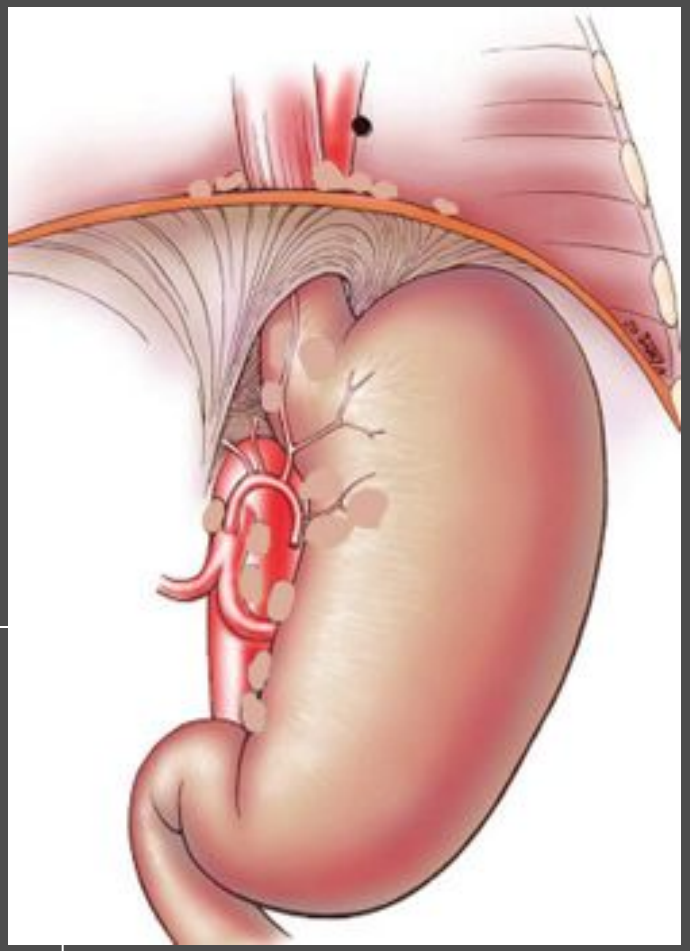

- CRM almost entire length of oesophagus.
  (≈ 1cm intra-abdominal peritonealised)
- At OGJ for gastric tumours.

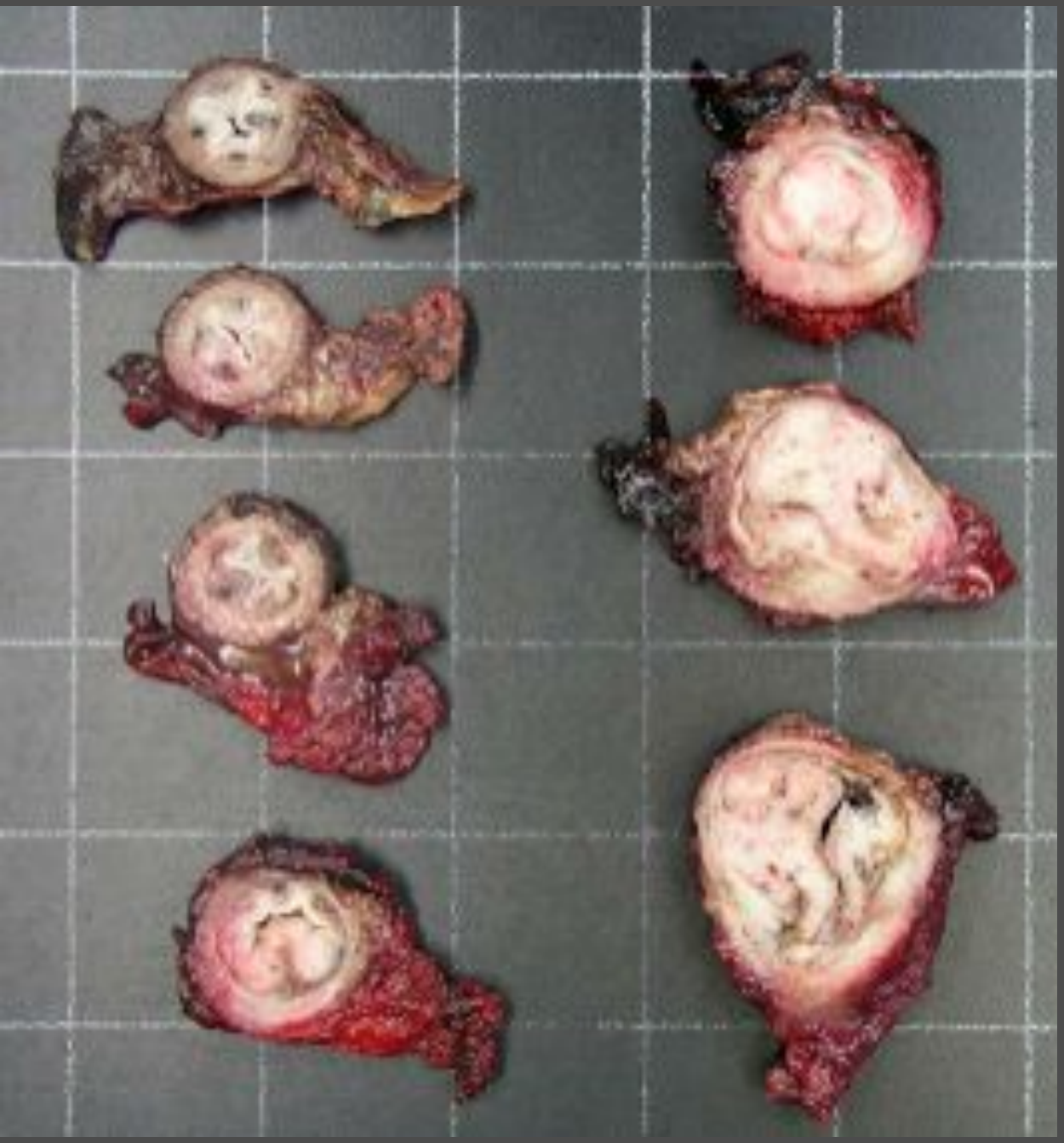

- In this specimen the tumour is predominantly in the stomach and the serosa has been inked red
- The serosa is an anatomical plane NOT A MARGIN!

Endoscopic mucosal resection (EMR)

Endoscopic mucosal resection (EMR)



- Resection not a biopsy.
- Treat like a cervical cone (do NOT bisect!).
- If received orientated – ink margins.

Endoscopic mucosal resection (EMR)

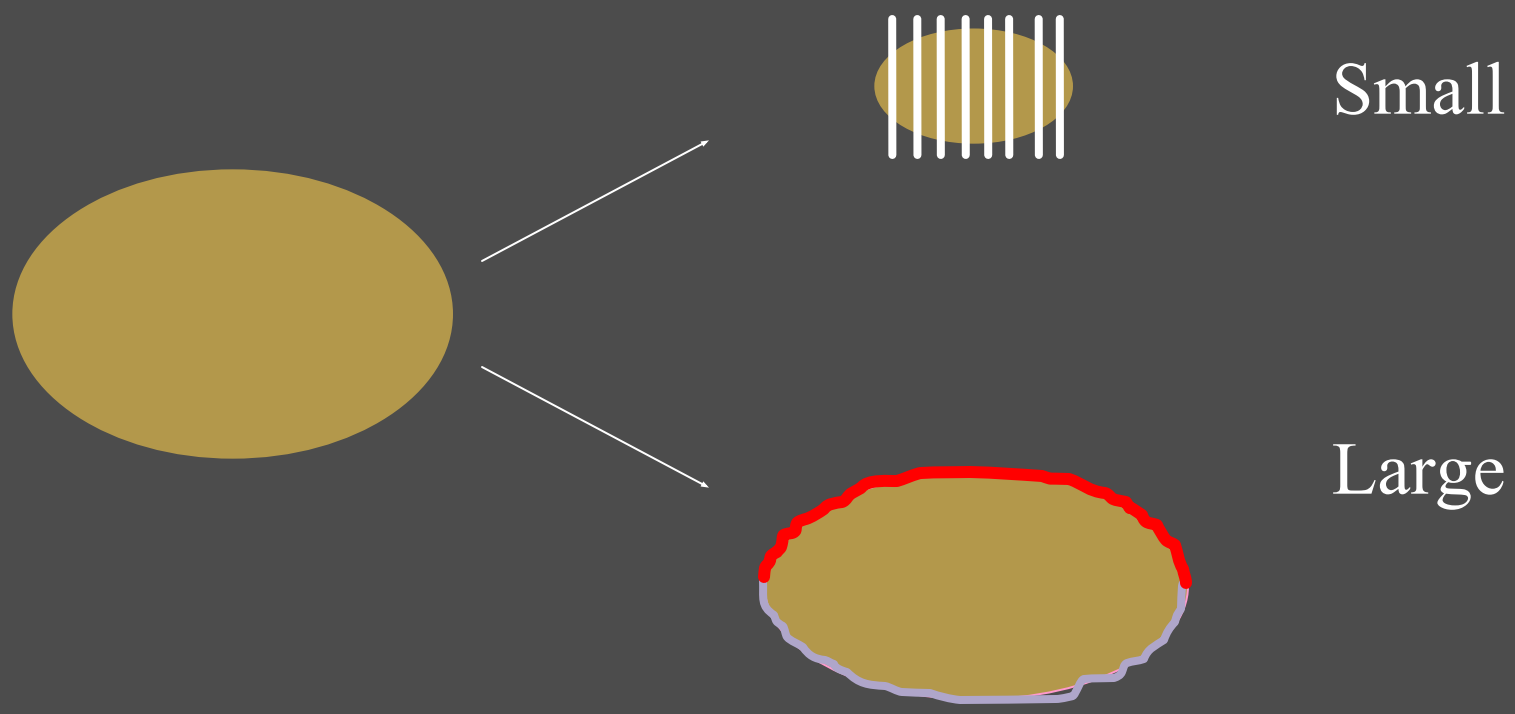

- Ink if orientated and large enough.
- Serially section.

EMR (small) + ESDs (larger)

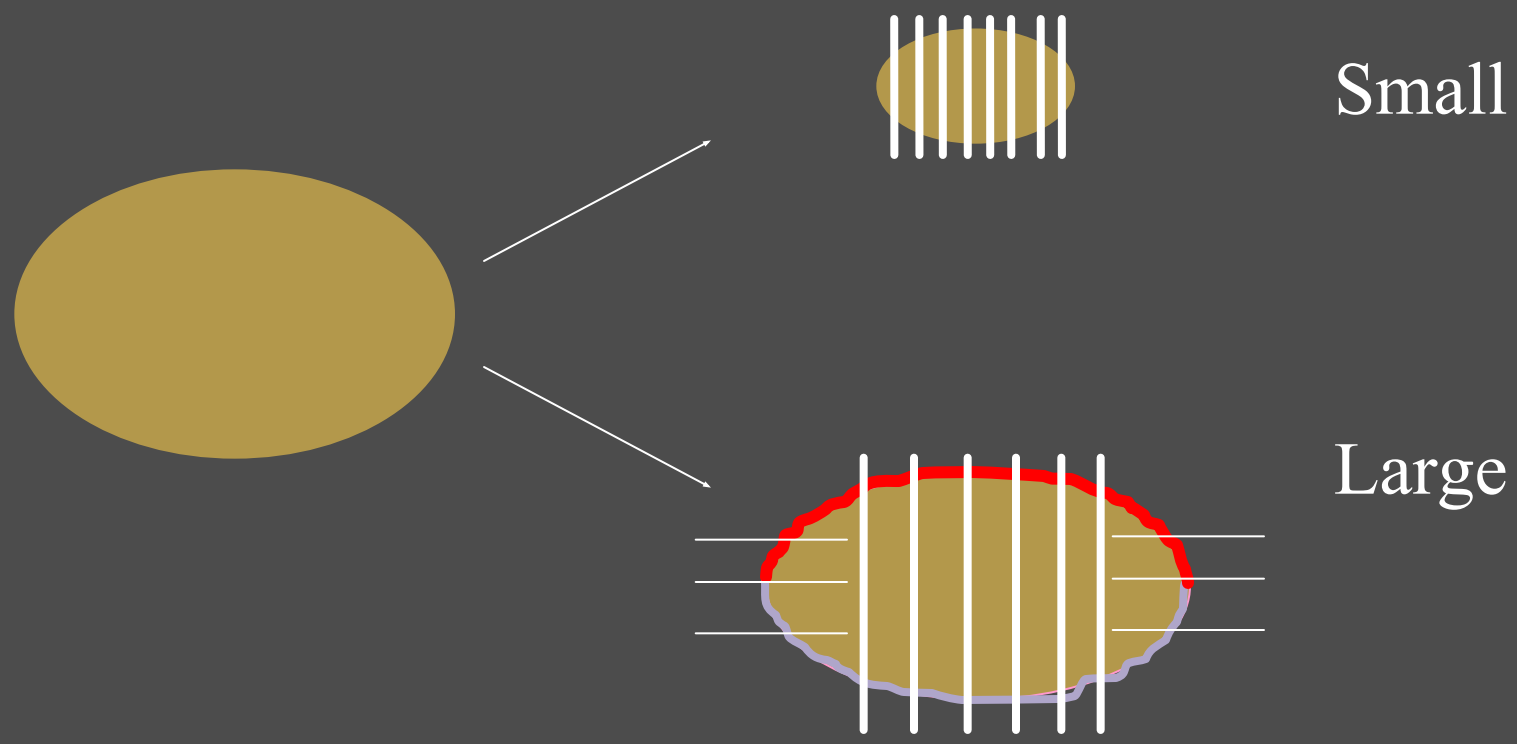

- Ink if orientated and large enough.
- Serially section.

Endoscopic mucosal resection (EMR)

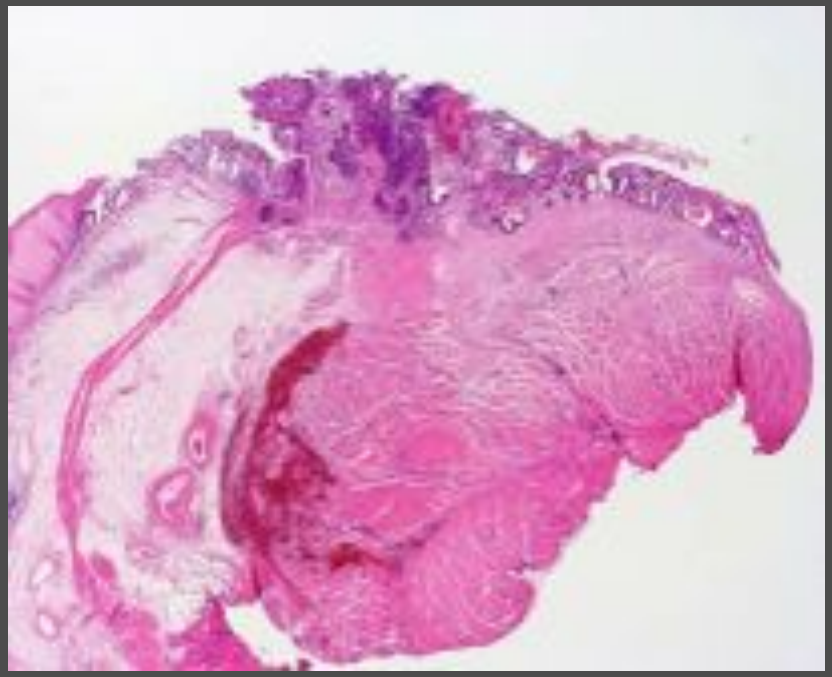

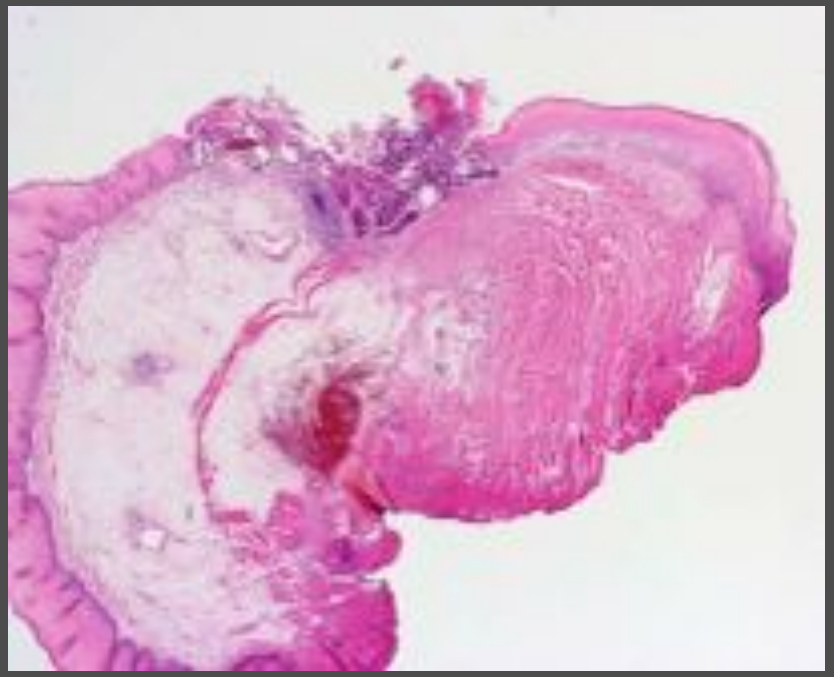

- Usually lots of diathermy artefact.
- Dysplasia often reaches circumferential margin.

Endoscopic mucosal resection (EMR)

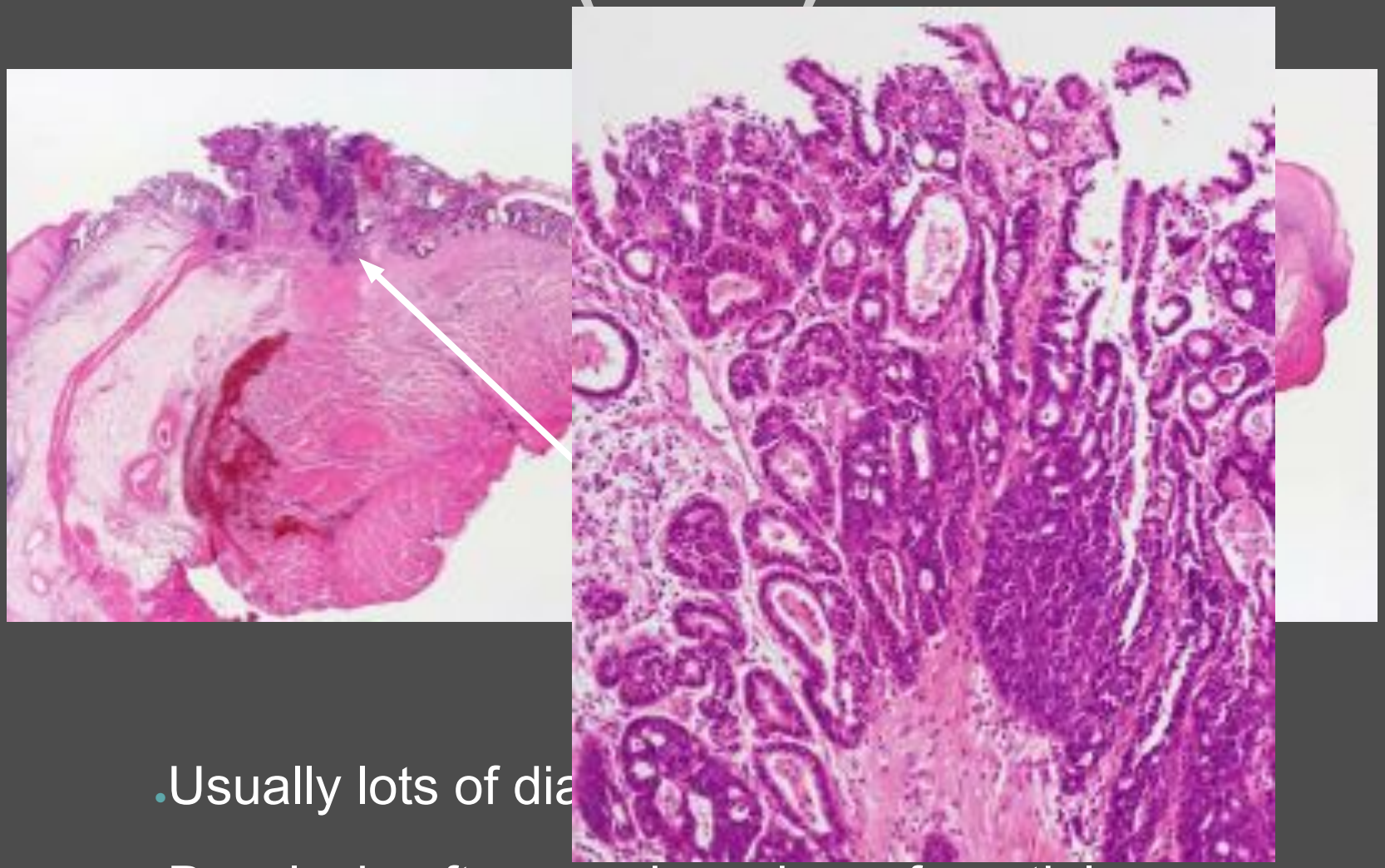

- Usually lots of dia
- Dysplasia often reaches circumferential margin.

Endoscopic mucosal resection (EMR)

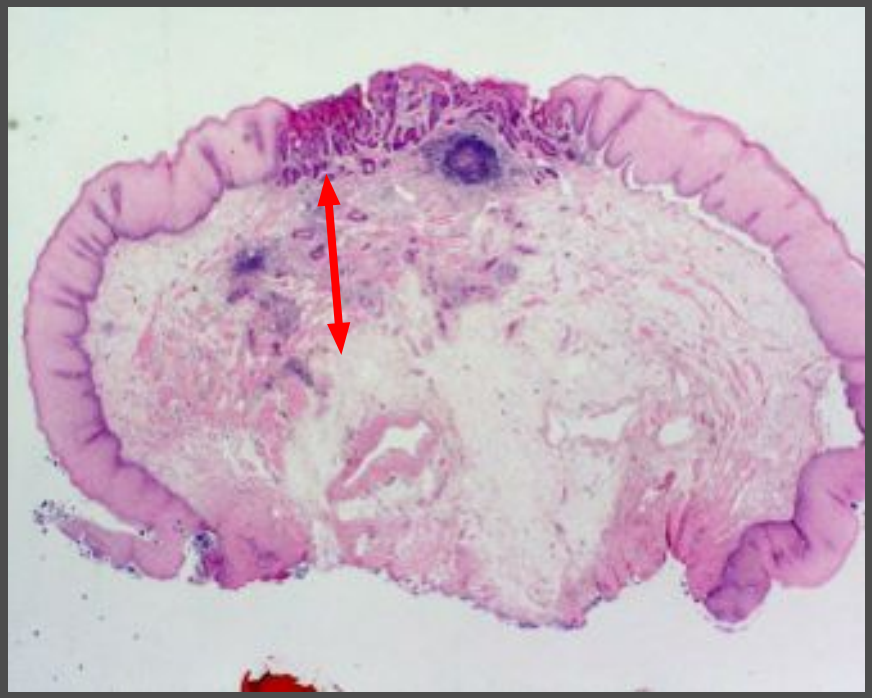

- Stage invasive carcinoma.
  - Mostly pT1
  - Submucosal invasion?
  - May be difficult to assess as splaying/reduplication of muscularis mucosa)
- Measure depth of invasion.
- Circumferential margins (may not be a true margin)
- Deep resection margin

Critical reporting criteria – any poor differentiation, submucosa and/or vascular invasion, clearance from deep margin
If none of the above factors – more radical treatment may not be necessary

Case study 3

- 60 year old male, long history of Barrett's
- Nodule seen on surveillance
- Referred for EMR

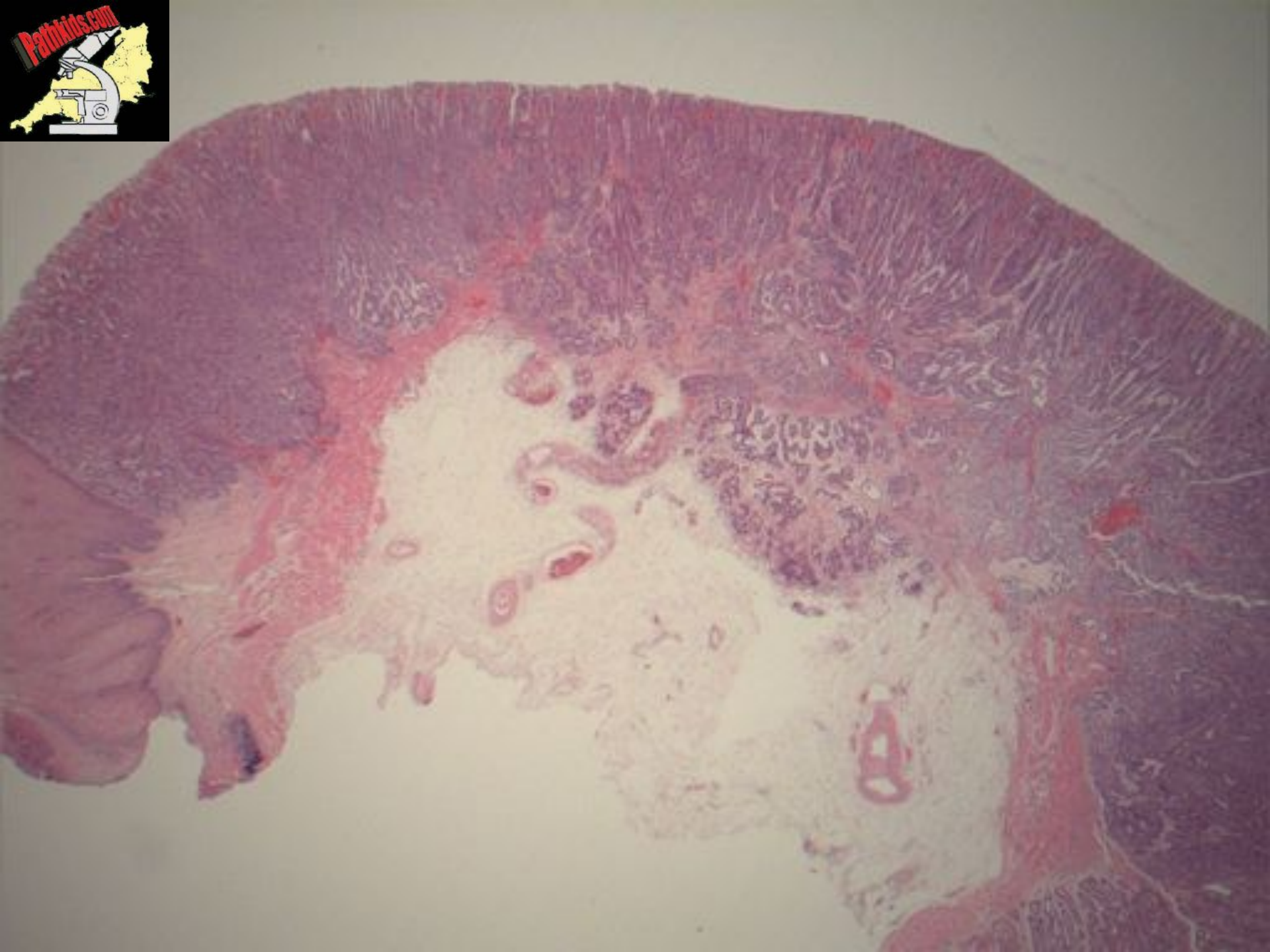
PathKids.com

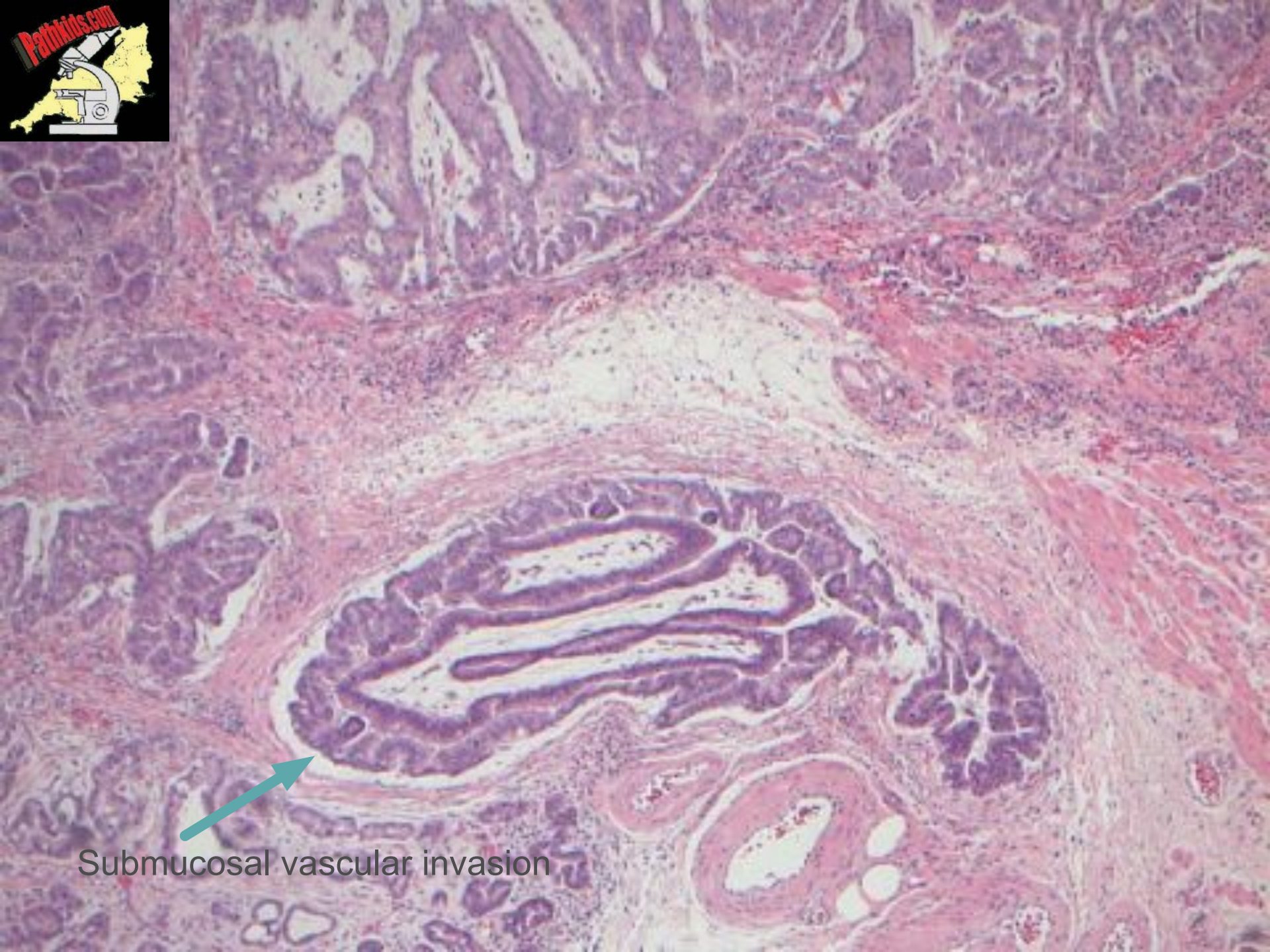
Submucosal vascular invasion

Case study 3

- EMR
- Moderately differentiated adenocarcinoma
- Submucosal (pT1b) and Vascular invasion
- Deep margin 0.8mm

  - Referred for oesophagectomy, why??
  - Mucosal to submucosal invasion, risk of LN mets rises from 1% (no poor diff) to >20% risk!

OESOPHAGEAL CANCER RESECTION

NAME: ..... Hosp No: ..... DoB: ..... LAB No: .....

GROSS DESCRIPTION:

Length of specimen: mm (unpinned)
Length of oesophagus: mm Length of stomach (maximum): mm
Length of tumour: mm Width of tumour: mm
Tumour edge to nearest distal margin: mm, to nearest proximal margin: mm
Macroscopic type of tumour: polypoid / other *(specify)*: .....

Siewert tumour type (tumours with epicentre within 5cm of oesophagogastric junction):
Type 1 ☐ epicentre 1-5cm above GOJ; Type 2 ☐ epicentre at GOJ; Type 3 ☐ centre 1-5cm below GOJ
Only tumours with an epicentre in the stomach greater than 5cm from the OGJ, or those within 5cm of the OGJ without extension in the oesophagus are staged using the gastric proforma. All other tumours involving oesophagus staged with this proforma.

HISTOLOGY:

Type of tumour: SQUAMOUS / ADENOCARCINOMA / OTHER *(specify)* .....
Differentiation by *worst* area:- WELL / MODERATE / POOR
Depth of invasion: Tumour invades to: lamina propria or muscularis mucosae (pT1a) / submucosa (pT1b) / muscularis propria (pT2) / beyond muscularis propria (pT3) / invasion of serosal sacs or diaphragm (pT4a) / invasion of other structures eg. aorta, vertebrae or trachea (pT4b).

Neo-adjuvant therapy given YES / NO / UNKNOWN
Tumour regression grade (TRG) (MANDARD) post preoperative chemo/radiotherapy:

- ☐ TRG 1 - Complete regression
- ☐ TRG 2 - Rare residual cancer cells
- ☐ TRG 3 - More residual cancer cells but fibrosis predominates
- ☐ TRG 4 - Residual cancer predominates over fibrosis
- ☐ TRG 5 - Absence of regressive changes
- ☐ No clinical information provided

Margins:
Proximal margin: NORMAL / BARRETT'S / DYSPLASIA / CARCINOMA.
Distal margin features: NORMAL / BARRETT'S / DYSPLASIA / CARCINOMA
Circumferential margin involved (<1mm): YES / NO
Histological measurement from tumour to circumferential margin: mm
Proximal do'nut: Distal do'nut:

Other:
Vascular (lymphatic or blood vessel) invasion: YES / NO
Barrett's metaplasia: YES / NO

Metastatic spread:
Number of lymph nodes examined: ..... (PARA-OESOPHAGEAL .....PARAGASTRIC ..... OTHER.....)
Number of lymph nodes involved: .....(PARA-OESOPHAGEAL .....PARAGASTRIC ..... OTHER.....)
pN1: metastasis in 1-2 regional lymph nodes, pN2: metastasis in 3-6 regional lymph nodes, pN3: metastasis in 7 or more regional lymph nodes.
NB: Coeliac nodes now considered within N category (TNM7) not M1a (TNM6)

Tissue submitted representing metastatic spread (M1): YES / NO

Pathological Staging:
Complete resection at all margins (R0) YES / NO

(y)pT pN pM *remove 'y' prefix if neo-adjuvant not given* (TNM 7th edition)

Polypoid tumours have better prognosis

All tumours centred within 5cm of GOJ now considered to be oesophageal and staged with this dataset

If considering TRG3 or less ensure all tumour bed/whole oesophagus embedded

If surgeon has removed paraoesophageal LNs this margin may be "Not assessable"

"Other" category for all other nodes not submitted as either para-oes or gastric eg. Subcarinal, coeliac axis

OGJ tumours

- Siewert classification
- Gastric versus oesophageal dataset?

J. R. Siewert
H. J. Stein

"We have defined and described adenocarcinomas of the oesophagogastric junction as tumours that have their centre within 5 cm proximal and distal of the anatomical cardia and have differentiated the following three distinct tumour entities within this area[1,3]:

Type I tumour	Adenocarcinoma of the distal oesophagus which usually arises from an area with specialized intestinal metaplasia of the oesophagus (i.e. Barrett's oesophagus) and which may infiltrate the oesophagogastric junction from above.
Type II tumour	True carcinoma of the cardia arising from the cardiac epithelium or short segments with intestinal metaplasia at the oesophagogastric junction; this entity is also often referred to as 'junctional carcinoma'.
Type III tumour	Subcardial gastric carcinoma which infiltrates the oesophagogastric junction and distal oesophagus from below.

British Journal of Surgery 1998, 85, 1457–1459

Siewert Classification of OGJ Tumours

Type I

Type II

Type III

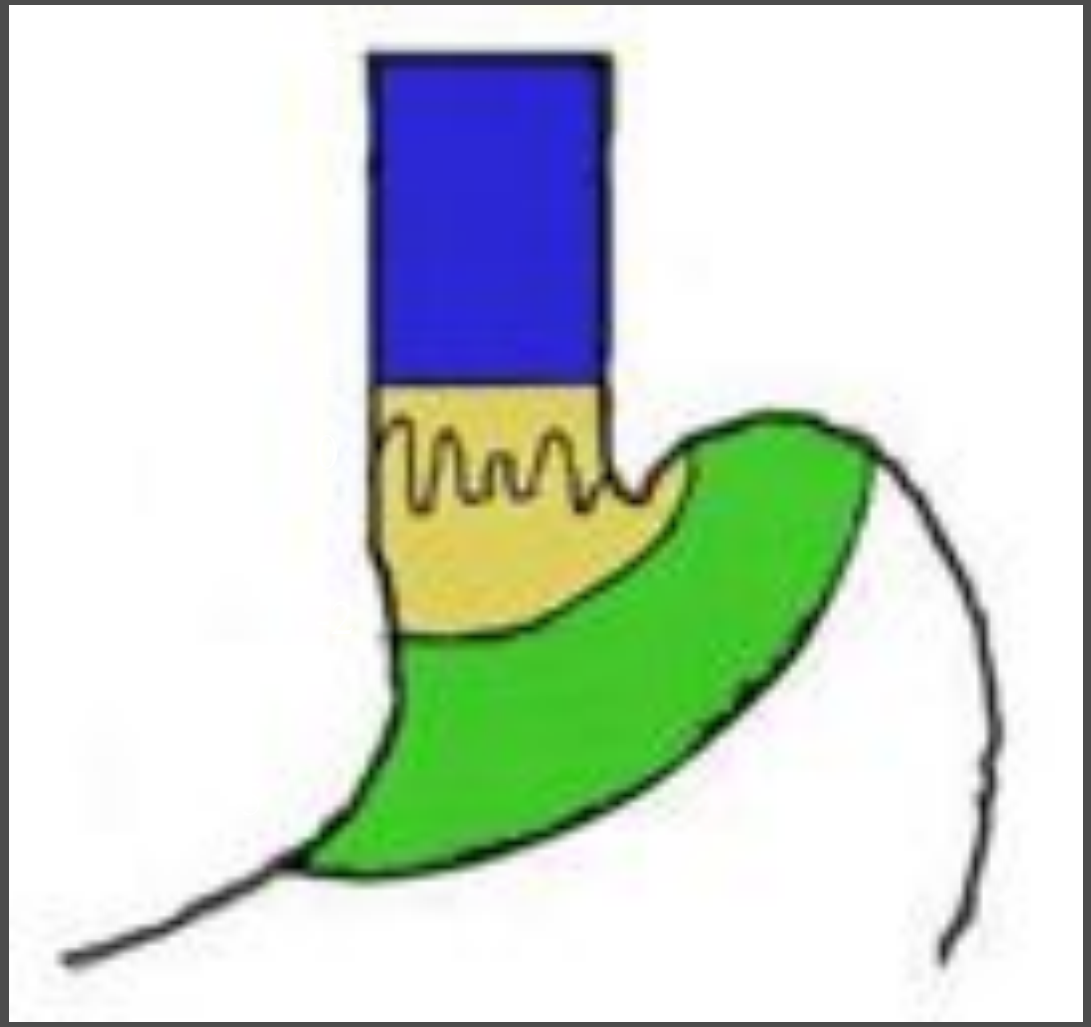

Siewert Classification of OGJ Tumours

cm

Type

Type

Type

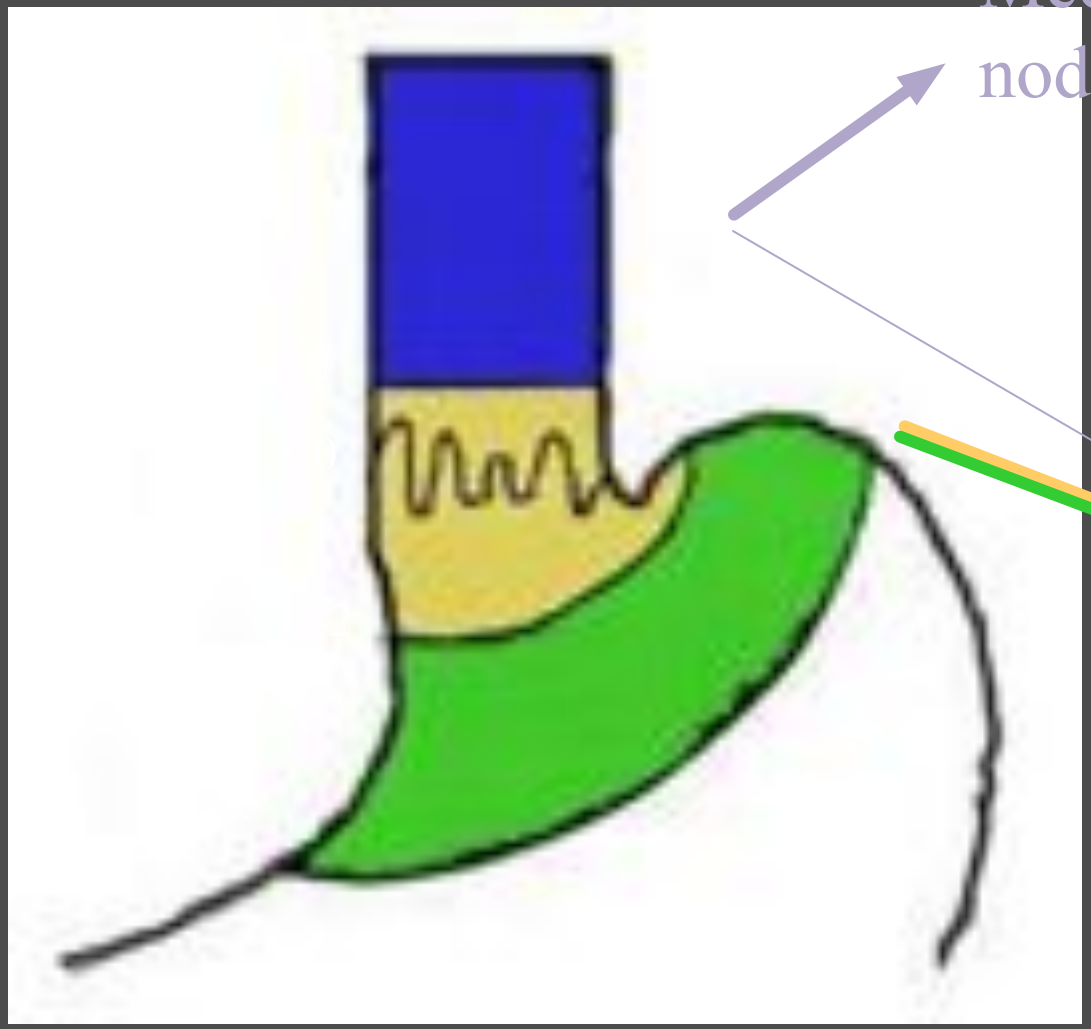

Mediastinal nodes

Abdominal nodes

Oesophagogastric junction

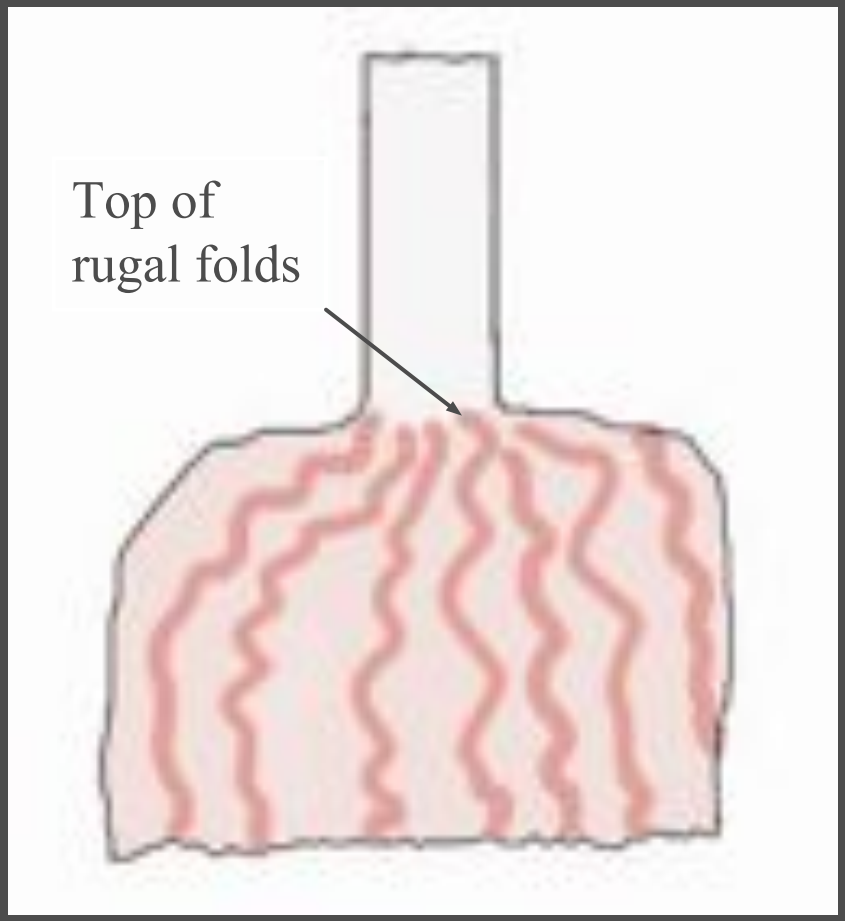

Mucosal aspect

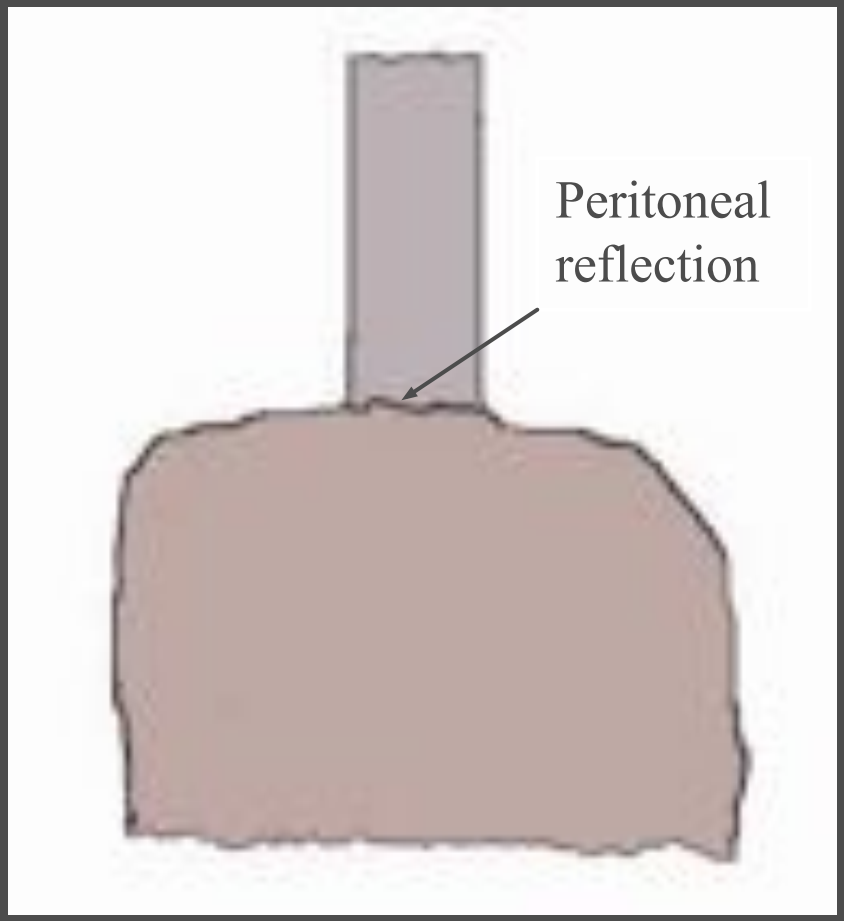

Serosal aspect

OG Junction

(note Barrett's)

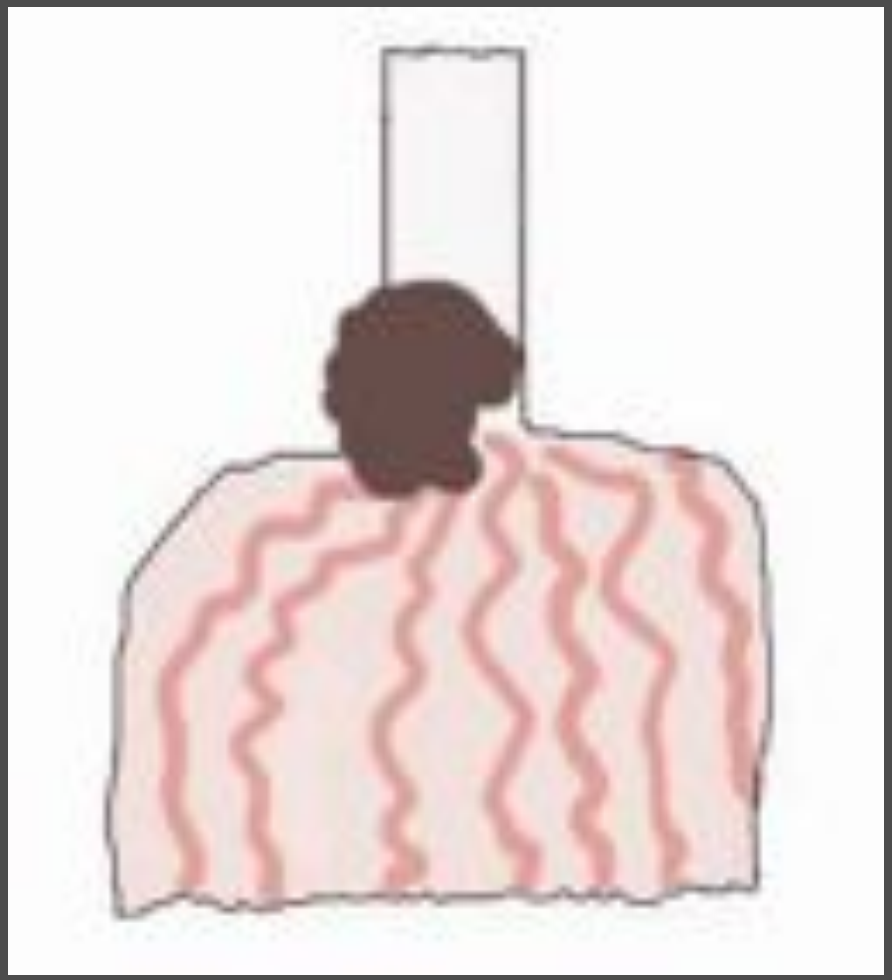

> 50% tumour in oesophagus

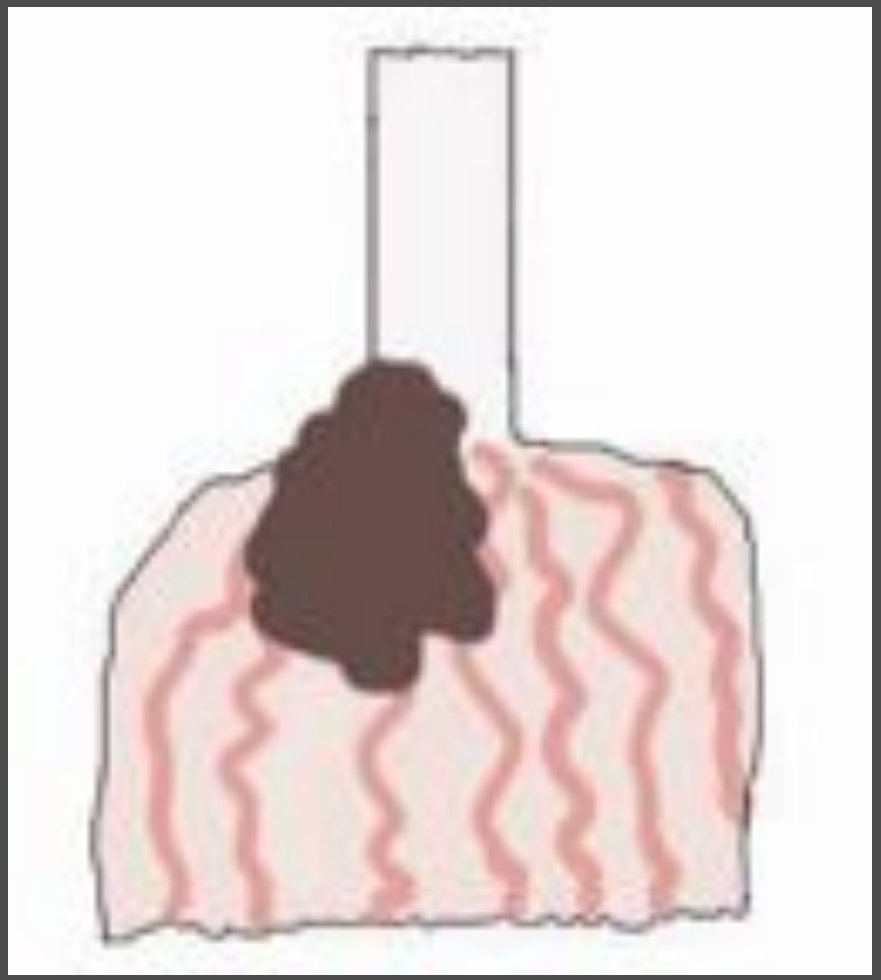

> 50% tumour in stomach

Oesophageal dataset

Gastric dataset

TNM6

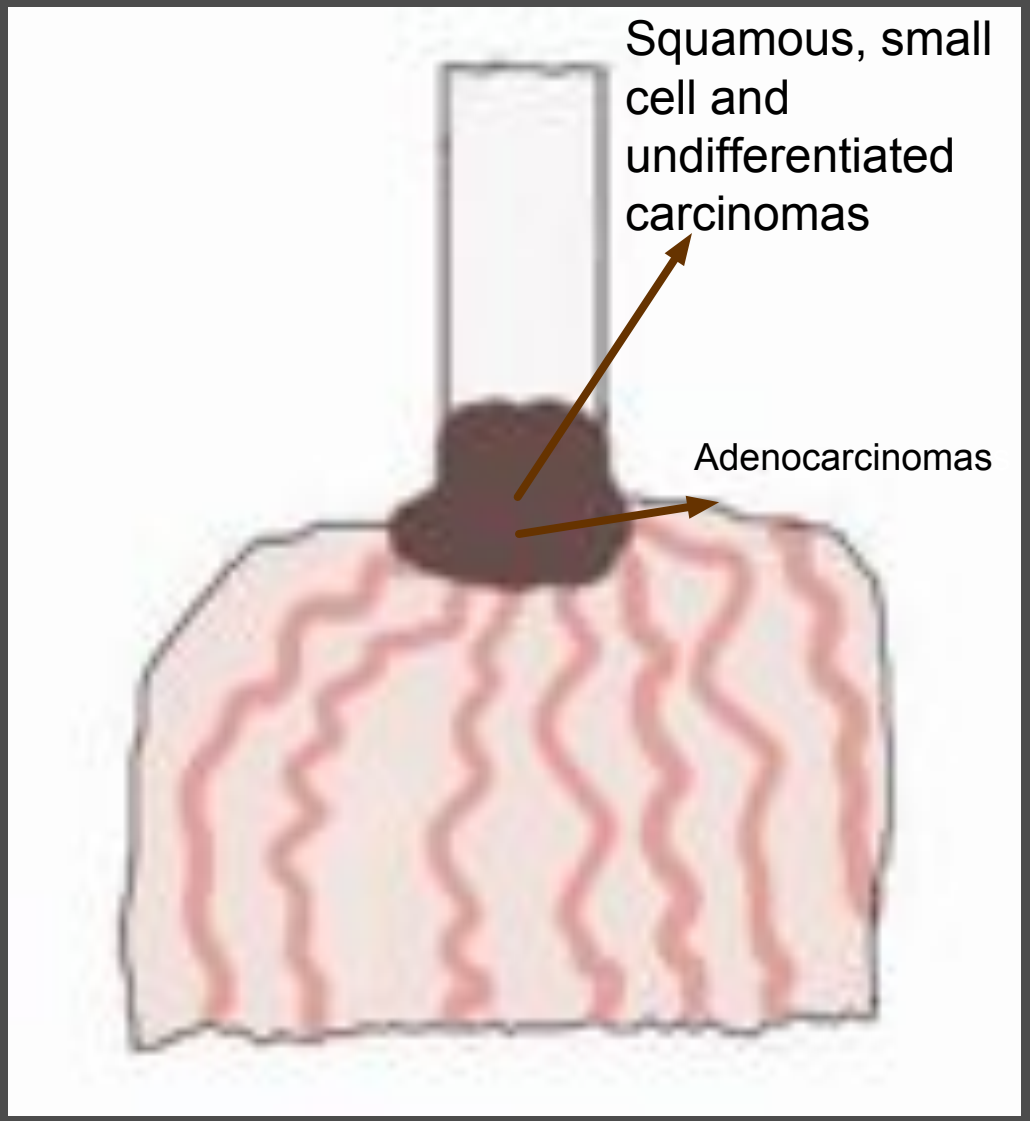

Oesophageal dataset

Gastric dataset

TNM6

Siewert type 2 tumours (50: 50)

TNM-7
Oesophagogastric junction tumours

A tumour the epicenter of which is within 5 cm of the esophagogastric junction and also extends into the oesophagus is classified and staged according to the **oesophageal** scheme

All other tumours with an epicenter in the stomach greater than 5 cm from the oesophagogastric junction or those within 5 cm of the EGJ *without* extension into the oesophagus are staged using the **gastric** carcinoma scheme

TNM-7
Oesophagogastric junction tumours

A tumour the epicenter of which is within 5 cm of the esophagogastric junction and also extends into the oesophagus is classified and staged according to the **oesophageal** scheme

All other tumours with an epicenter in the stomach greater than 5 cm from the oesophagogastric junction or those within 5 cm of the EGJ *without* extension into the oesophagus are staged using the **gastric** carcinoma scheme

Most tumours which involve the OGJ will be classified under oesophageal dataset

Stomach

Anatomy

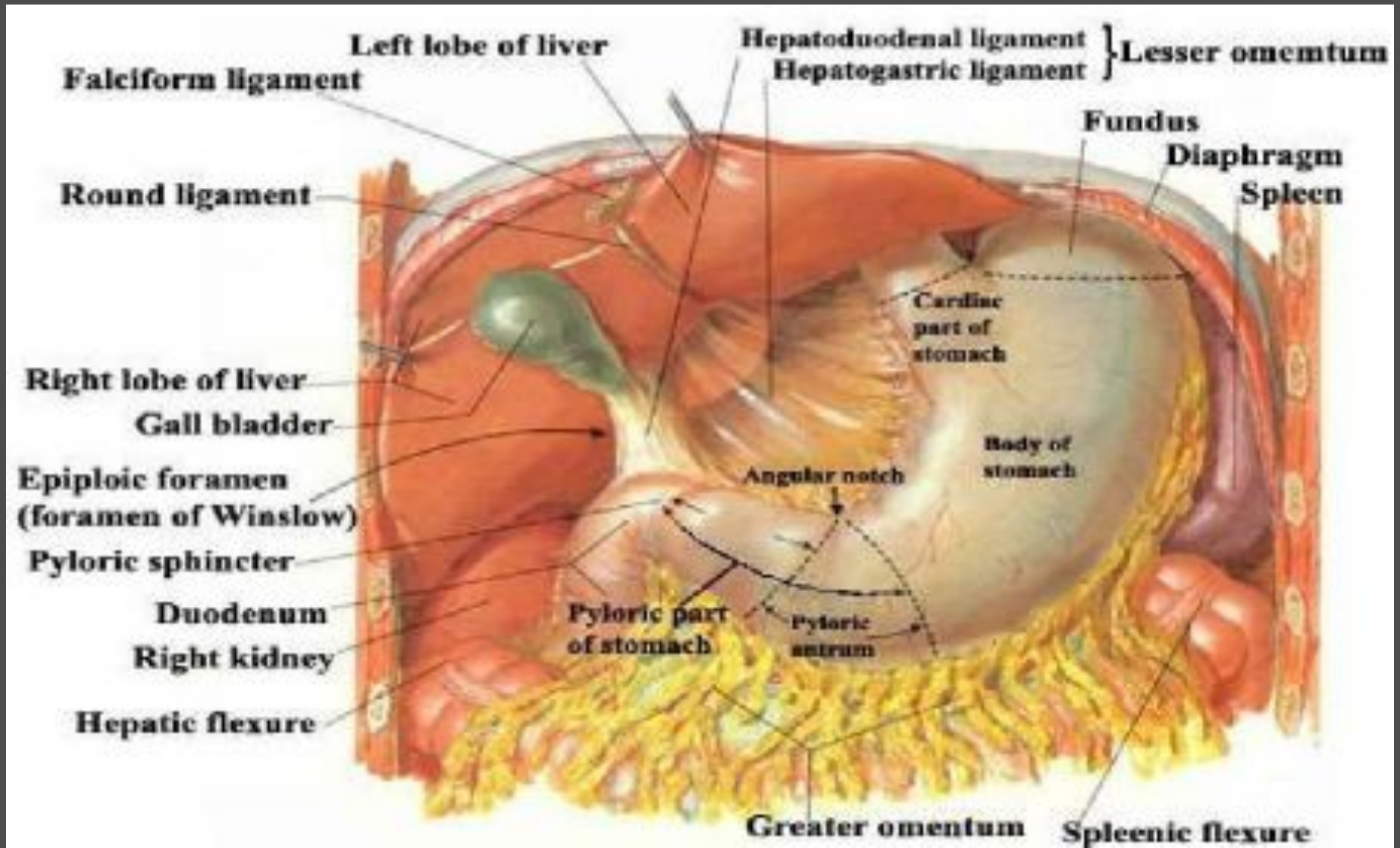
Left lobe of liver
Falciform ligament
Hepatoduodenal ligament
Hepatogastric ligament
Lesser omemtum
Fundus
Diaphragm
Spleen
Round ligament
Cardiac part of stomach
Right lobe of liver
Gall bladder
Body of stomach
Angular notch
Epiploic foramen (foramen of Winslow)
Pyloric sphincter
Duodenum
Pyloric part of stomach
Pyloric antrum
Right kidney
Hepatic flexure
Greater omentum
Spleenic flexure

STOMACH - RELATIONS

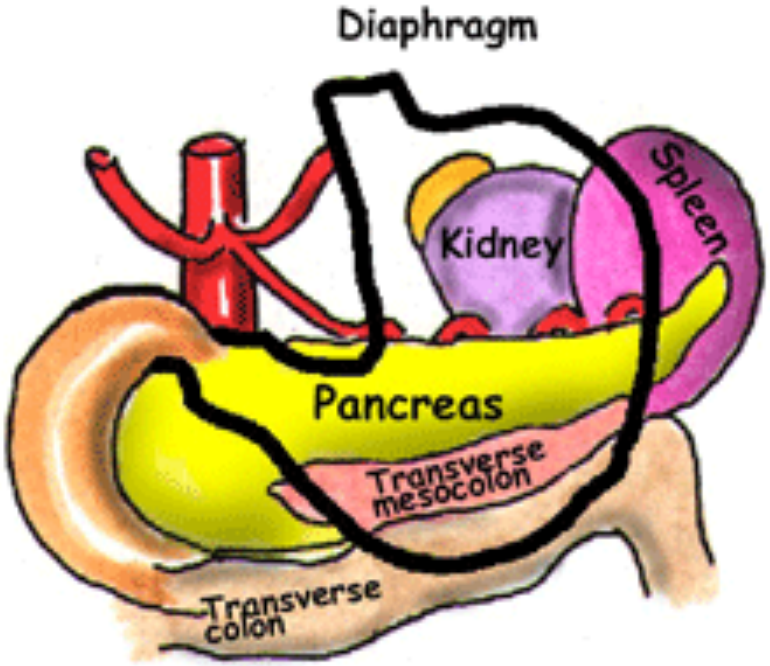

ANTERIOR
Abdominal wall
Left costal margin
Diaphragm
Left lobe of liver

SUPERIOR
Left dome of diaphragm

POSTERIOR
Lesser sac
Pancreas
Transverse mesocolon
Transverse colon
Left kidney/suprarenal gland
Spleen/splenic artery

Gastric resections

- Variety of operations:
  - Oesophagogastrectomy (Ivor Lewis)
  - Proximal gastrectomy
  - Distal gastrectomy
  - Subtotal/total/extended gastrectomy
  - Sleeve gastrectomy (usually for benign disease / bariatric procedures)

Gastric resections

- Open specimen and pin out where possible.
- Identify OGJ (if present).
- Lymph nodes (lesser curve, greater curve etc).
- Margins
  - Proximal
  - Distal
  - Circumferential (OGJ)
- Serosal involvement.

Stomach Lymphatic Drainage

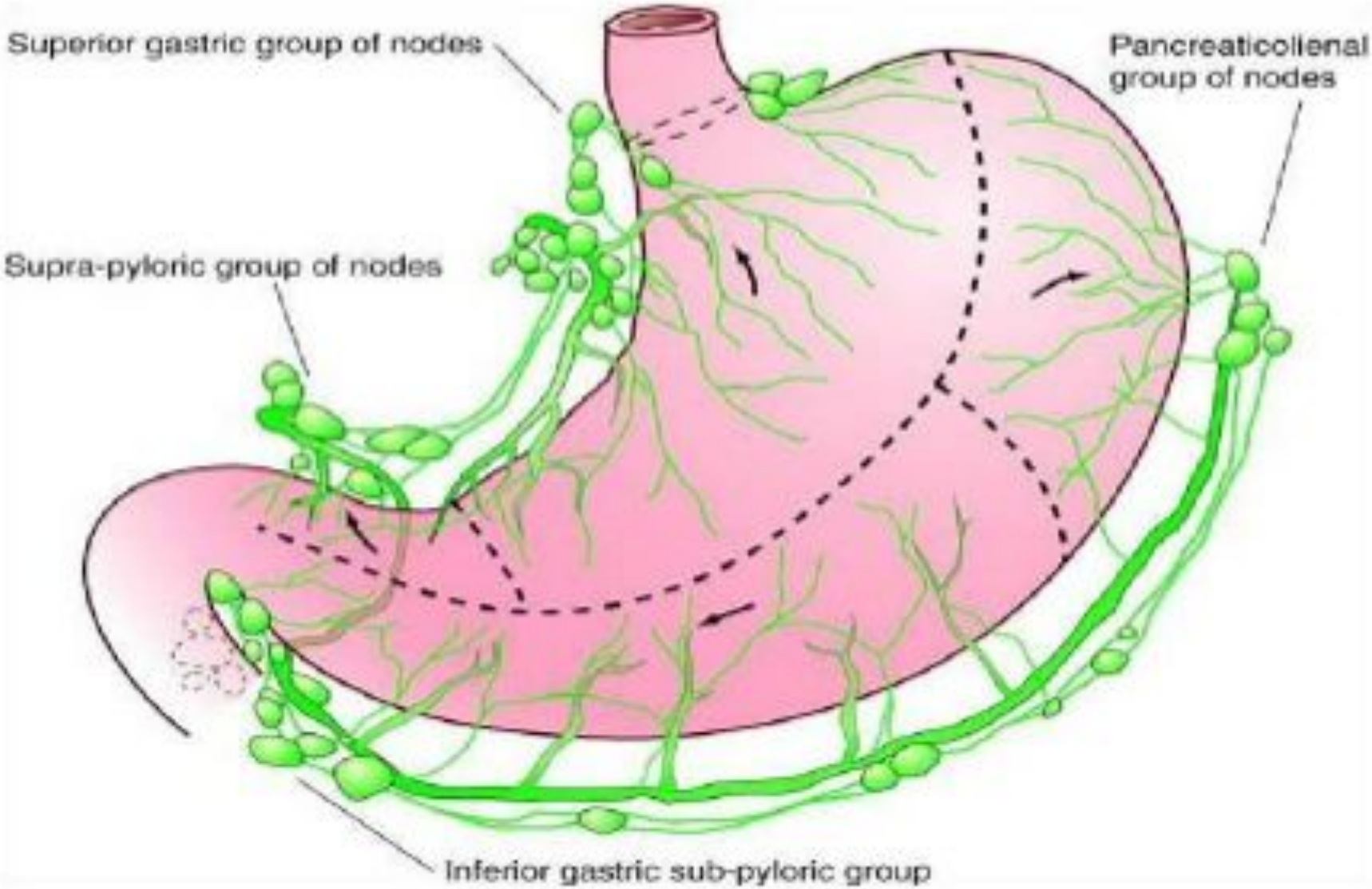

- Margins:
  - Where possible sample entire margin.
- Nodes:
  - OGJ, proximal lesser curve, distal lesser curve, proximal greater curve, distal greater curve.

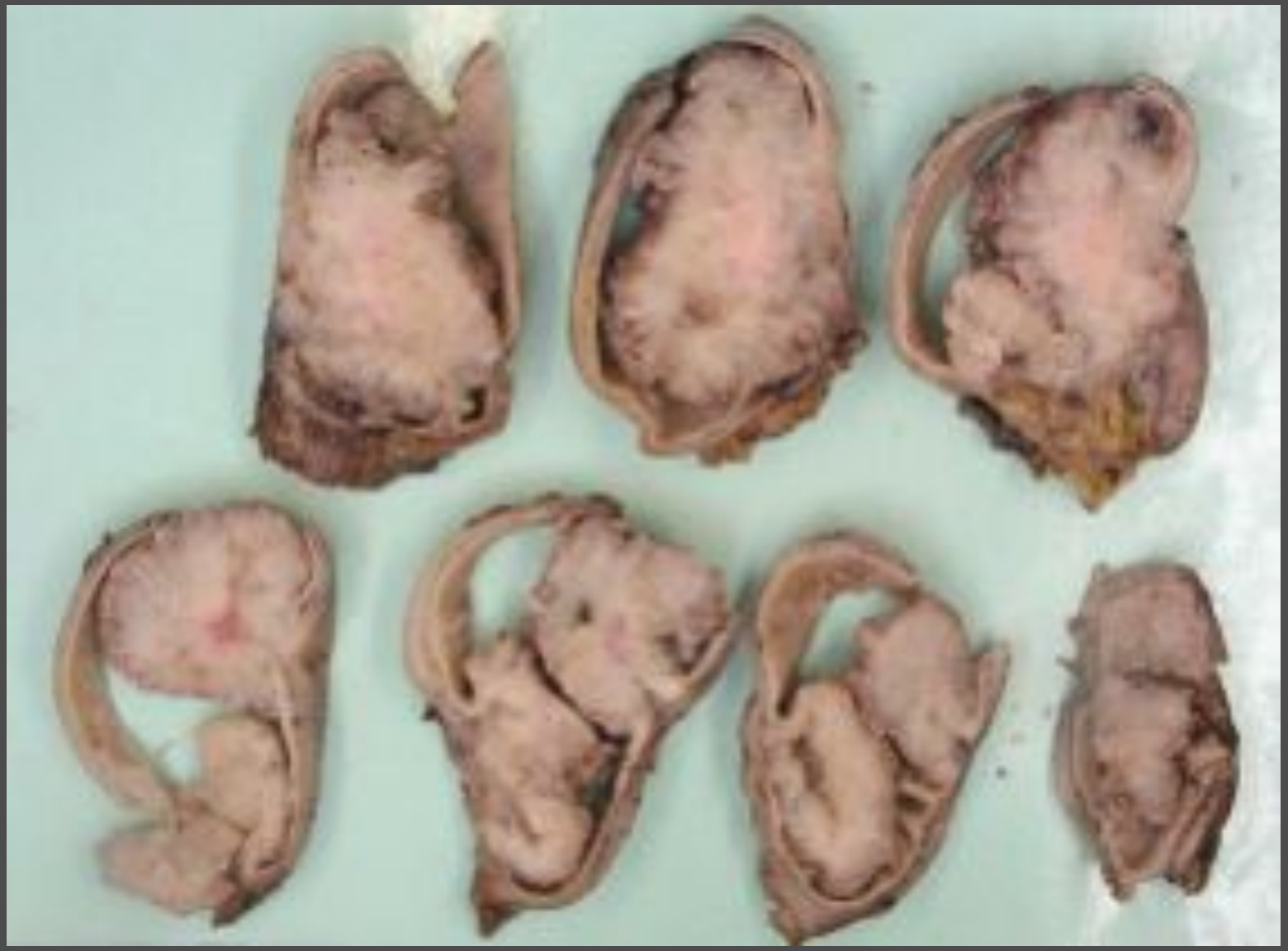

- Measure tumour in 3 dimensions + mm to margins
- Bread-slice tumour, lay out slices and photograph

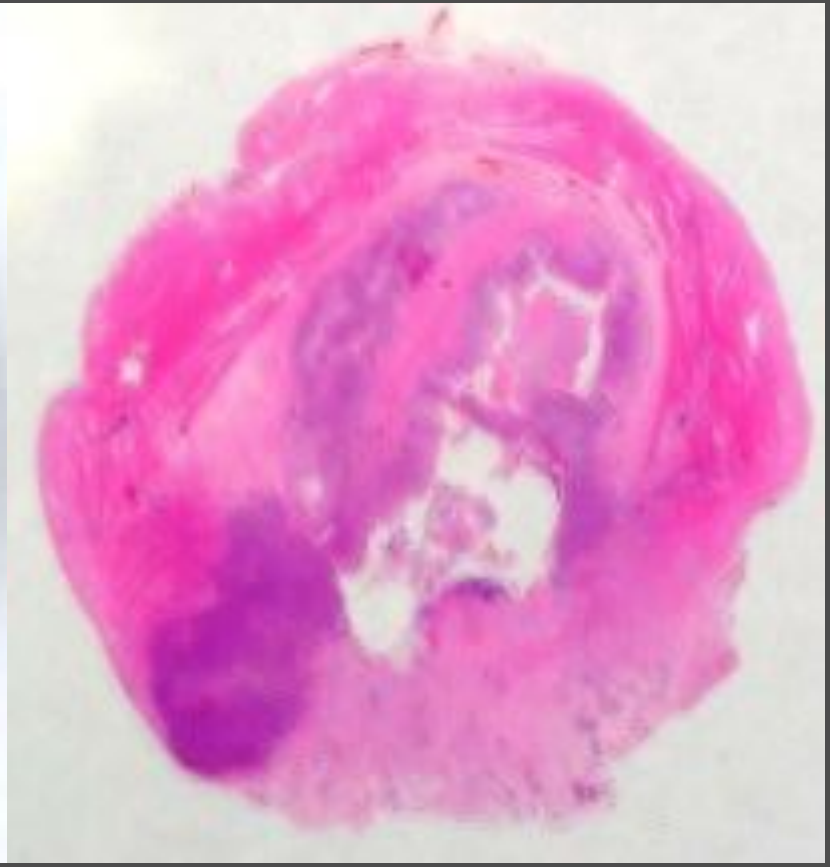

- 3+ blocks of tumour (+/- megablock).
- Sample:
  - Extension into perigastric connective tissue.
  - Circumferential margin at OGJ.
  - Serosal involvement.

Normal histology

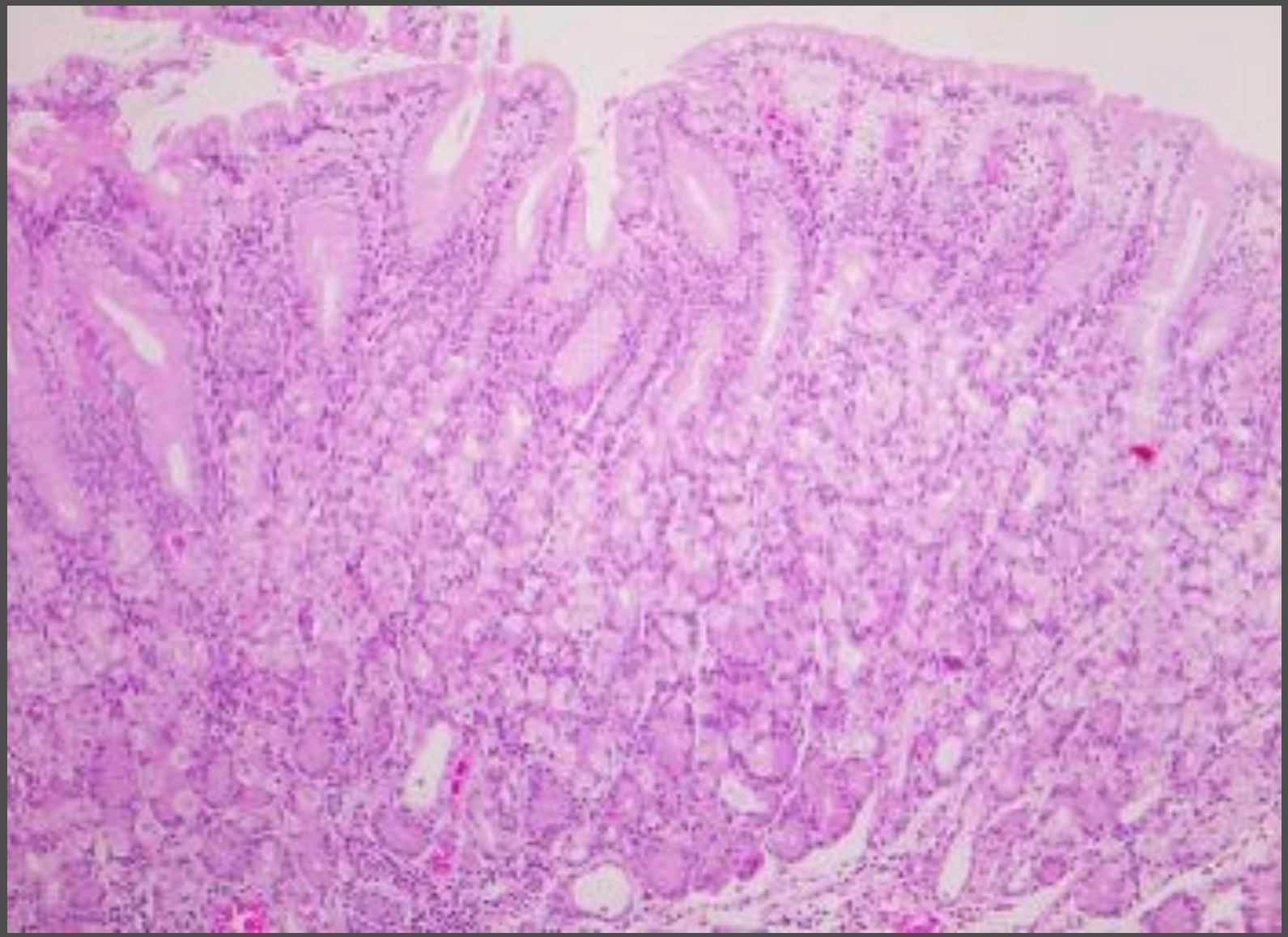

Normal histology

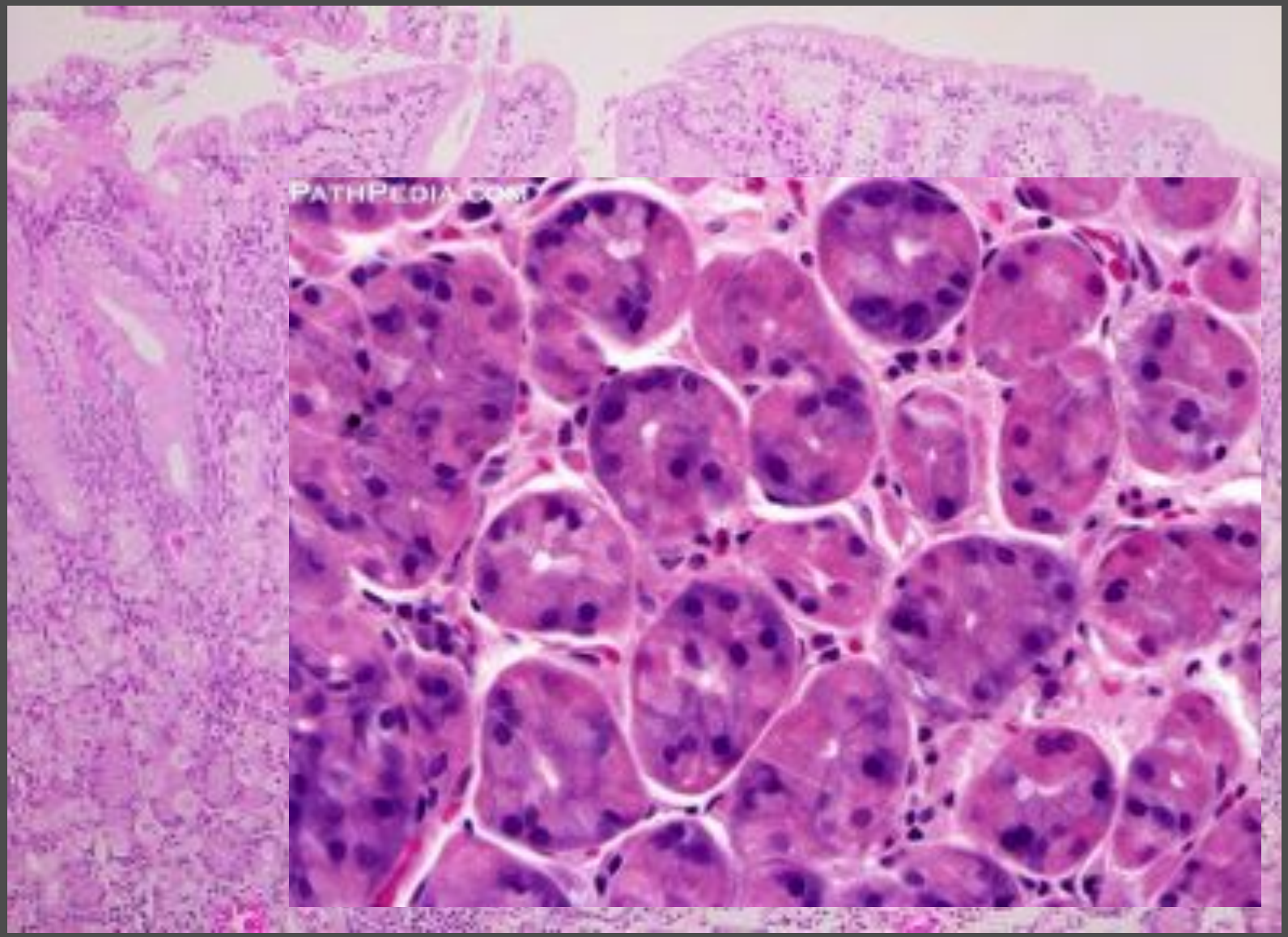

Normal histology

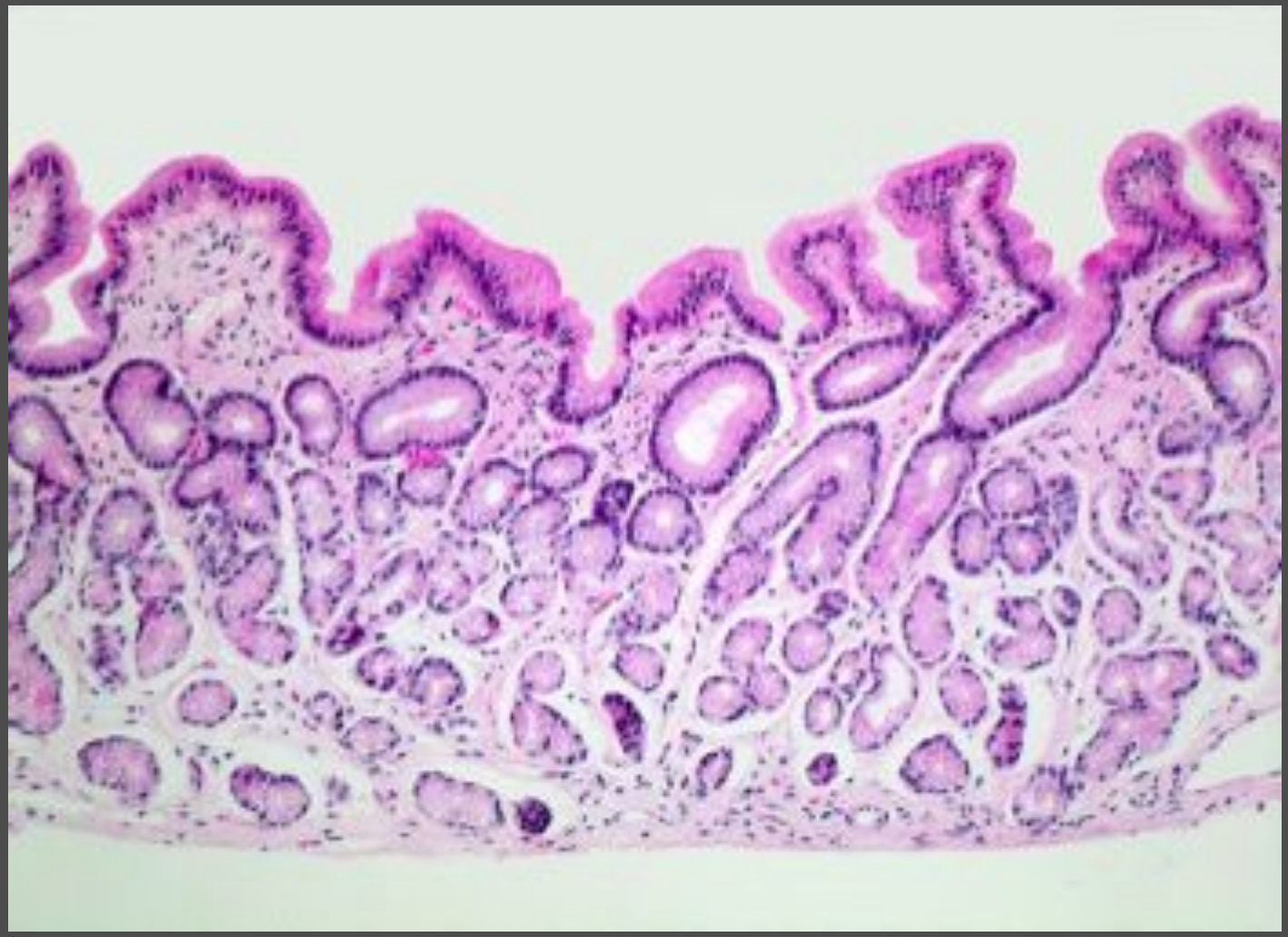

Case study 4

- 82 year old male, inflammation and ulceration in the antrum
- Clo test positive

PathKids.com

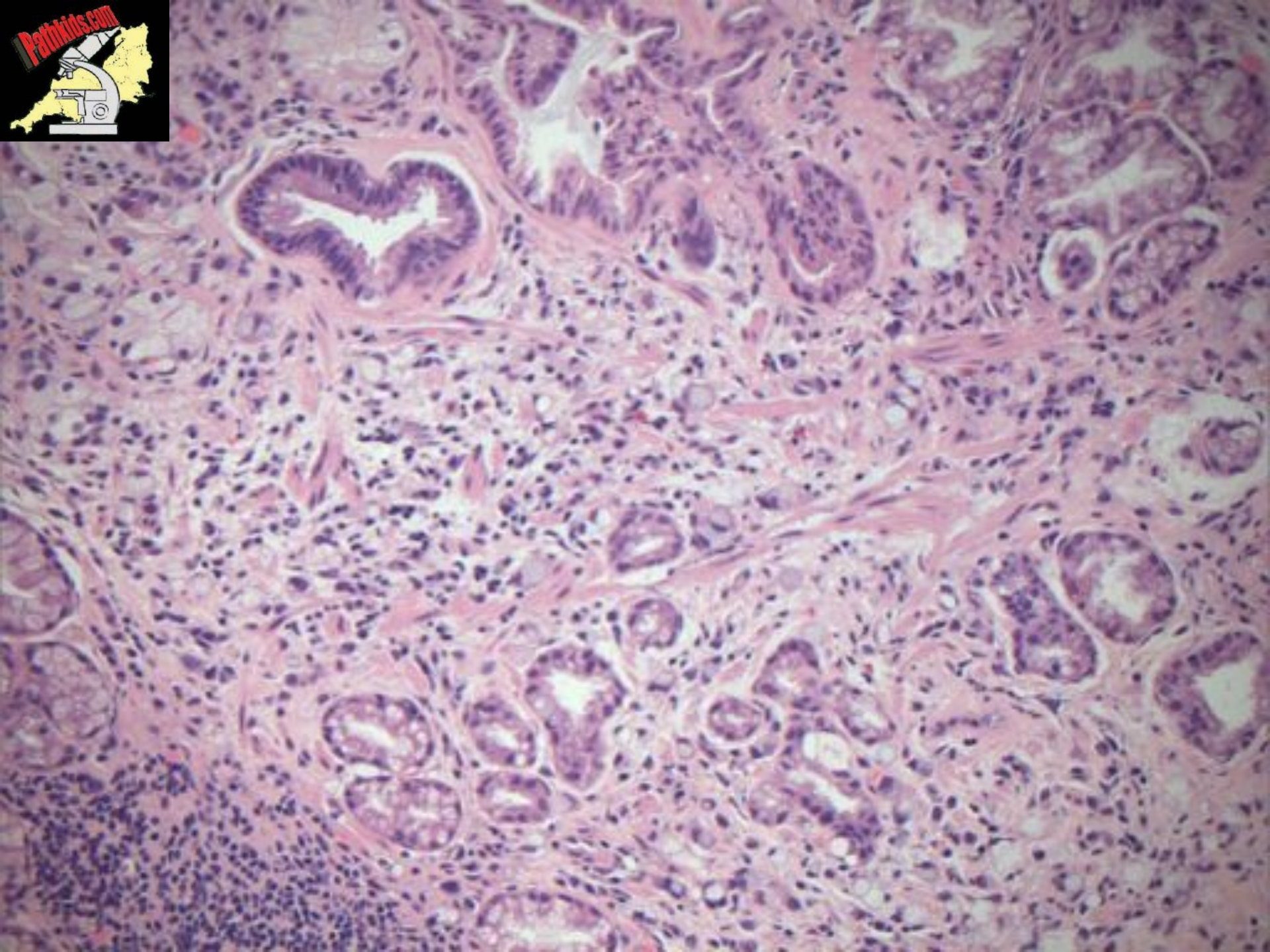
PathKids.com

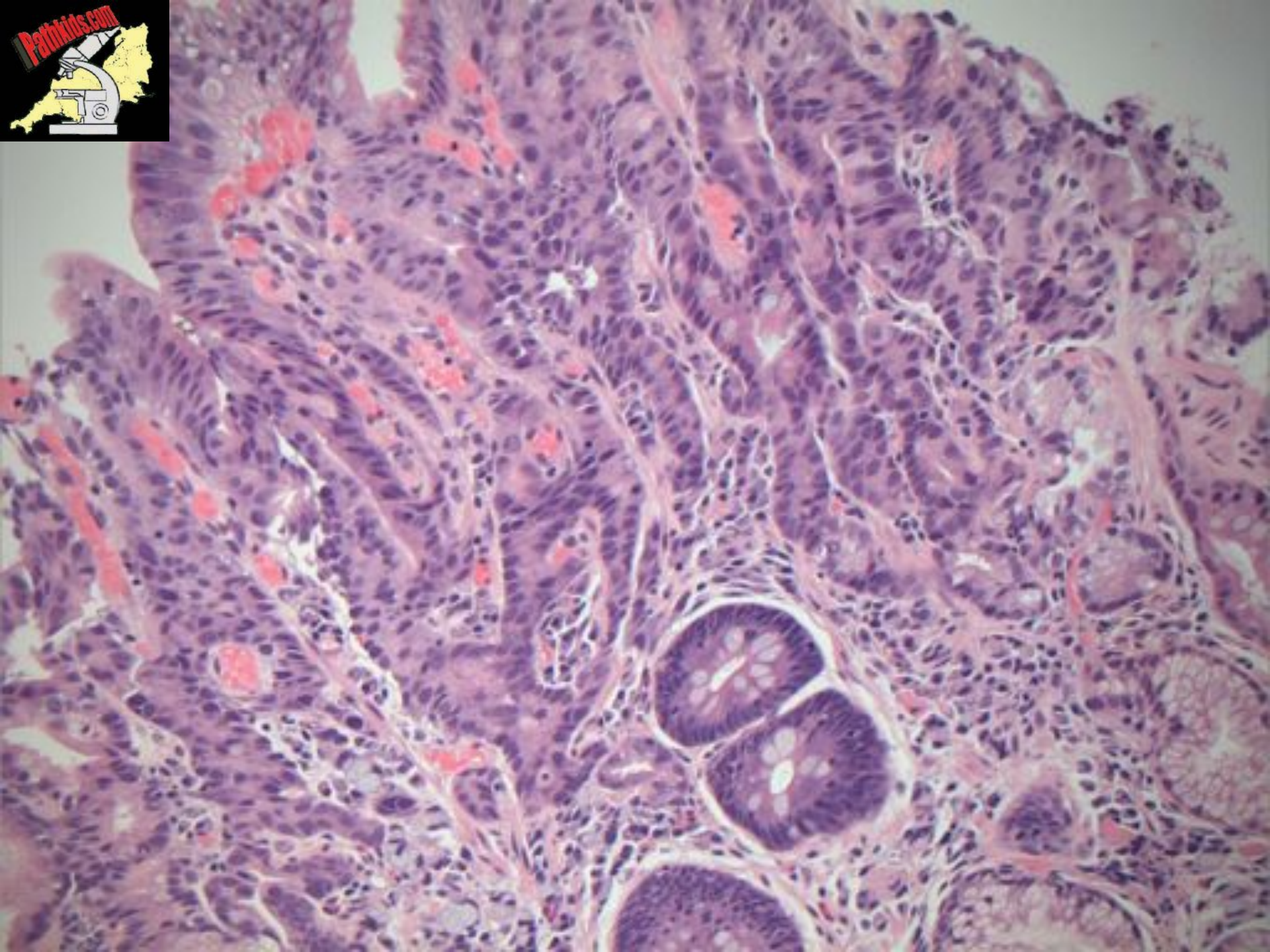
PathKids.com

Case study 4

- Diffuse poorly differentiated non-cohesive adenocarcinoma with signet ring differentiation
- Often distal stomach “gastric outlet obstruction” but with no discrete mass
- Linitis plastica / leather bottle stomach
- More common in young (HDGC, globoid /crypt neck dysplasia)
- Commonly understaged, often no stromal reaction

Signet ring adenocarcinoma

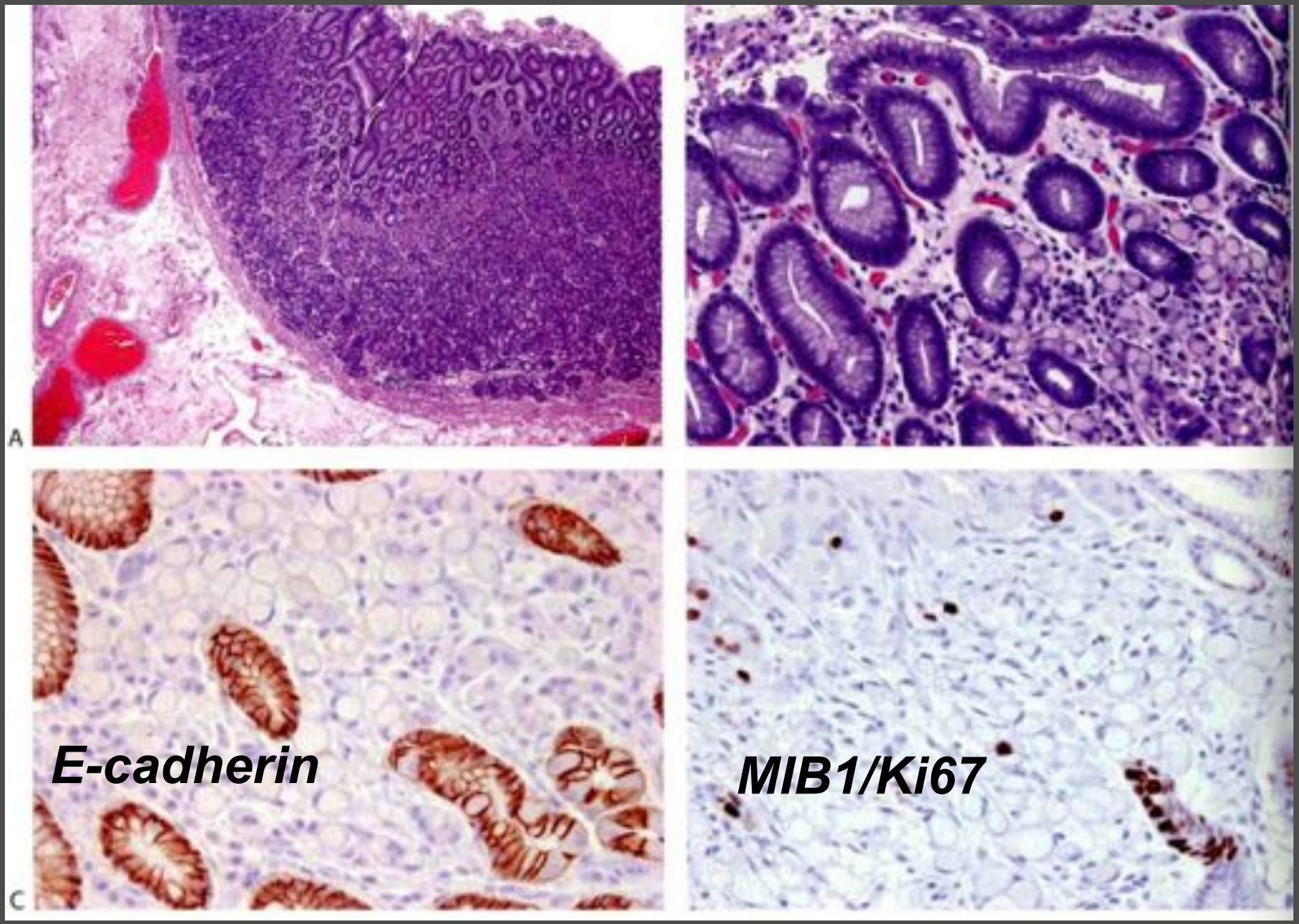

Very difficult frozen section diagnosis – look up previous histo!

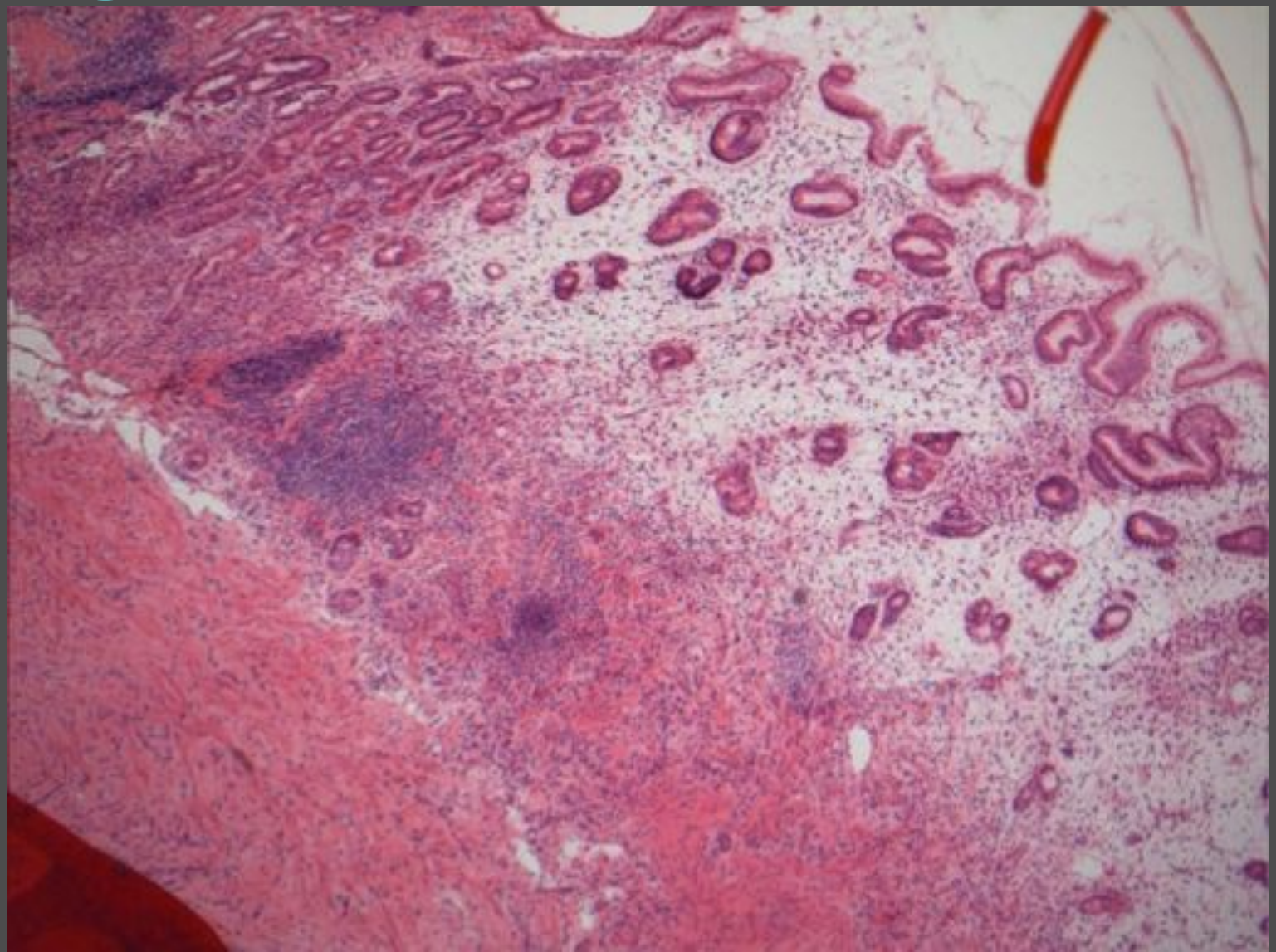

Very difficult frozen section diagnosis – look up previous histo!

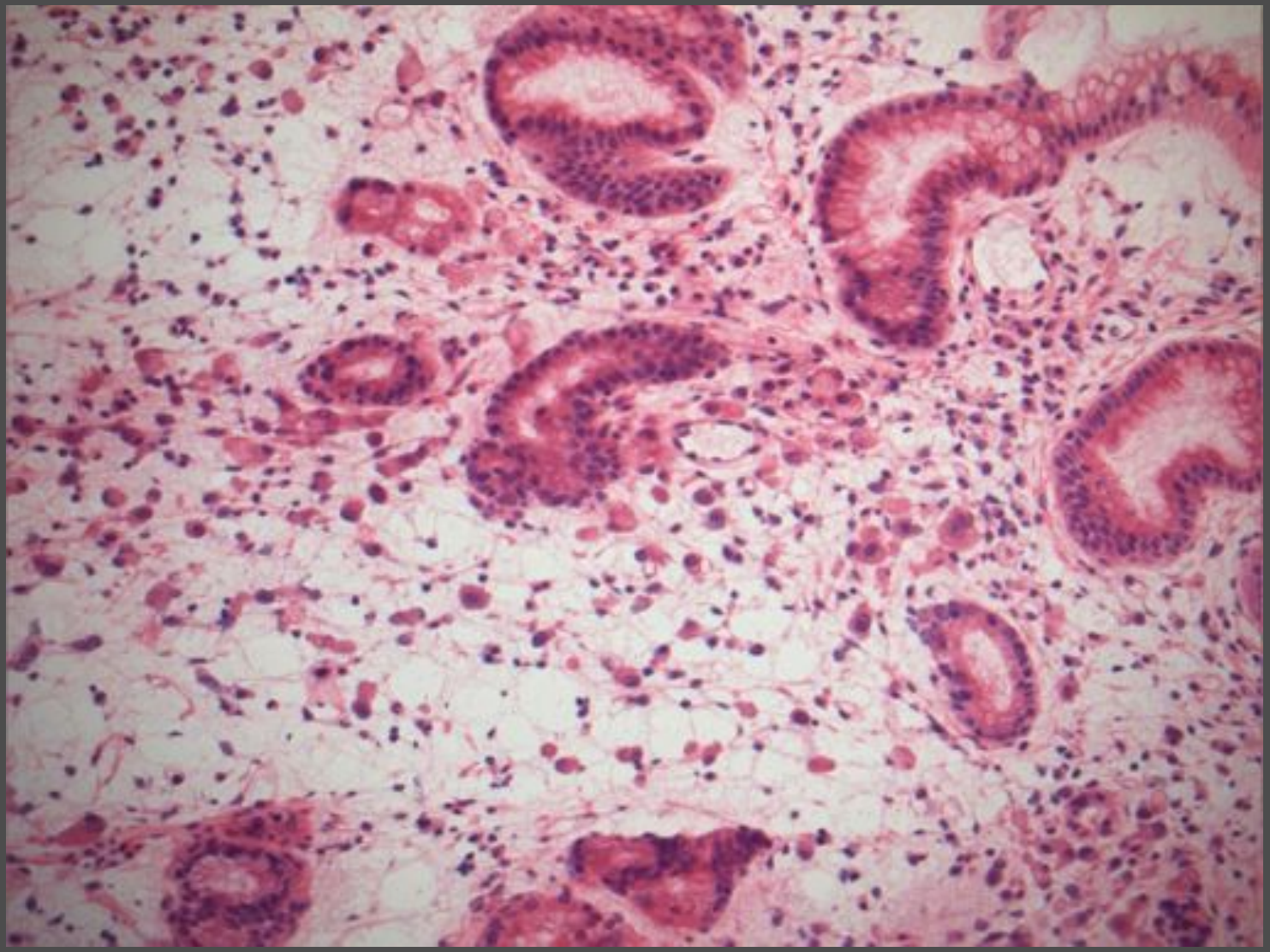

….. Cytokeratin can help (later)

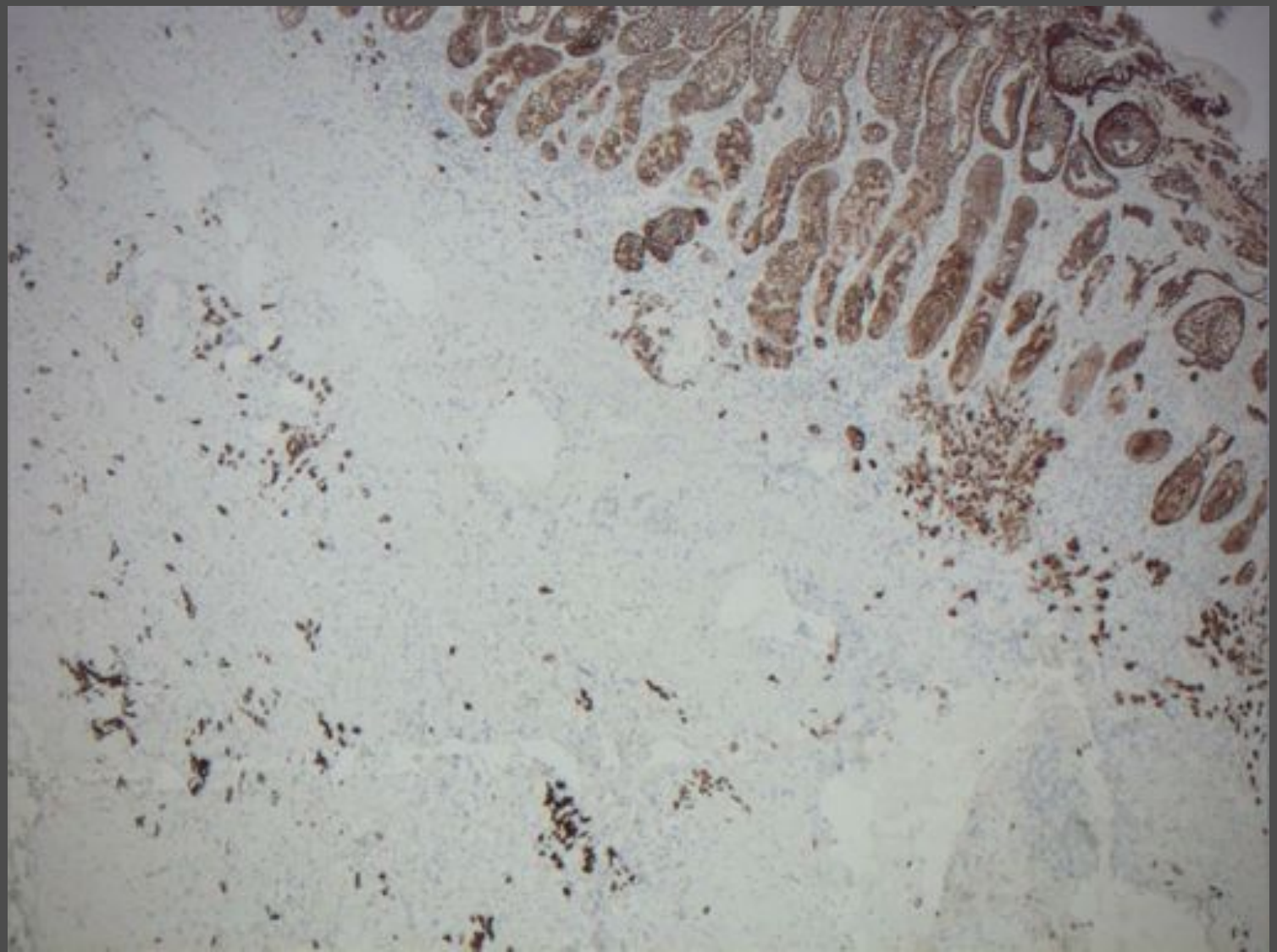

Intestinal adenocarcinoma can be preceded/accompanied by dysplasia in flat or polypoid mucosa

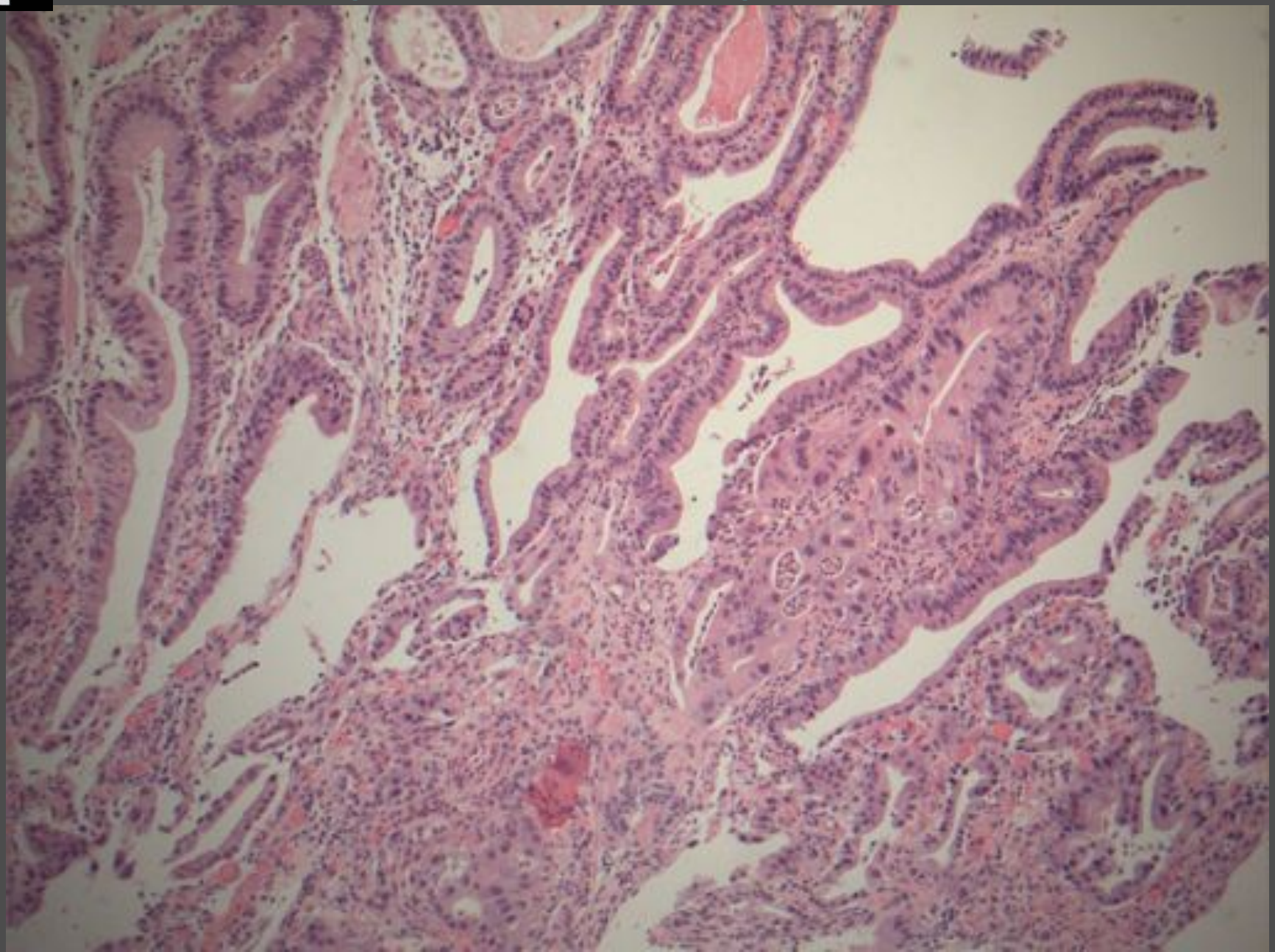

Intestinal adenocarcinoma can be preceded/accompanied by dysplasia in flat or polypoid mucosa

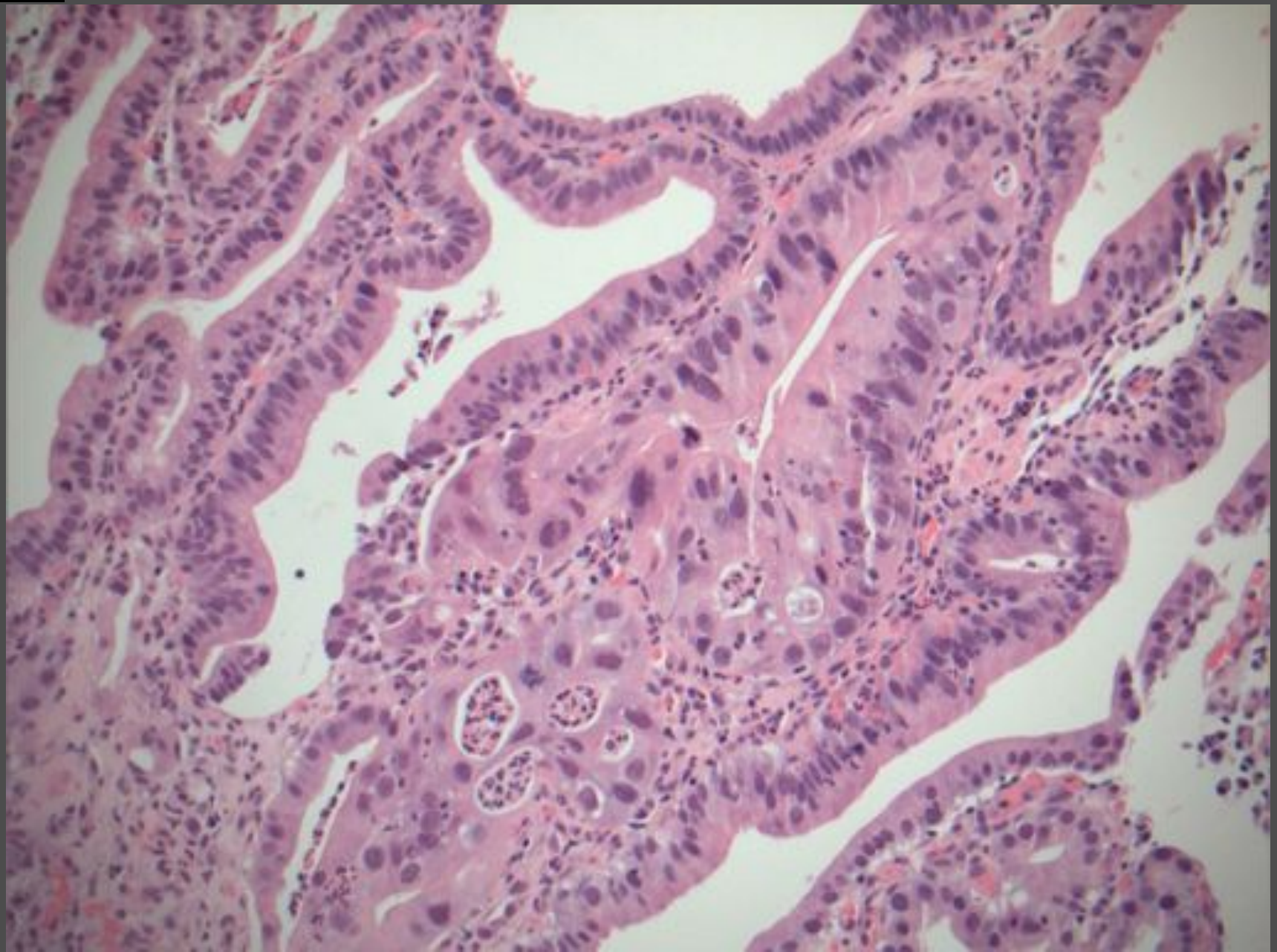

Case study 5

- 59 year old female, nodule in gastric body

?fundic gland polyps ?small GIST

Subsequently found to have multiple nodules all less than 1cm in body and fundus

Referred for EMR excision

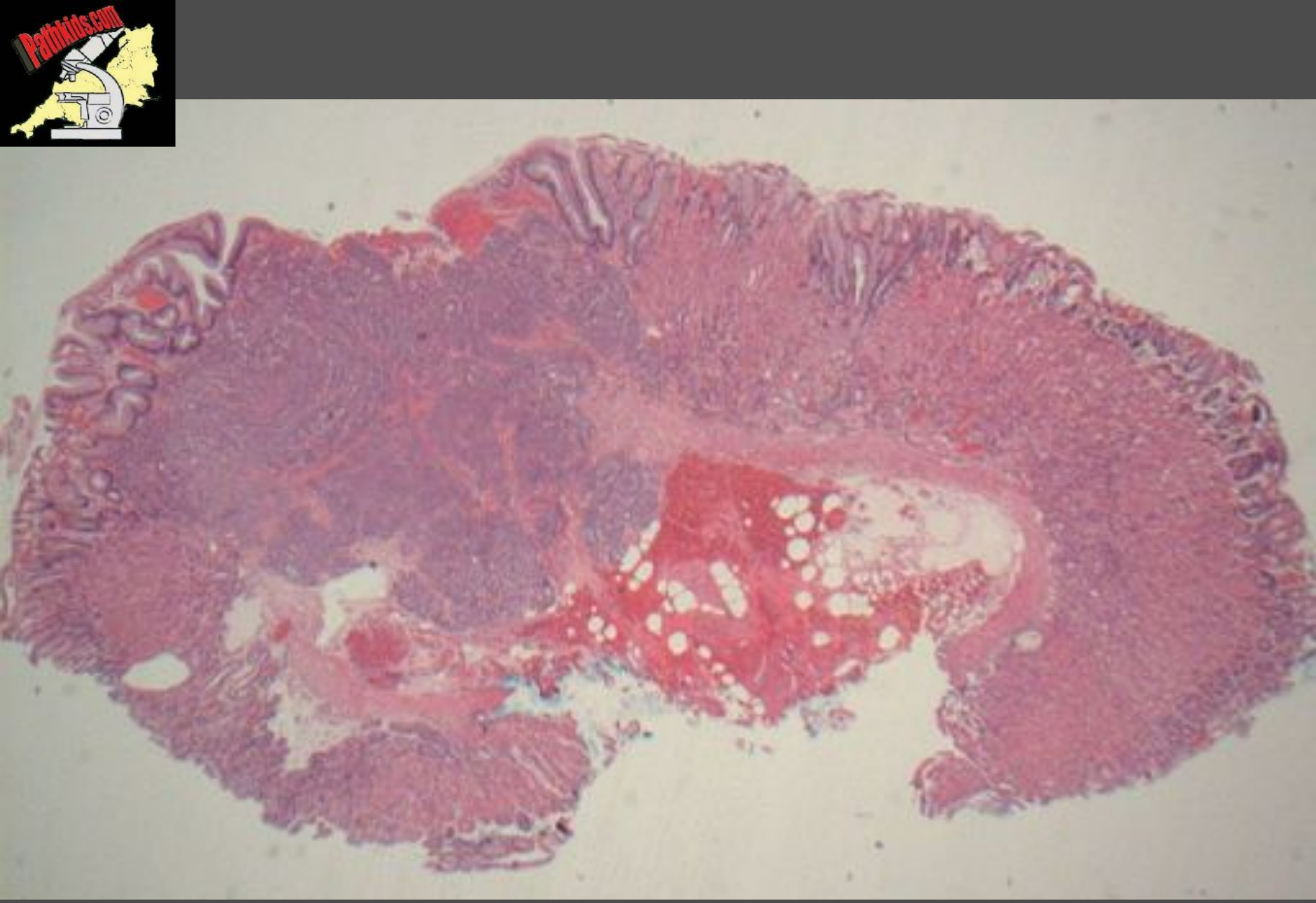
PathKids.com

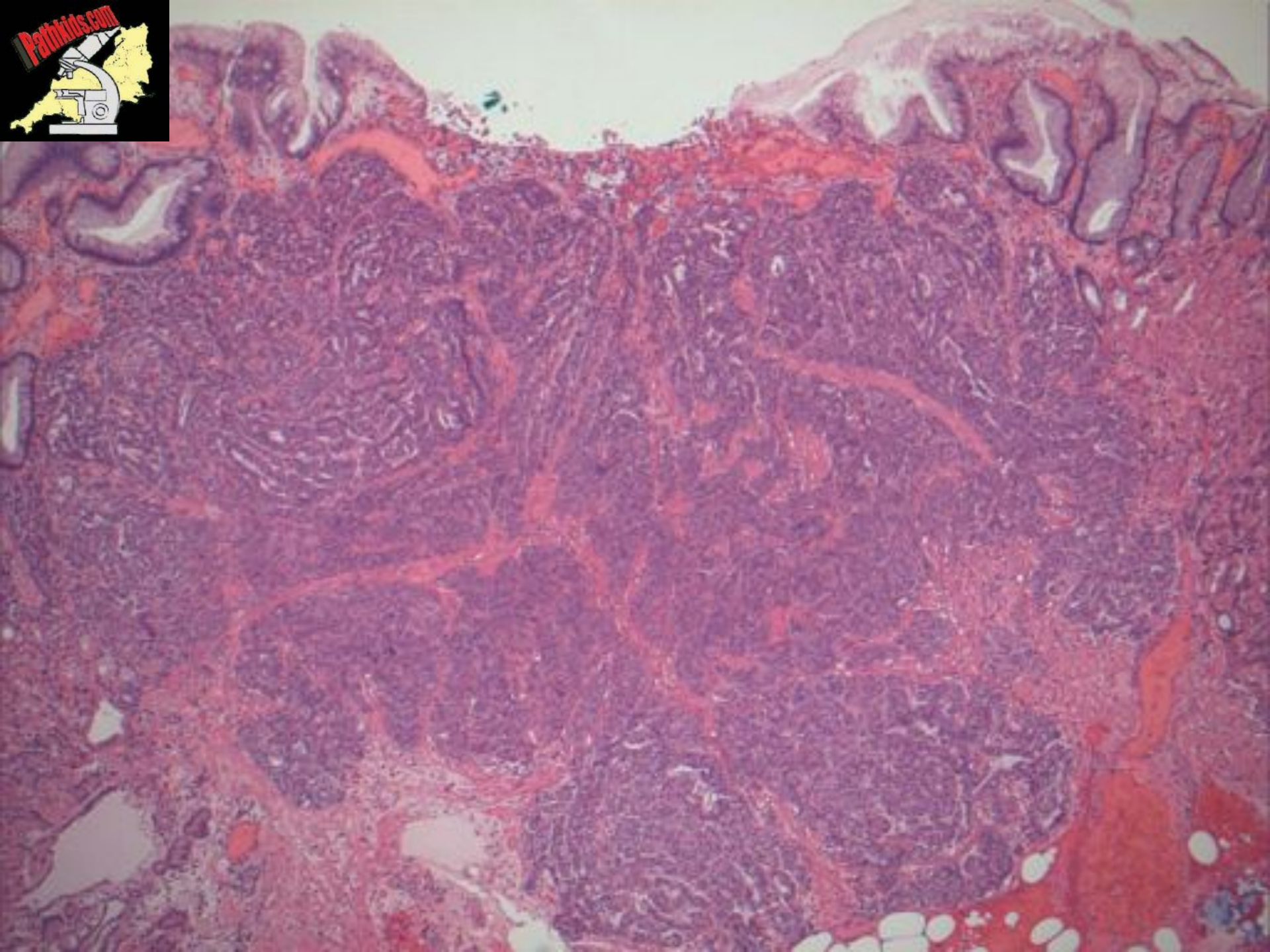
PathKids.com

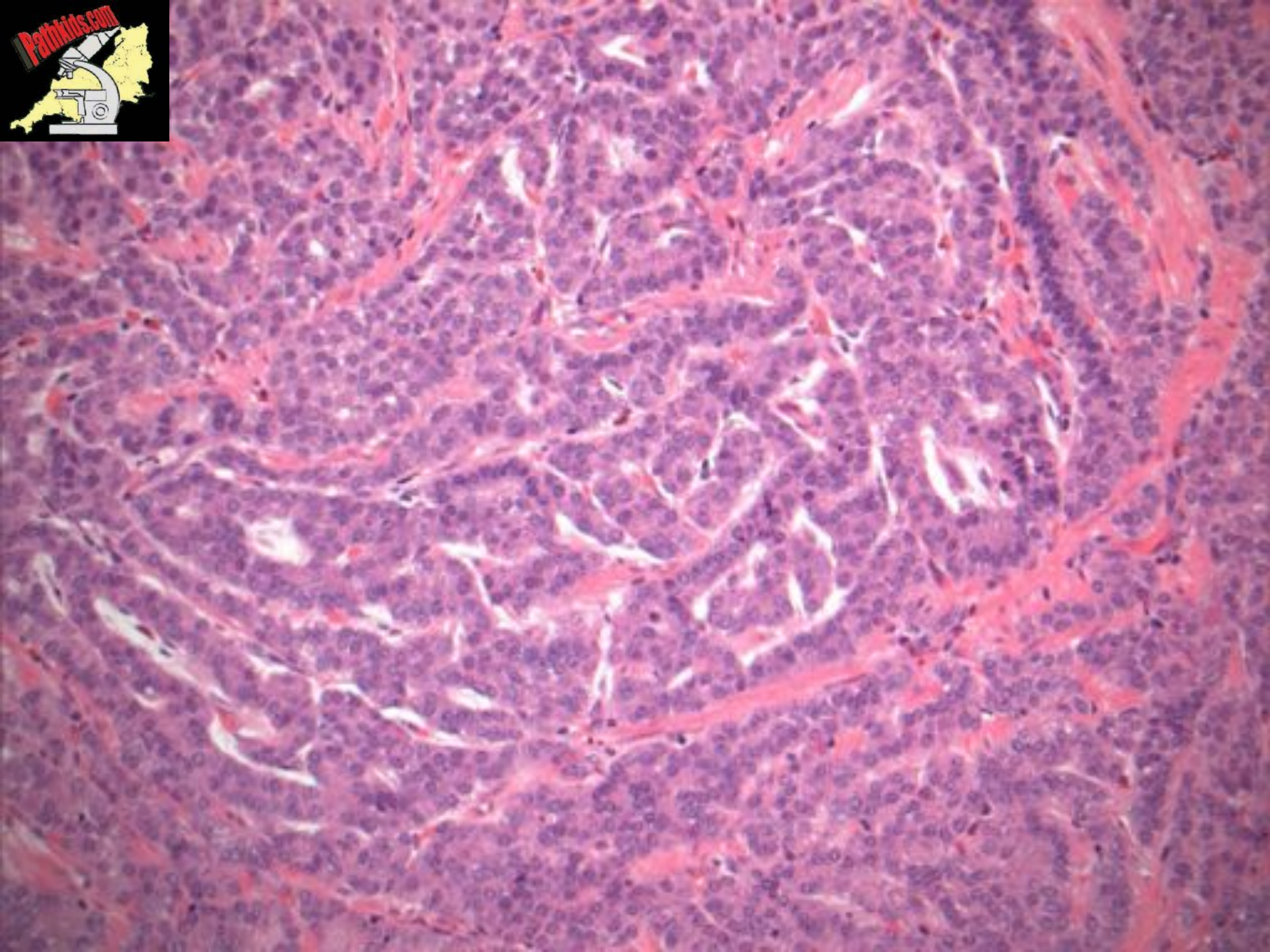
PathKids.com

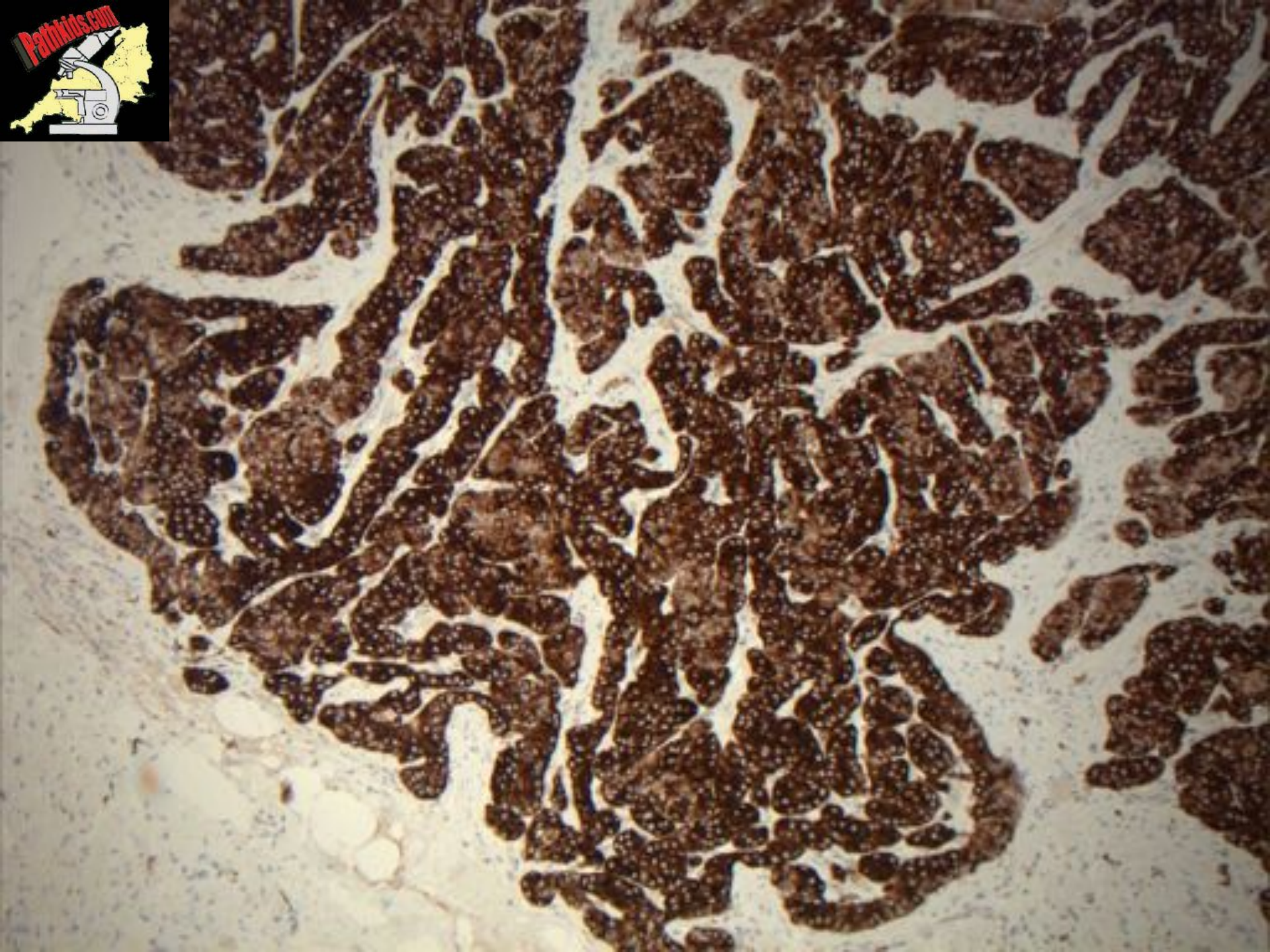
PathKids.com

Case study 5

- Diagnosis – multiple carcinoid tumours
- Correct definition well differentiated endocrine tumour (where tumour is more than 0.5mm)
- G1 (NET G1): mitotic count <2 per 10 high power fields (HPF) or Ki67 index <=2%
- Submucosal invasion but no vascular invasion
- Background mucosa showed no evidence of atrophy

Subclassification of GET/carcinoid

- **Type 1**
  - *In patients with autoimmune chronic atrophic gastritis*
  - Occur in 5-10%, usually women, mean age 63 years
  - ECL hyperplasia and hypergastrinemia secondary to parietal cell loss, in fundus/body
  - 57% multifocal
  - 97% < 1.5 cm
  - 91% limited to mucosa or submucosa
  - Only 2-5% associated with liver metastases. Grade 1, indolent course, almost never fatal

Type 2
- *In patients with Zollinger-Ellison syndrome, usually also MEN1*
- No gender predilection, mean age 50 years
- *ECL cell hyperplasia* and hypergastrinemia
- Usually multicentric in body/fundus
- 23% > 1.5 cm, 30% with local nodal metastases, 10% with liver metastases
- Death more likely from gastrinomas of Z-E syndrome than from the carcinoid tumors

Type 3 gastric endocrine tumor:
- Sporadic, not related to hypergastrinemia or ECL cell hyperplasia
- Usually solitary, may not be in body/fundus
- 74% in men, mean age 55 years
- 76% deeply invasive, 71% have nodal metastases, distant metastases common

Type 4 gastric endocrine tumor:
- Very rare, due to defective gastric acid secretion
- Metastases only to regional lymph nodes and liver, but patients may still have long term surviva

Appendix I WHO classification of gastrointestinal[6] and pancreatic endocrine tumours[12]

Site	Well differentiated endocrine tumour (Benign behaviour)	Well differentiated endocrine tumour (Uncertain behaviour)	Well differentiated endocrine carcinoma (Low grade malignant)	Poorly differentiated endocrine carcinoma (High grade malignant)
Pancreas	Confined to pancreas Functioning insulinoma <20mm Non-functioning tumours <20mm No vascular invasion No perineural invasion <2 mitoses/HPF / Ki-67 index ≤2%	Confined to pancreas and one or more of the following: ≥20mm Perinneural invasion Vascular invasion 2-10 mitoses/HPF/ Ki-67 index >2%	Invasion of adjacent organs presence of metastases	High grade, poorly differentated large cell, intermediate cell or small cell carcinoma. Ki-67 index >30%
Stomach	Non-functioning Confined to mucosa-submucosa Size ≤10 mm. No vascular invasion	Non-functioning Confined to mucosa-submucosa Size >10-20 mm without vascular invasion Size up to 20mm with vascular invasion	Functioning tumour of any size Non-functioning tumour >20mm or of any size with invasion beyond submucosa and/or metastases. Ki-67 index 2-30%	High grade, poorly differentated large cell, intermediate cell or small cell carcinoma. Ki-67 index >30%
Duodenum and Upper jejunum	Non-functioning Confined to mucosa-submucosa Size ≤10 mm No vascular invasion Gangliocytic paraganglioma of any size	Non-functioning tumour or functioning gastrinoma Confined to mucosa-submucosa Size >10mm or ≤10 mm with vascular invasion	Functioning or non-functioning tumour of any size with invasion beyond submucosa and/or metastases. Ki-67 index 2-30%	High grade, poorly differentated large cell, intermediate cell or small cell carcinoma. Ki-67 index >30%
Distal Jejunum, Ileum	Non-functioning Confined to mucosa-submucosa Size ≤10 mm No vascular invasion	Non-functioning Confined to mucosa-submucosa Size ≤10 mm Vascular invasion	Functioning tumour of any size Non-functioning tumour >10mm or of any size with invasion beyond submucosa and/or metastases. Ki-67 index 2-30%	High grade, poorly differentated large cell, intermediate cell or small cell carcinoma. Ki-67 index >30%
Appendix	Non-functioning Confined to appendiceal wall Size <20 mm No vascular invasion	Non-functioning Extension into mesoappendix Vascular invasion >20-25 mm	Functioning tumour of any size Non-functioning Deep invasion into mesoappendix Size >25 mm and/or metastases. Ki-67 index 2-30%	High grade, poorly differentated large cell, intermediate cell or small cell carcinoma. Ki-67 index >30%
Colon, Rectum	Non-functioning Confined to mucosa-submucosa Size <20 mm No vascular invasion	Non-functioning Confined to mucosa-submucosa Size <20 mm Vascular invasion	Functioning tumour of any size Non-functioning tumour >20mm or of any size with invasion beyond submucosa and/or metastases. Ki-67 index 2-30%	High grade, poorly differentated large cell, intermediate cell or small cell carcinoma. Ki-67 index >30%

Note: the term functioning is defined as causing a hormonal syndrome, NOT containing an immunodetectable hormone within tumour cells

Grading ET/carcinoid
(RCPath/WHO 2009)

Grading system for gastrointestinal endocrine tumours[18,19]

Grade	Mitotic count (10HPF)*	Ki-67 index (%)**
G1	<2	≤2
G2	2–20	>2–20
G3	>20	>20

* 10 HPF = 2 mm^2 based on each hpf being 0.2 mm^2 with at least 40 fields evaluated in areas at highest mitotic density.

** MIB1 antibody; % of tumour cells in a 2000 cell sample from the areas of highest nuclear labelling.

In practical terms, G1 and G2 endocrine tumours are generally well differentiated and display diffuse and intense expression of the two general immunohistochemical endocrine markers, chromogranin A and synaptophysin.[19] Presence of any punctate necrosis is suggestive of a more aggressive tumour, pointing to a G2 status, which, however, has to be confirmed by the mitotic count and Ki-67 staining. G3 indicates a poorly differentiated (neuro)endocrine carcinoma. It has high mitotic counts/Ki-67 index, is often associated with fields of necrosis, and shows significantly reduced chromogranin A expression, while maintaining intense staining for synaptophysin.

Grading ET/carcinoid

(RCPath/WHO 2009)

7.2.1 Establishing mitotic count and Ki-67 index

In the proposed grading system, where possible, mitoses should be counted on haematoxylin and eosin stained sections in at least 40 HPFs.[19] The mitoses should be assessed in areas where they are most frequent. For Ki-67 assessment, the MIB1 antibody is recommended at the conditions that have been established at the reporting laboratory. The Ki-67 index should be assessed in areas where the highest nuclear labelling is observed (often but not exclusively at the tumour periphery),[19] by counting an adequate sample of cells, such as the suggested sample size of 2000. The primary tumour should be assessed in preference to metastases, but metastases can be assessed if the primary tumour is not available or has been modified by local therapies.

The above table, whose categories have the accumulated evidence on their prognostic value, was based around 0.2 mm^2 high power fields. Pathologists should determine the diameter of their own microscope's high power field with the exact objective, eyepieces and other lenses tha they prefer to use, and calculate the area of that field, to enable adjustment to made to their counts. For example, if a microscope has a high power field of 0.22 mm^2, 10% larger than 0.2 mm^2, then the count will be 10% higher than if the field had been 0.2 mm^2 and needs to be multiplied by 100/110 to achieve the count that would have been made if the field had only been 0.2 mm^2 in area. In practice, x40 high power fields on a modern microscope with wide field optics can considerably exceed 0.2 mm^2 so it is necessary to check and to adjust.

The rationale for inclusion of the actual Ki-67 index in the proformas is that different studies have proposed stratification based upon different cut-off values. Provision of the actual index allows for future introduction of different cut points and for research.

The Ki-67 index may be noted for metastases if locally desired, but there are no specific data to indicate analysis of other than the primary tumour where it is available.

Grading ET/carcinoid
(RCPath/WHO 2009)

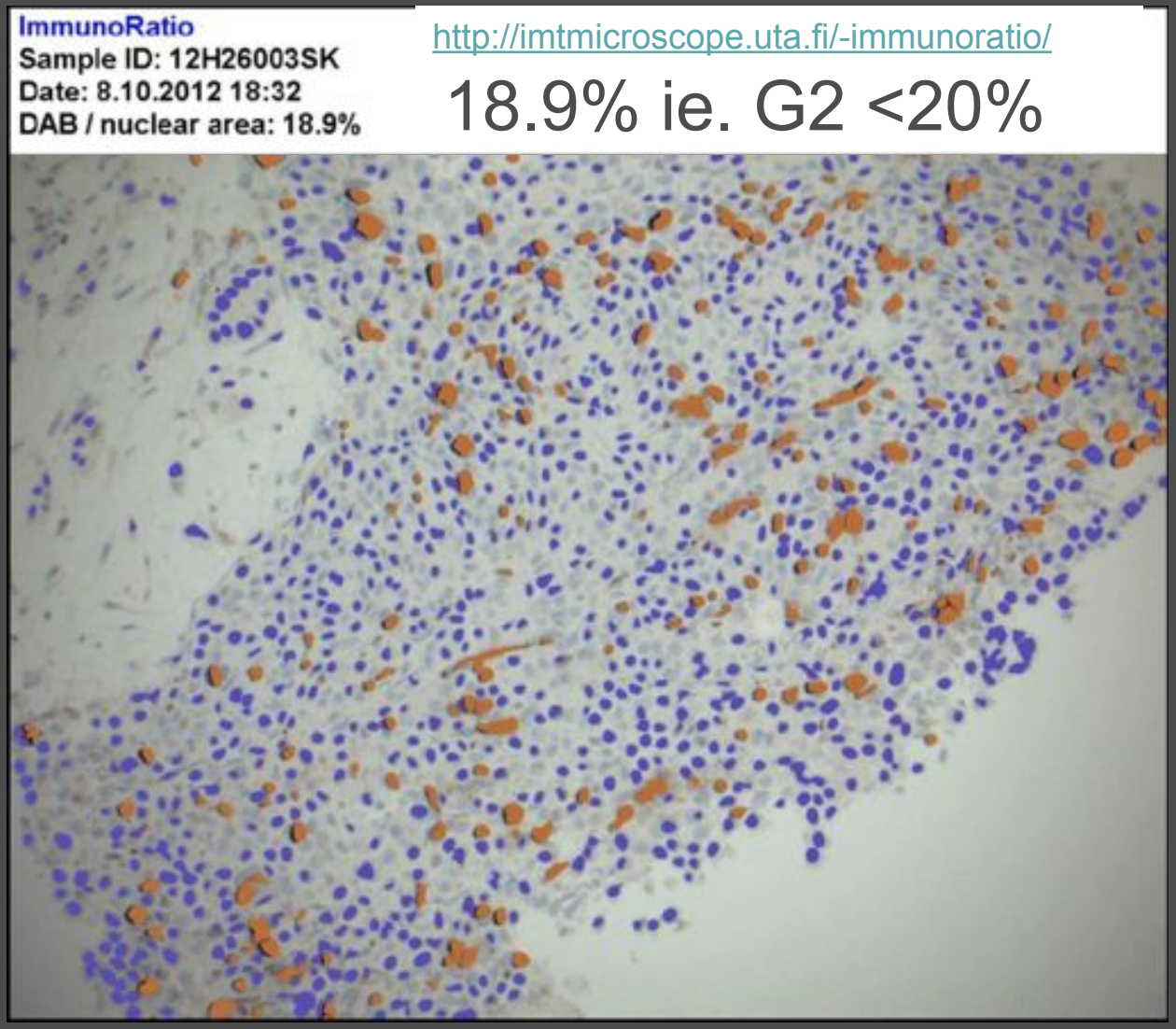

http://imtmicroscope.uta.fi/-immunoratio/

18.9% ie. G2 <20%

Gastric Endocrine hyperplasia

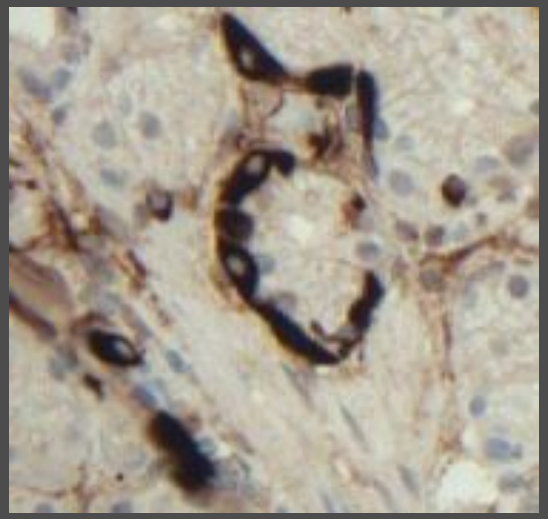

Linear – “daisy chain” >5/gland

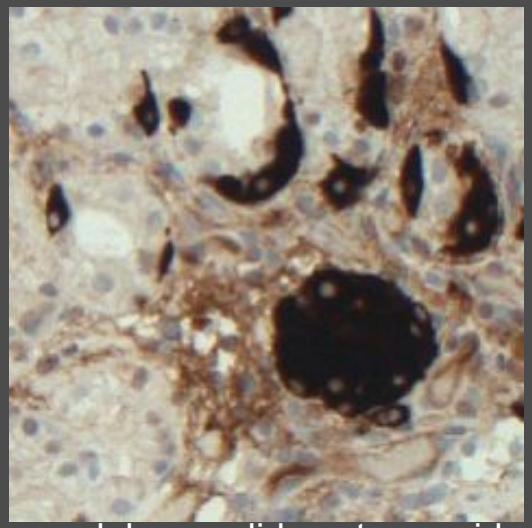

Micronodular – solid nests no wider than neighbouring glands (100-150um)

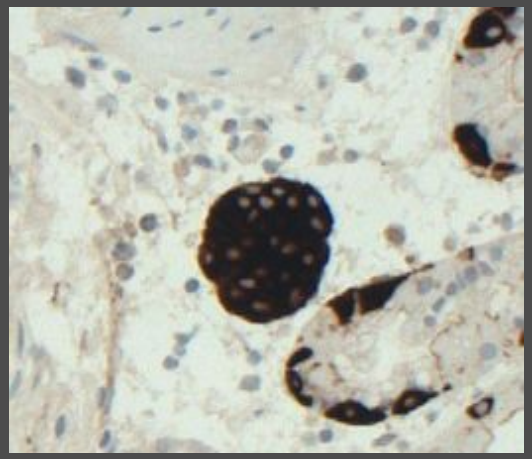

Adenomatoid – ***inter****glandular nodules >5 cells with intact basement membrane*

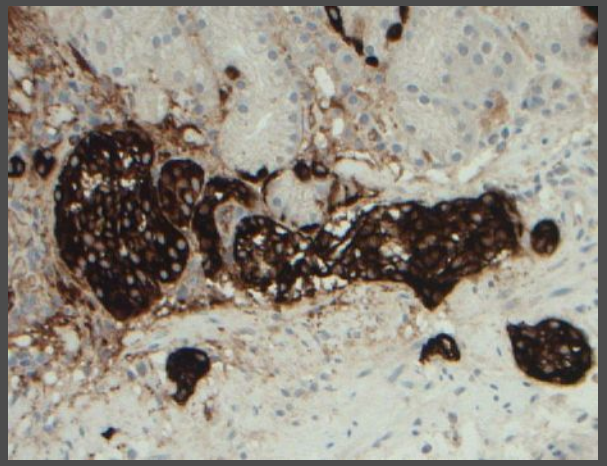

Dysplasia – enlarged/fused nodules less than 0.5mm (larger = tumour)

Case study 6

- 89 year old female, friable ulceration in fundus/hiatus hernia ?gastric/oesophageal cancer

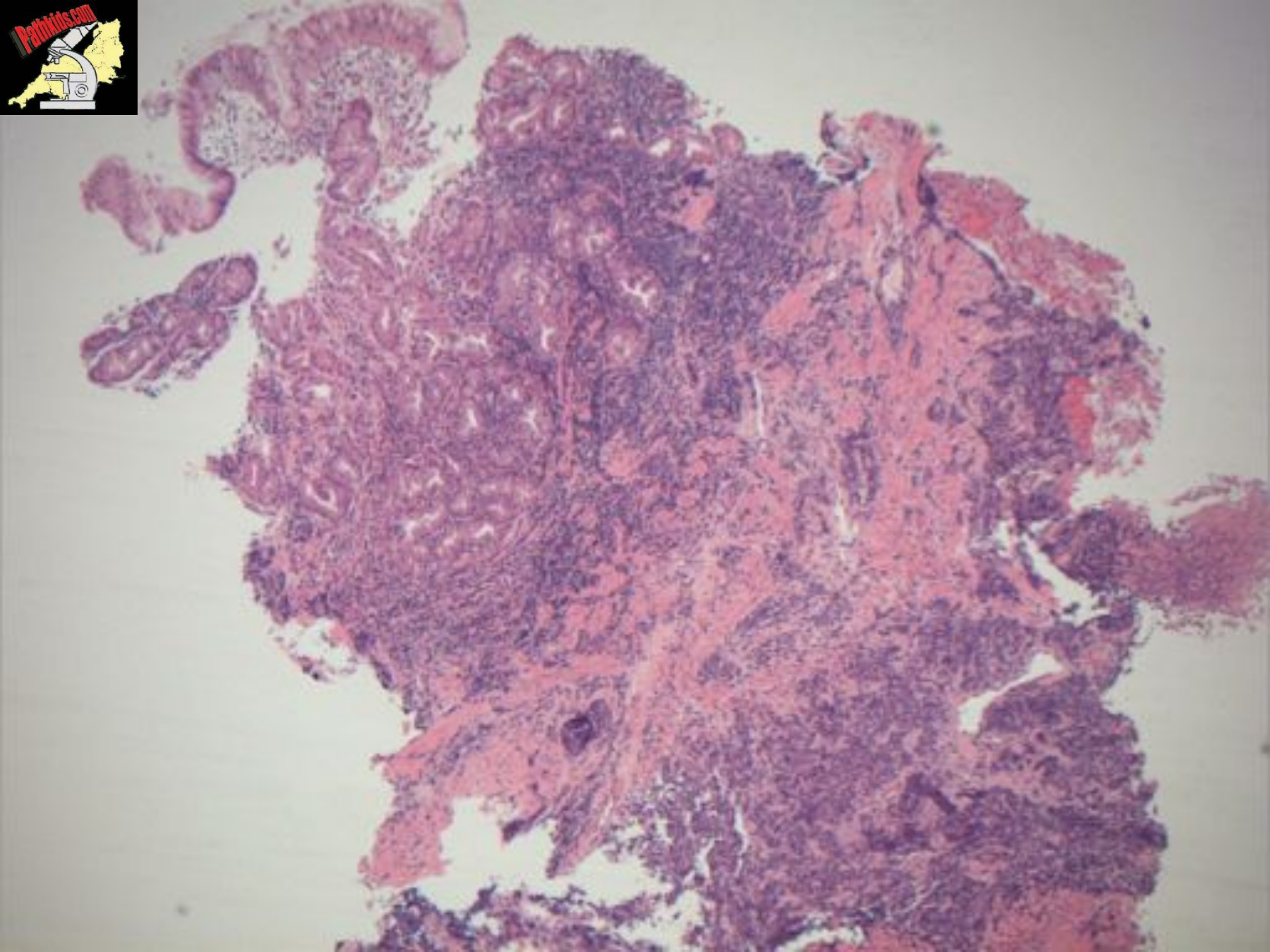
PathKids.com

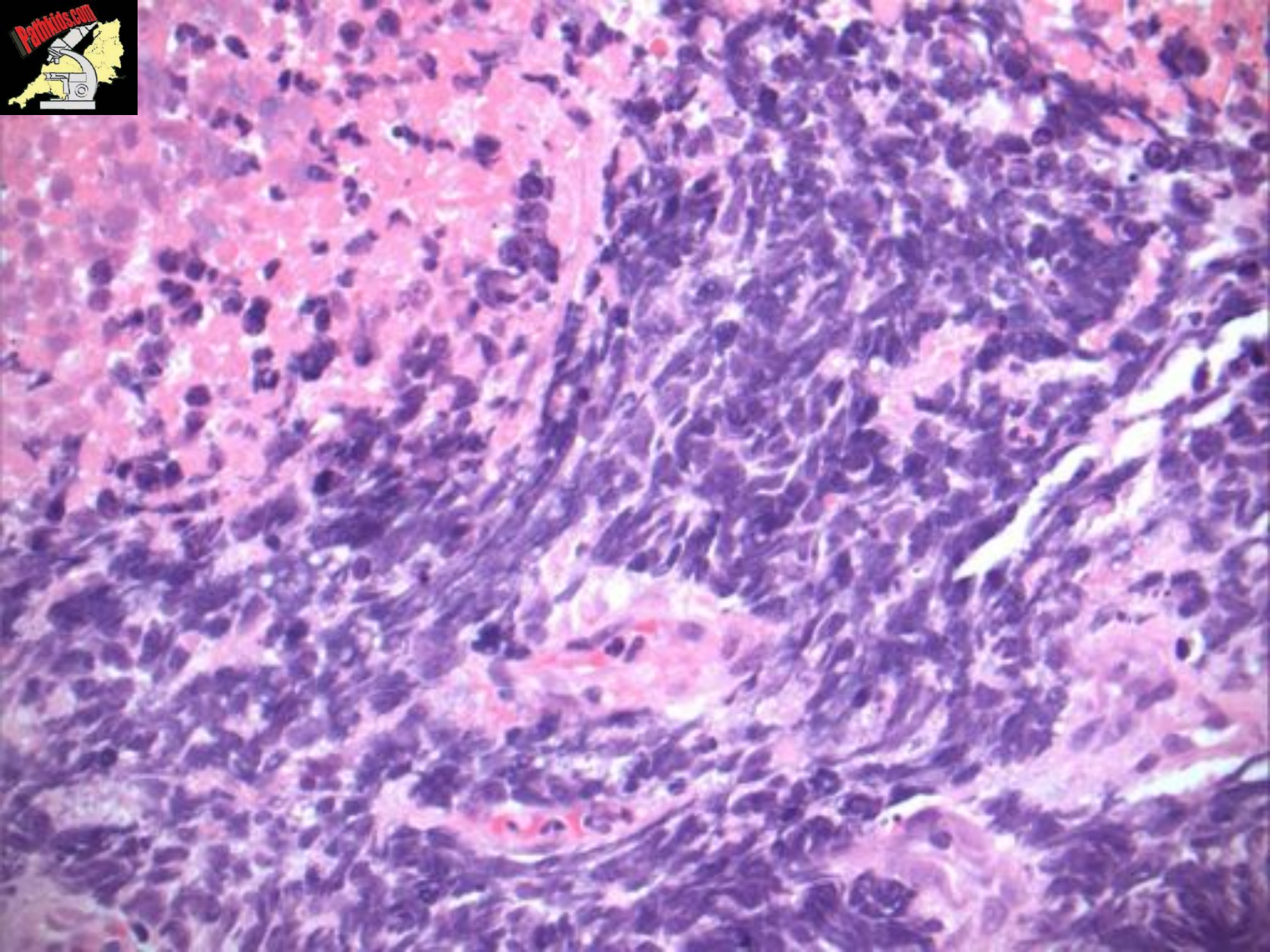
PathKids.com

What immuno is this?
CD20

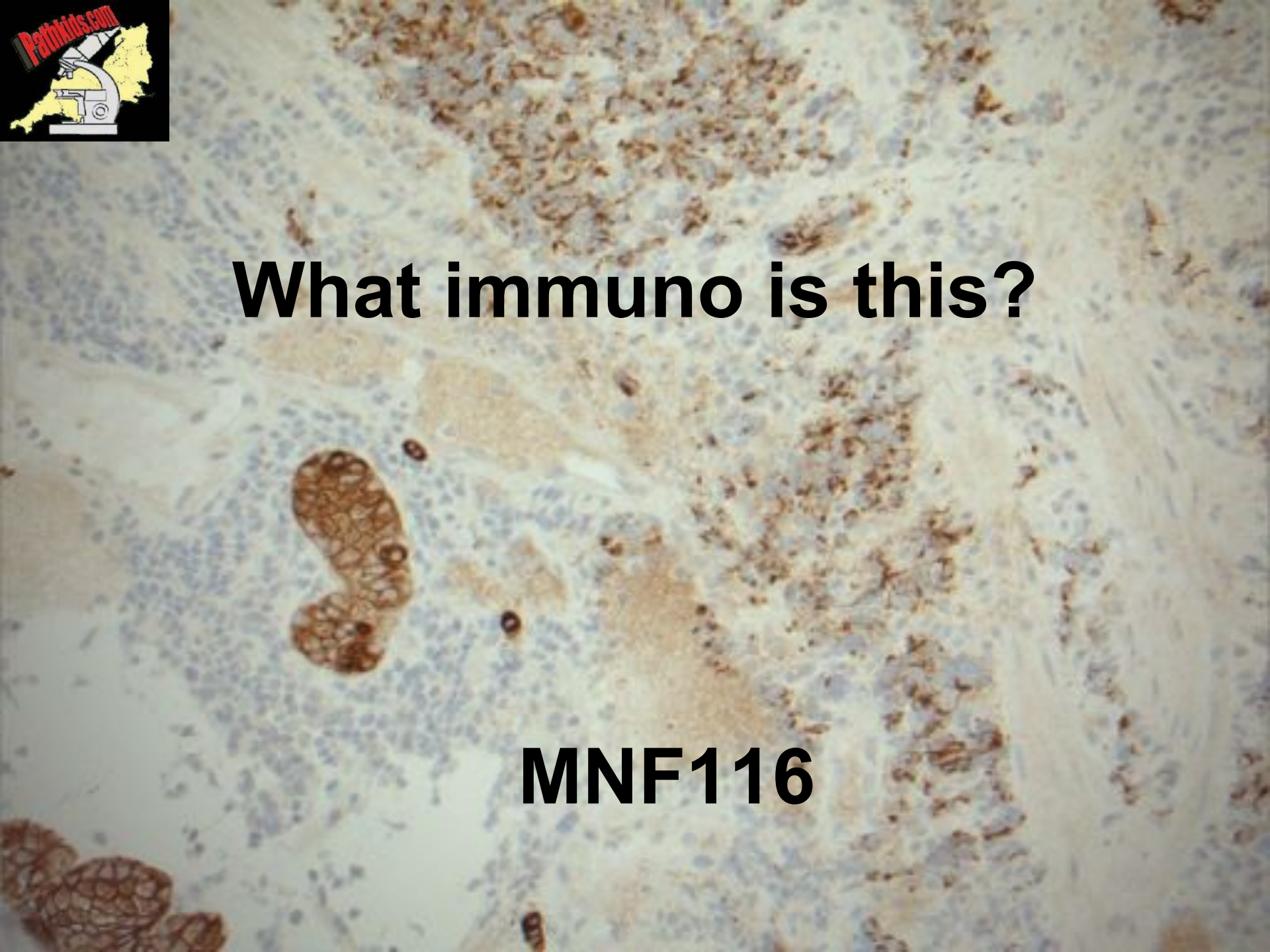
What immuno is this?
MNF116

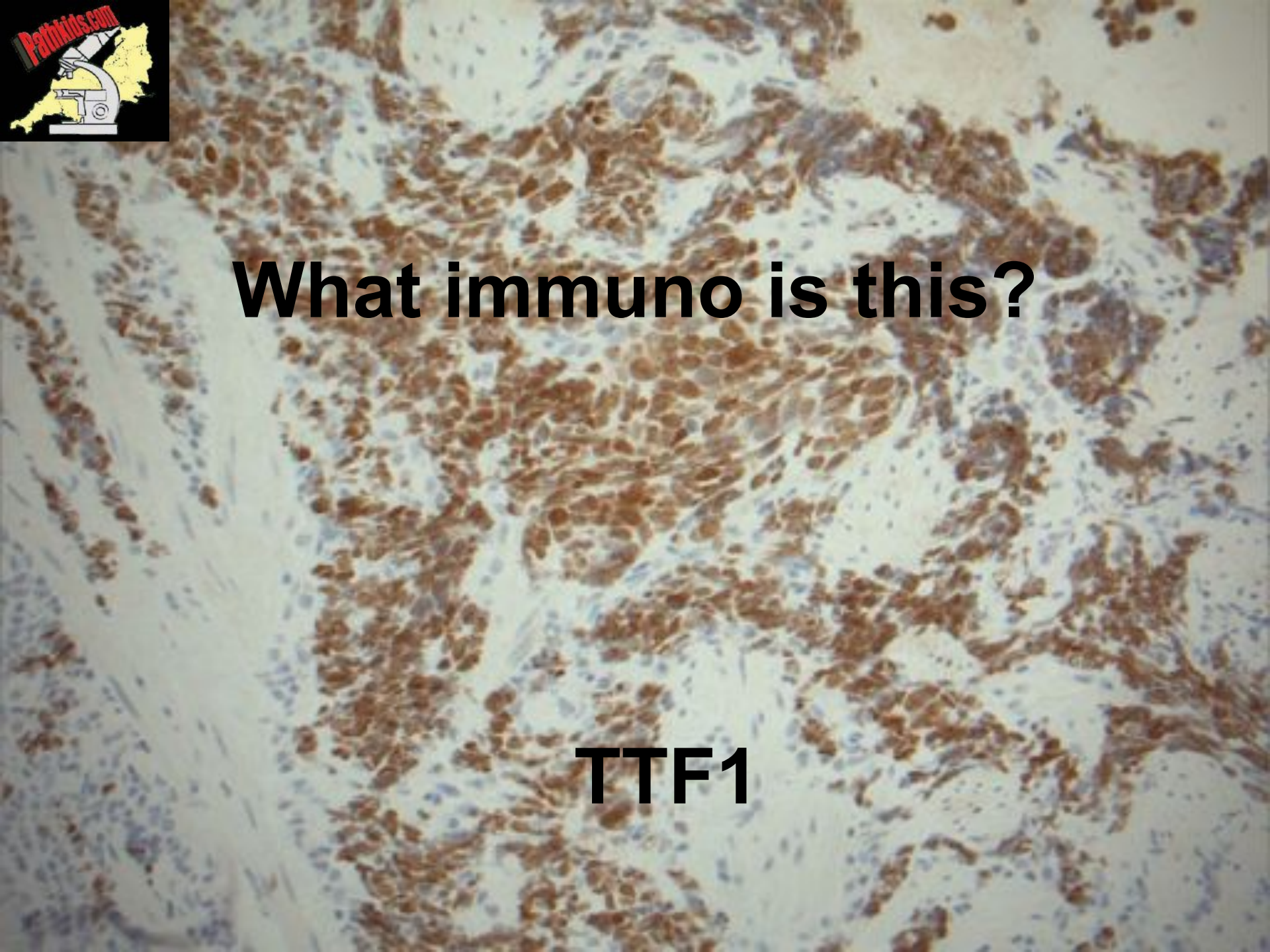
What immuno is this?
TTF1

What immuno is this?
Chromogranin

Case study 6

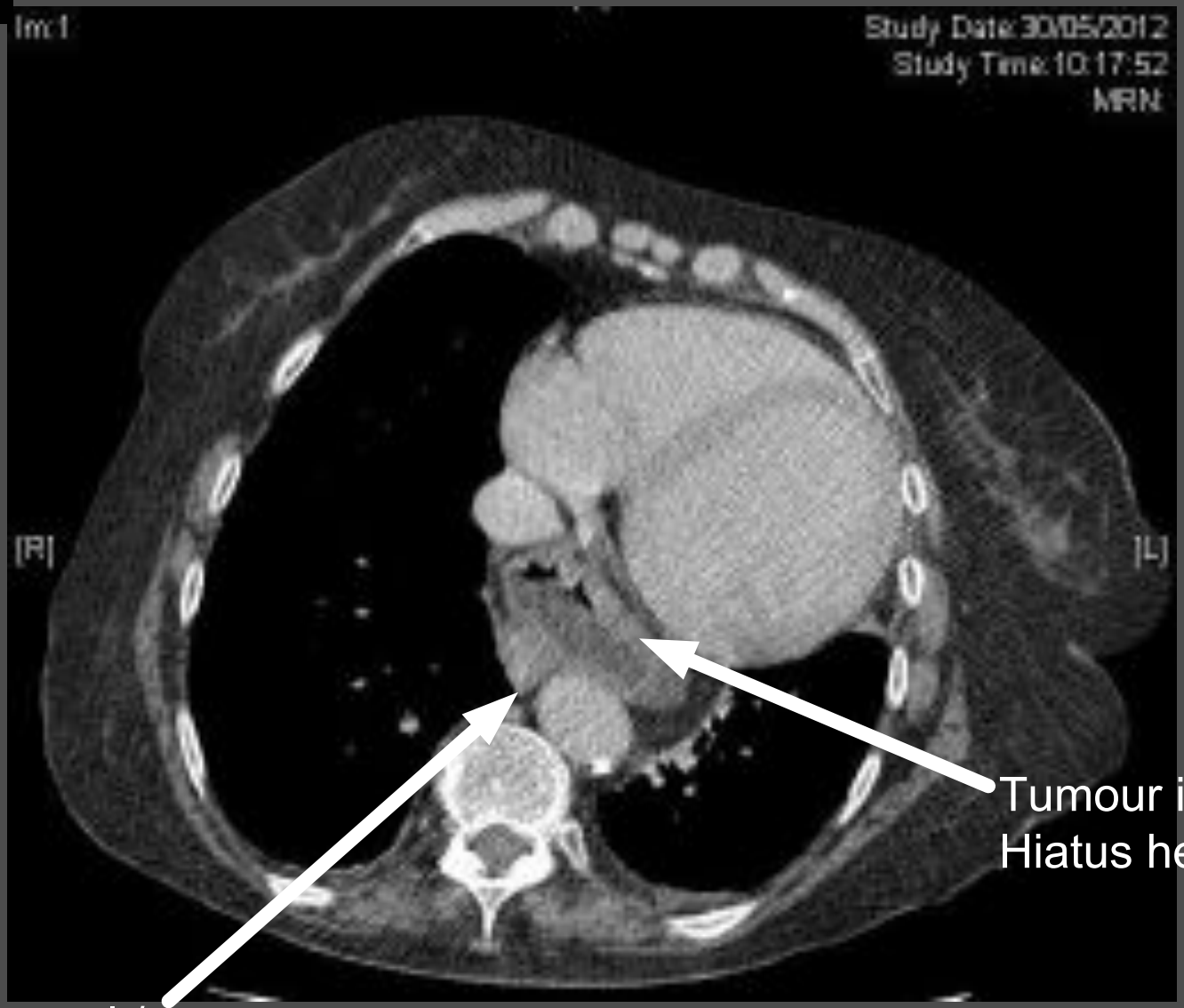

Tumour in wall of Hiatus hernia

Extramural / mediastinal tumour

Case study 6

- 89 year old female, friable ulceration in fundus/hiatus hernia ?gastric/oesophageal cancer
- Diagnosis – oesophagogastric small cell carcinoma (high grade neuroendocrine carcinoma)
- TTF1 positivity does not mean bronchopulmonary/mediastinal primary
- ~70% oesophageal SmCC TTF1 positive

Case study 7

- 60 year old male
- GOJ tumour
- Biopsy originally reported as poorly differentiated adenocarcinoma
- On review foci resembling carcinoid tumour
- ….but preoperative staging T3 N1

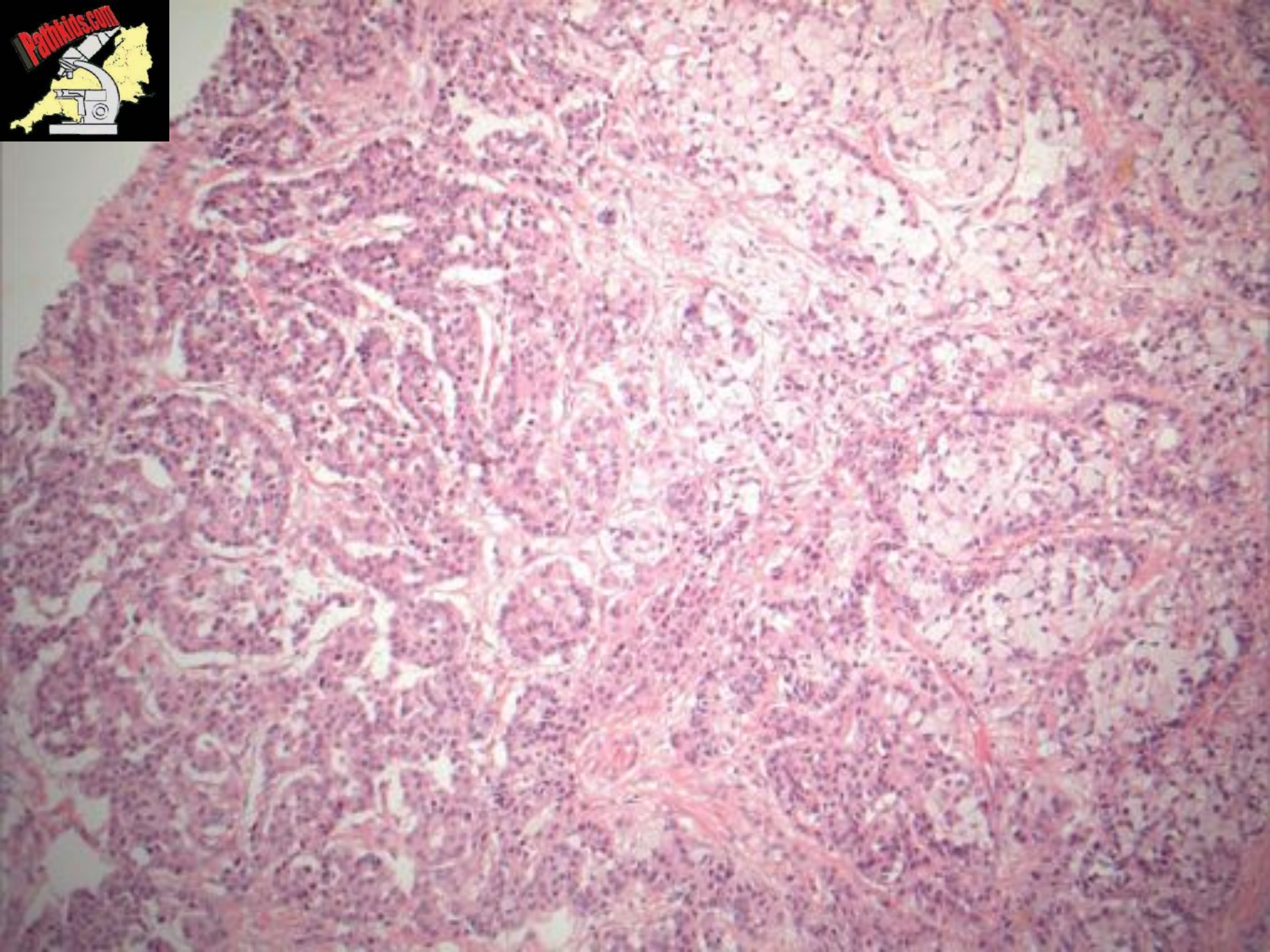
PathKids.com

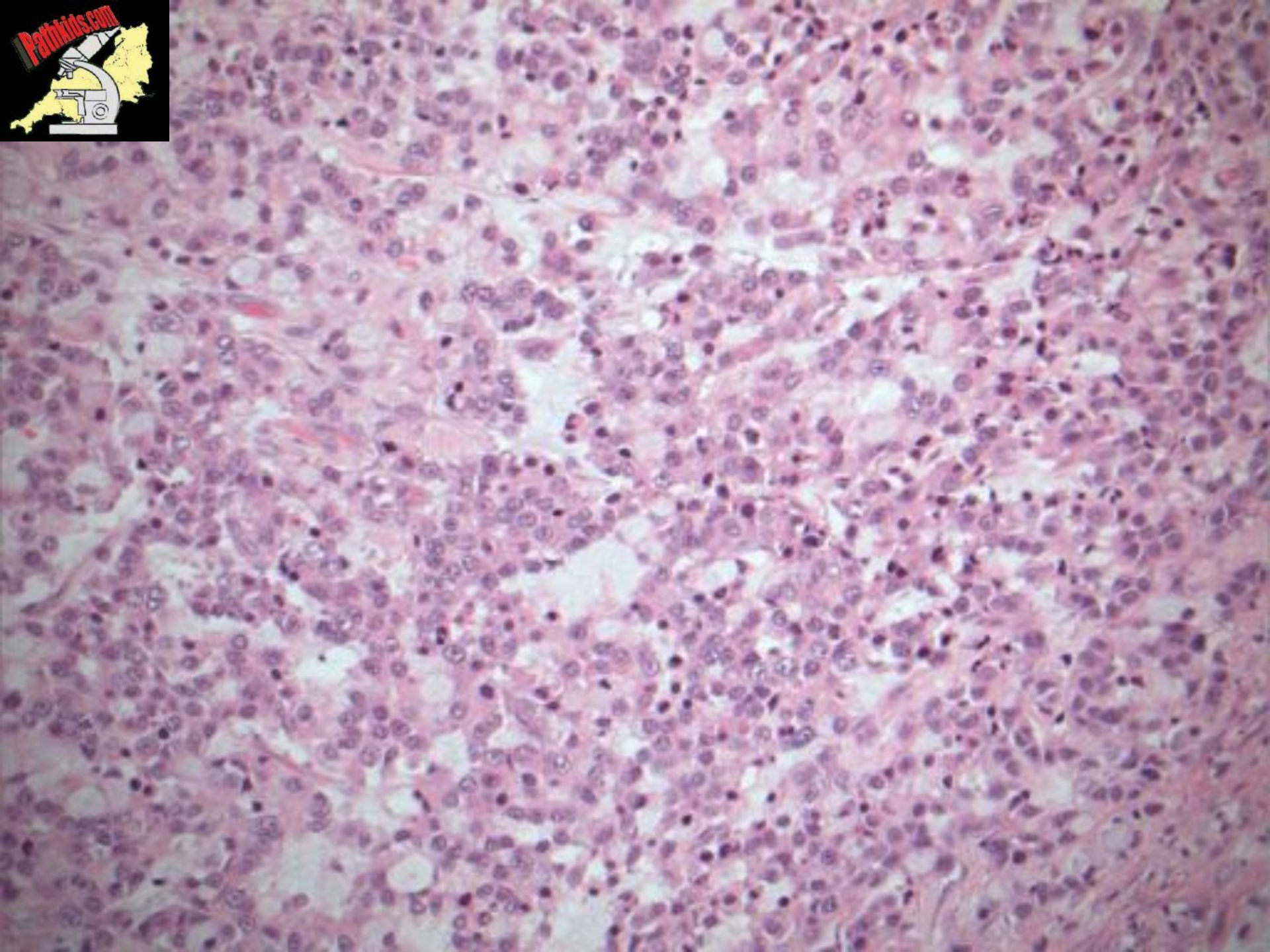
PathKids.com

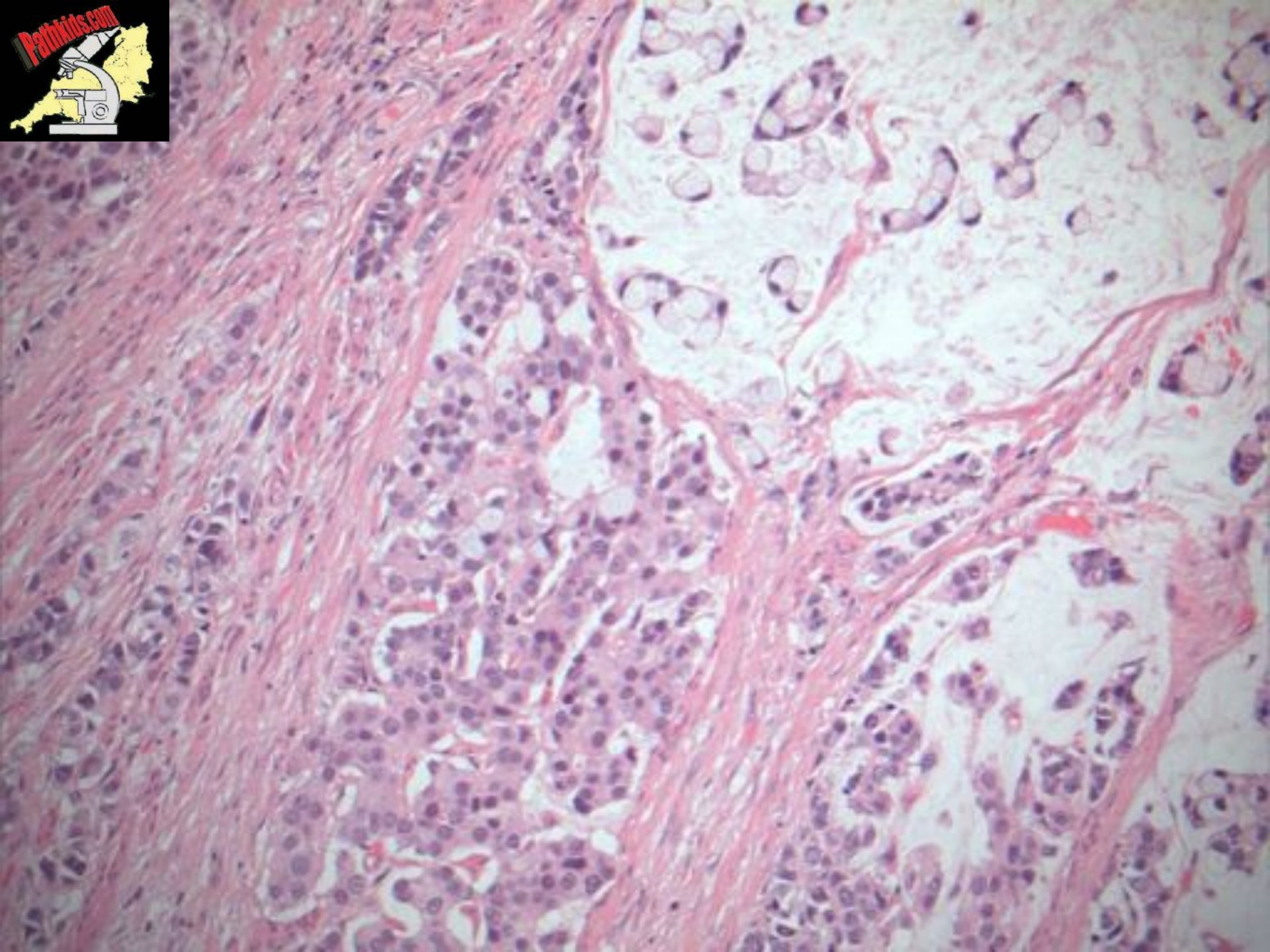
PathKids.com

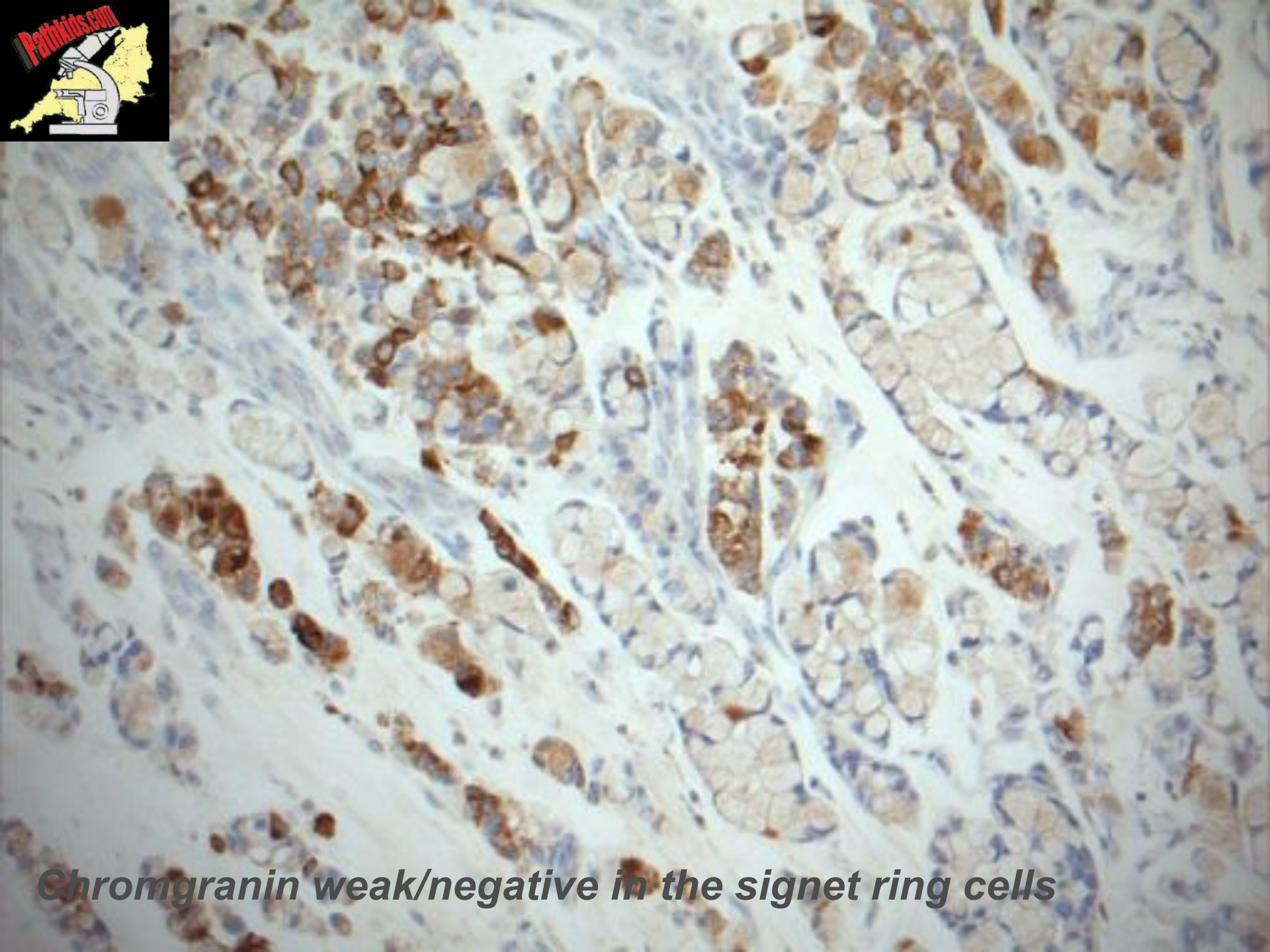

Chromgranin weak/negative in the signet ring cells

Cancers **2012**, *4*, 11-30; doi:10.3390/cancers4010011

OPEN ACCESS

cancers

ISSN 2072-6694

www.mdpi.com/journal/cancers

Review

Mixed Adenoneuroendocrine Carcinomas (MANECs) of the Gastrointestinal Tract: An Update

Stefano La Rosa [1,*], Alessandro Marando [2], Fausto Sessa [2] and Carlo Capella [2]

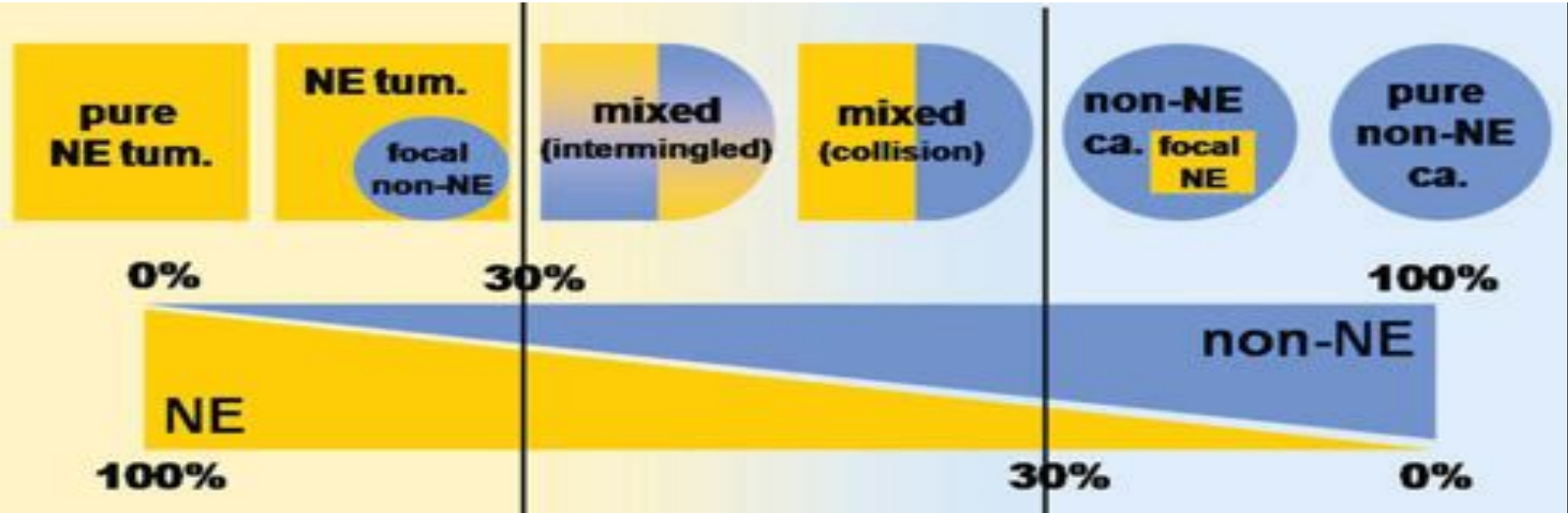

MANECs

- Must be at least 30% of each component
- Morphological and immunohistochemical evidence of NE differentiation
- Does not apply to carcinomas with focal chromogranin/synaptophysin immunoreactivity
- Grade both components (in the above case both adenocarcinoma and NET were high grade). Pt now has liver mets

Case study 8

- 83 year old male
- GOJ Siewert 1 tumour
- Biopsy originally reported as moderately differentiated adenocarcinoma
- On review foci resembling NET in addition to intestinal adenocarcinoma
- …. preoperative staging T3 N0
- Both these patients had PET and octreotide scans to exclude distant mets before neoadjuvant and surgical treatment

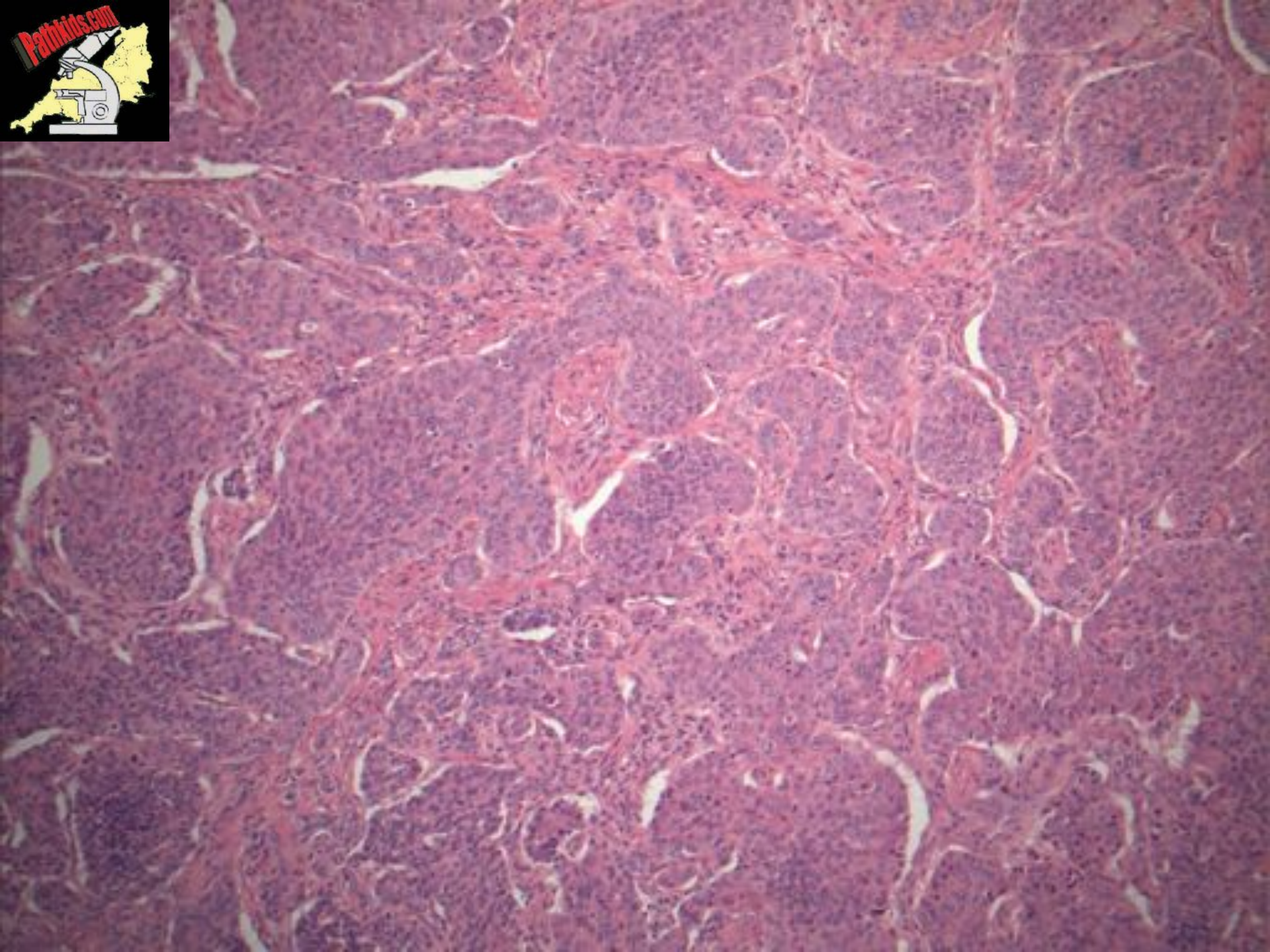
PathKids.com

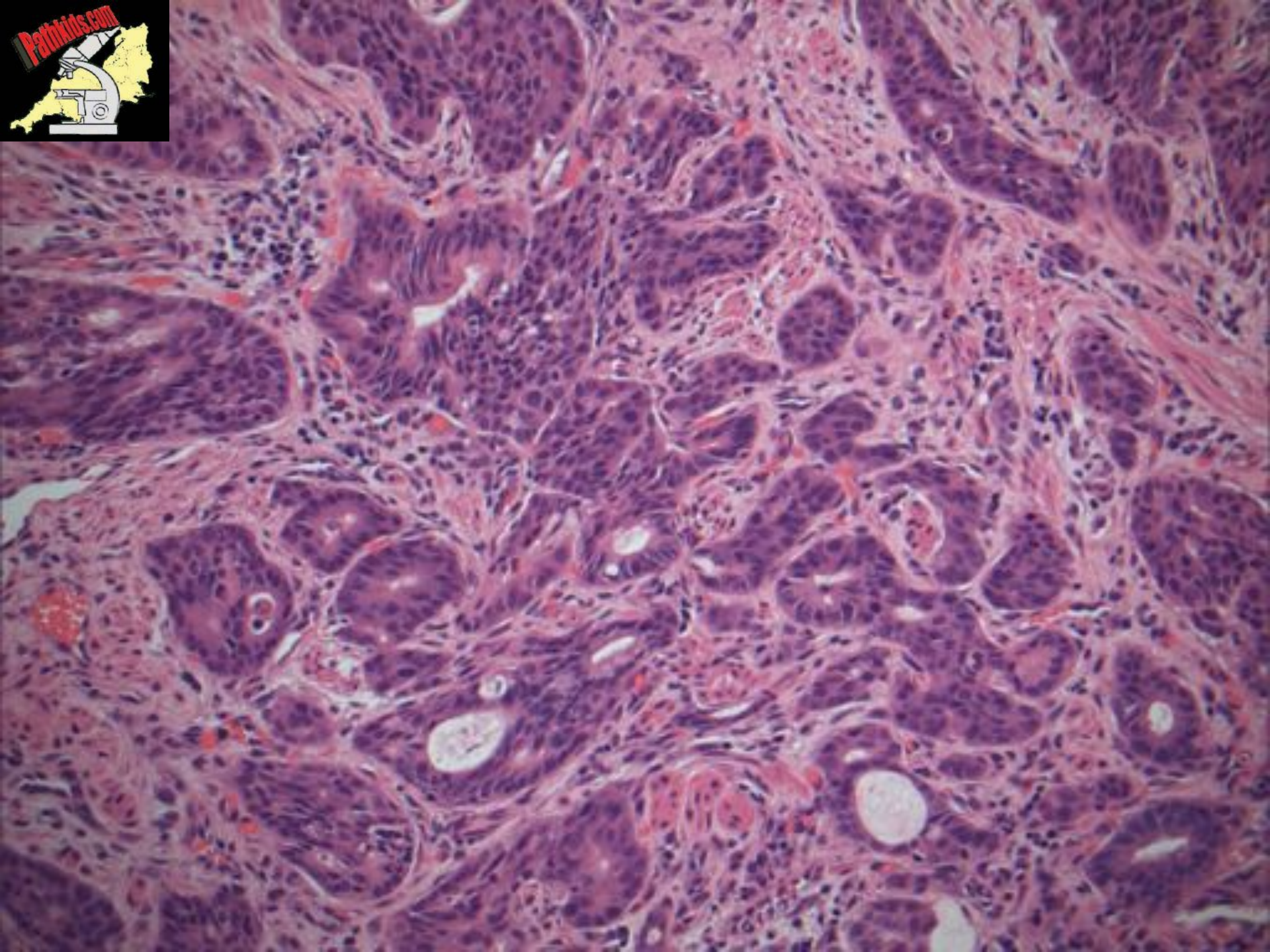
PathKids.com

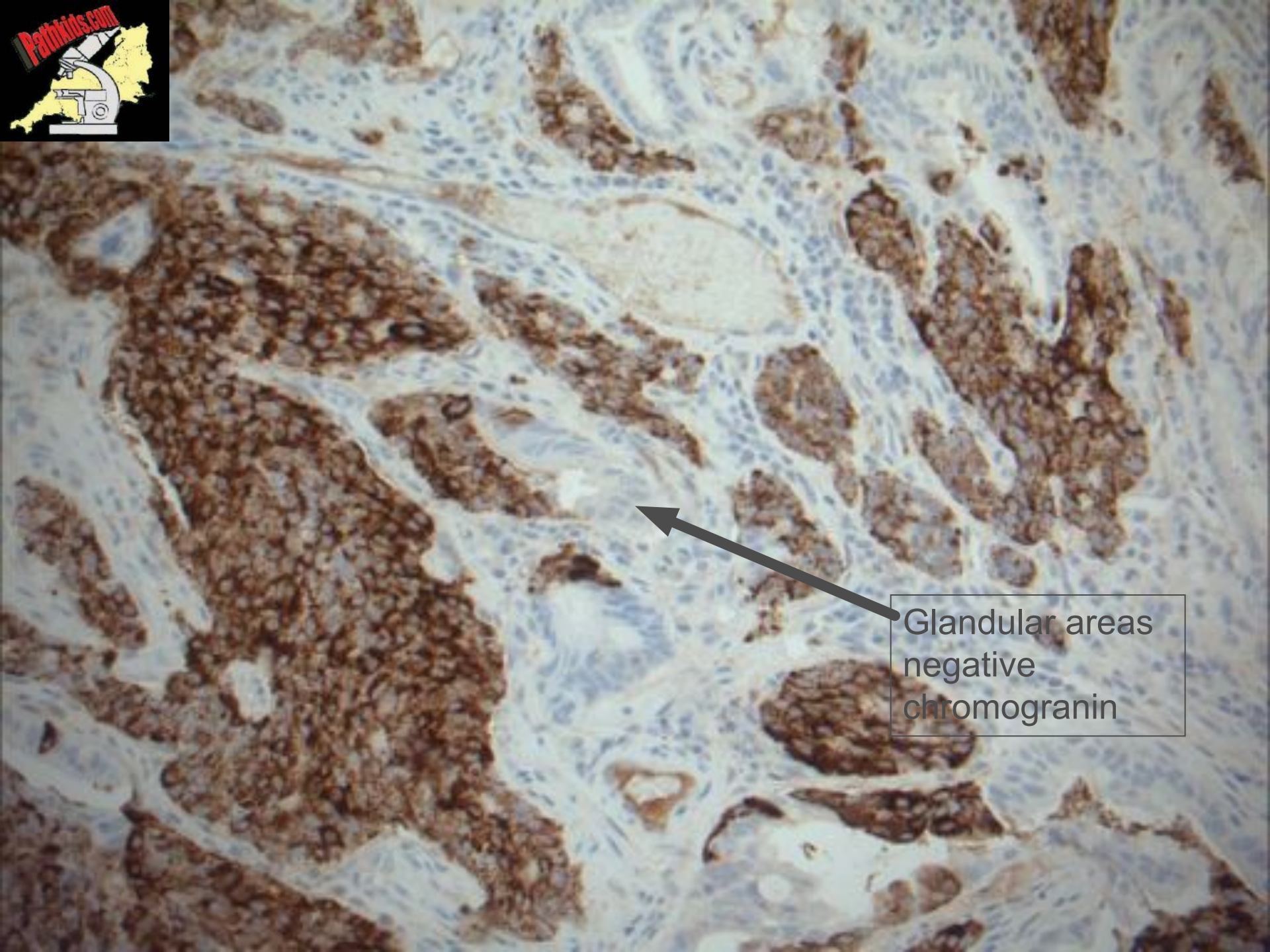
Glandular areas
negative
chromogranin

Case study 8

- MANEC comprising moderately differentiated adenocarcinoma (intestinal) and G2 endocrine carcinoma
- No response to neoadjuvant but all nodes clear; T3 N0 (0/27) R1 (0.5mm circumferential) TRG5 (no response)

Regression grading (Mandard)

- Grading is subjective
- Trials have shown survival benefit with TRG1 and TRG2 (~60% 3years with no difference between 1&2)
  - Although this clearly depends on the diligence of the reporting pathologist to separate these grades

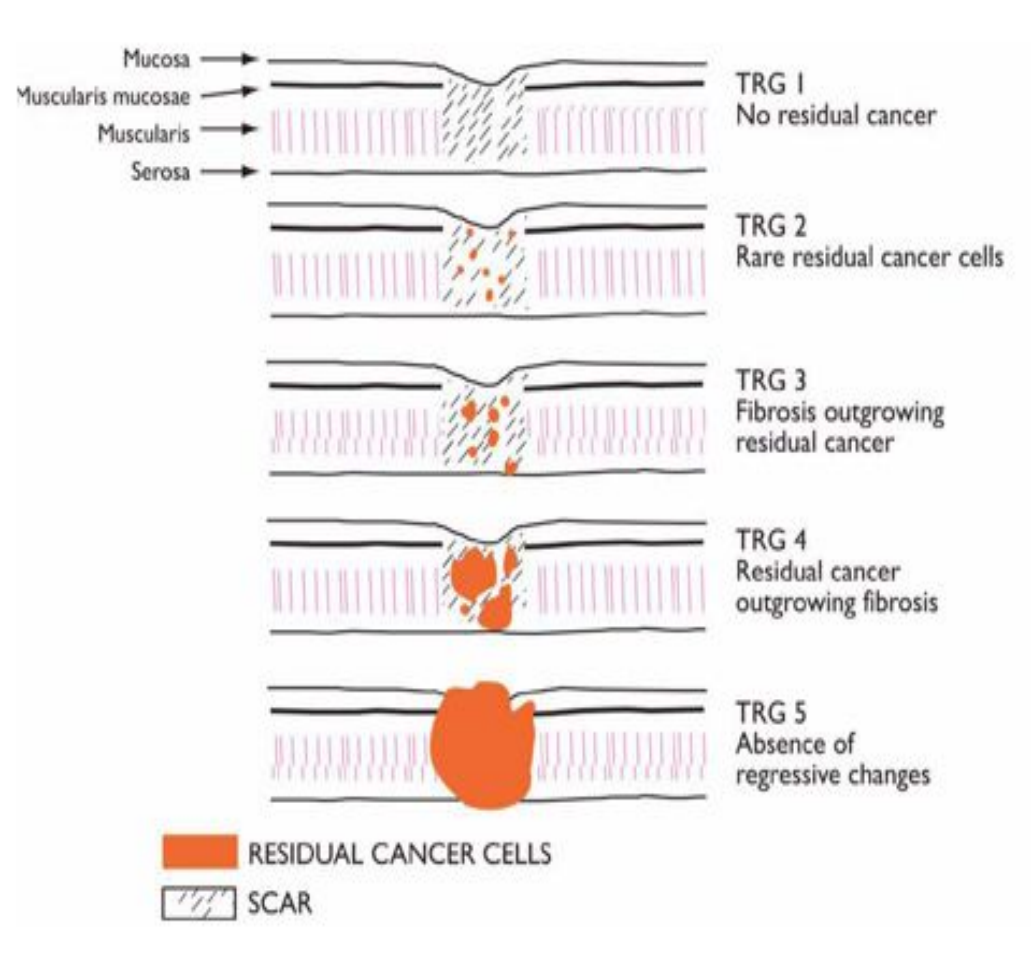

A recent TRG2 (originally TRG1 but tumour cells found in 1 block

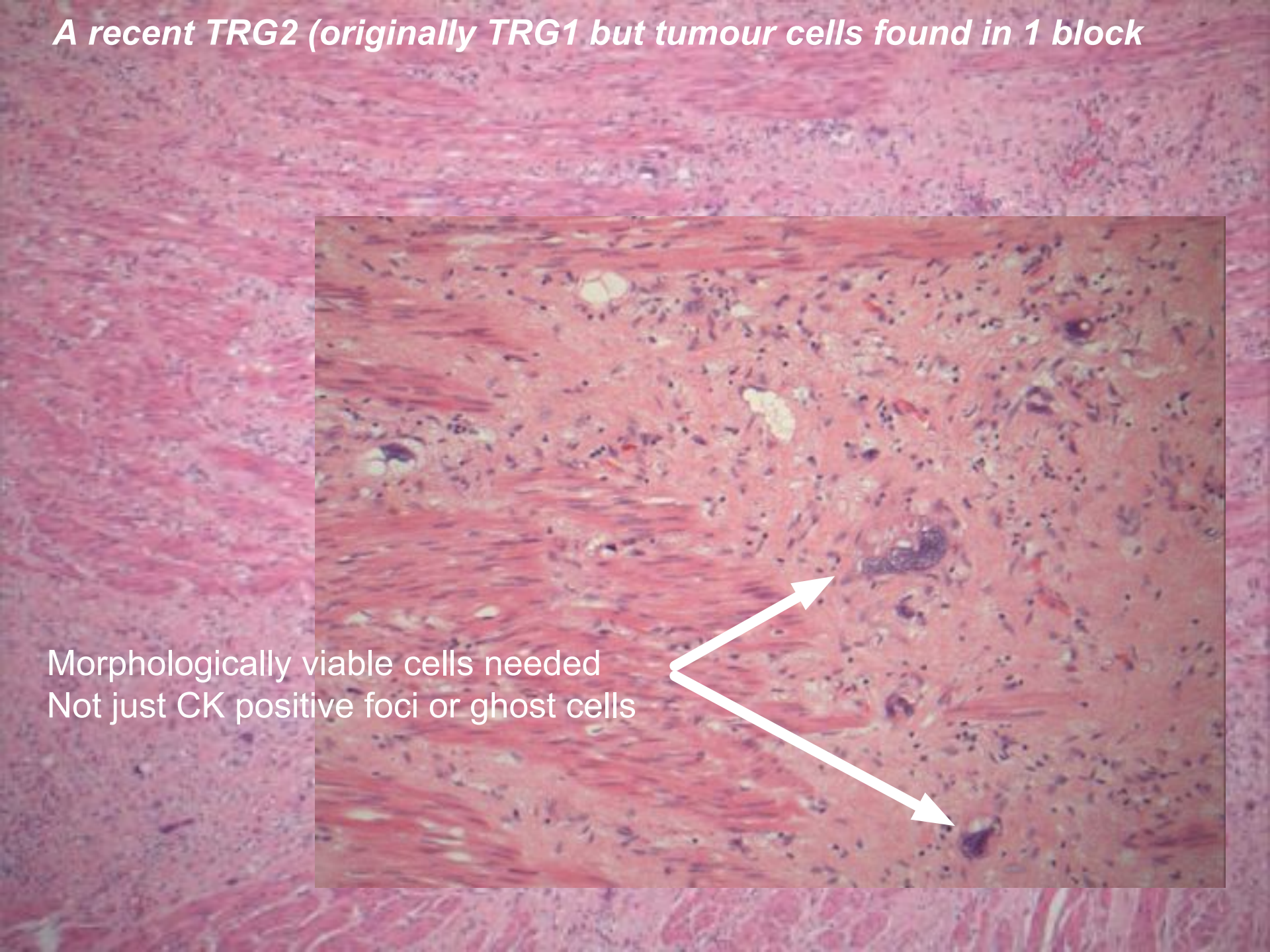

SUMMARY

- Oesophagus and stomach
- benign and malignant conditions
- Cutup and reporting of radical cancer resections and local (EMR) excisions
- Endocrine tumour spectrum, terminology grading and reporting

Esophagus – 7th Edition

Tis Carcinoma in situ /High-grade dysplasia
T1 Lamina propria or submucosa
- T1a Lamina propria or muscularis mucosae
- T1b Submucosa

T2 Muscularis propria
T3 Adventitia
T4 Adjacent structures
- T4a Pleura, pericardium, diaphragm, or adjacent peritoneum
- T4b Other adjacent structures, e.g. aorta, vertebral body, trachea

Changes from 6th Ed.

Esophagus – 7th Edition

N0 No regional lymph node metastasis
N1 1 to 2 regional lymph nodes
N2 3 to 6
N3 > 6

Changes from 6th Ed.

[N1 was site dependent]

M0 No distant Metastasis
M1 Distant metastasis
[M1a,b were site dependent]

Anatomical/Prognostic Stage Groups
based on histologic type, grade, location within esophagus and T, N, M

Stomach – 7th Edition

T1 Lamina propria, submucosa
- T1a Lamina propria
- T1b Submucosa

T2 Muscularis propria
T3 Subserosa (was T2b)
T4a Perforates serosa (was T3)
T4b Adjacent structures

Changes from 6th Ed.

N1 1 to 2 nodes
N2 3 to 6 nodes (was N1)
N3a 7 - 15 nodes (was N2)
N3b 16 or more (was N3)

Stage Groupings revised