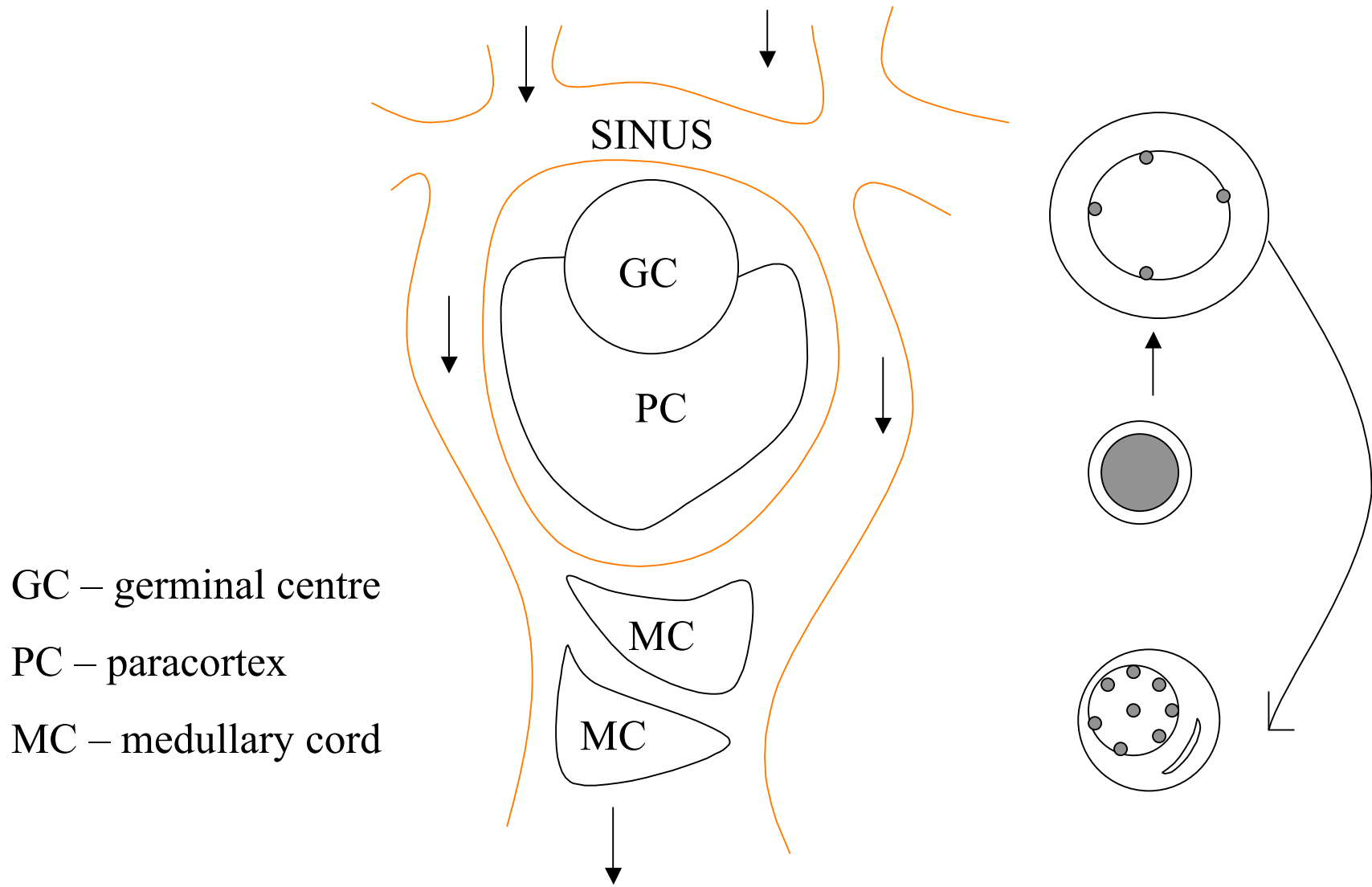
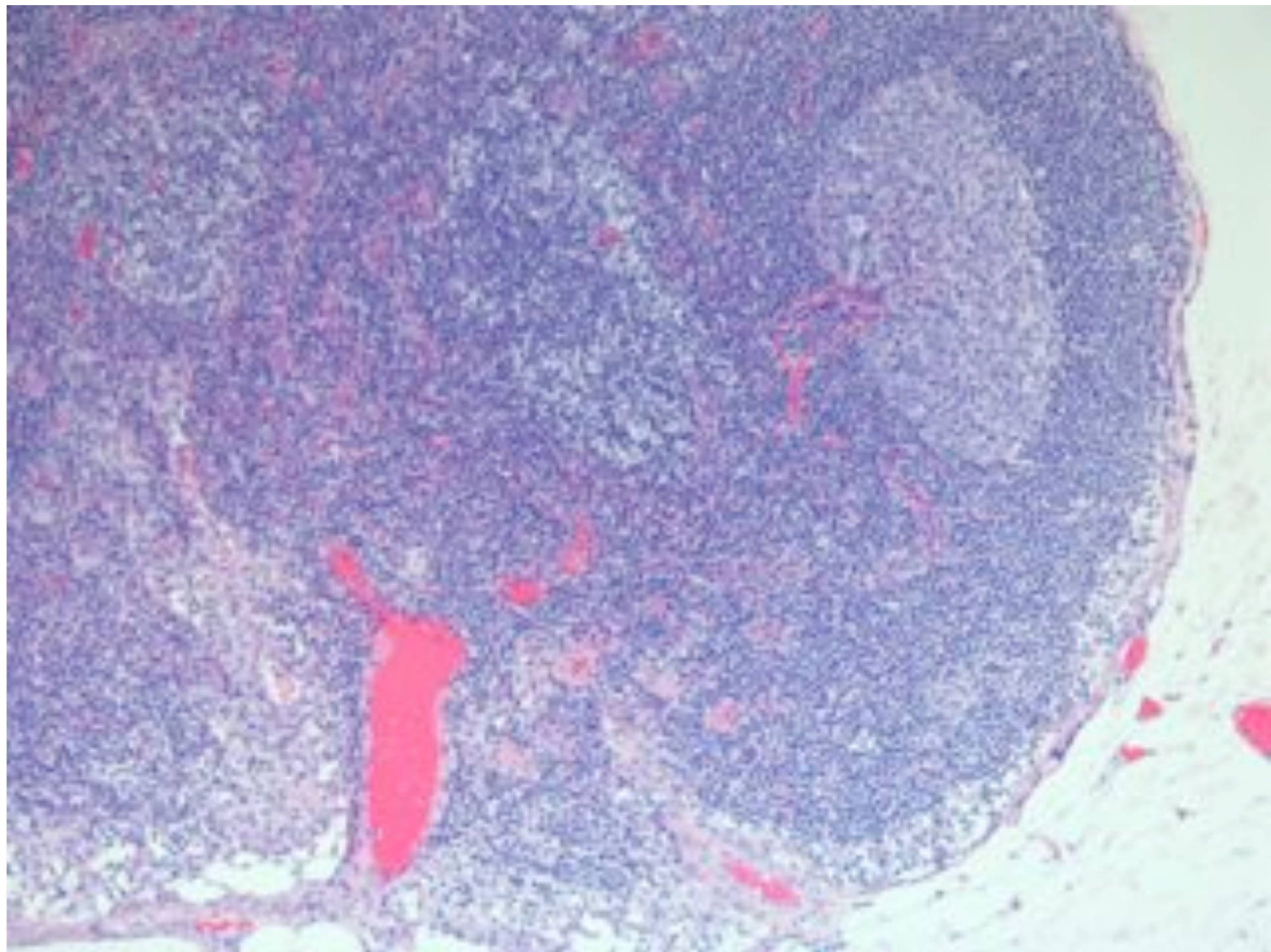
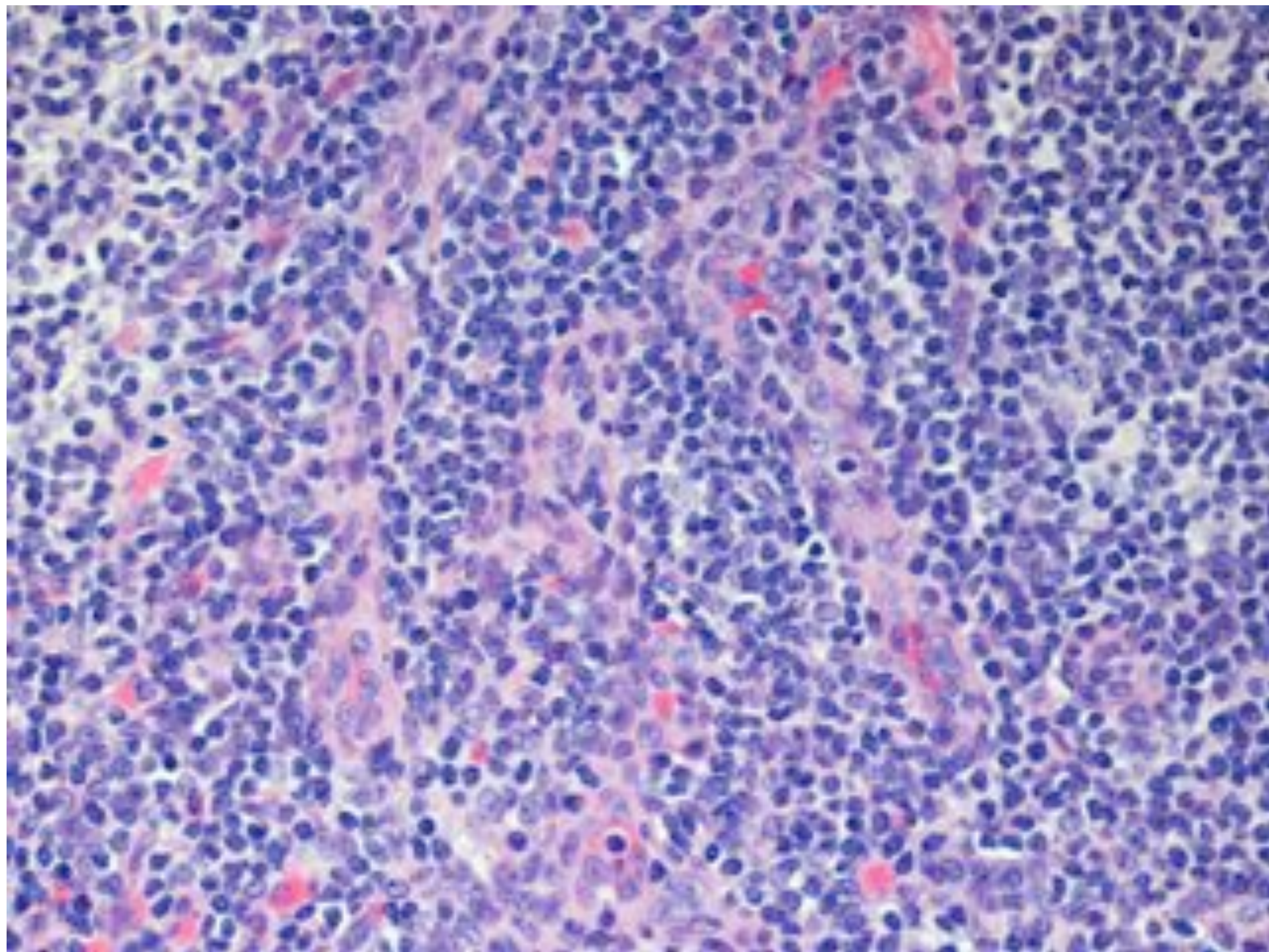


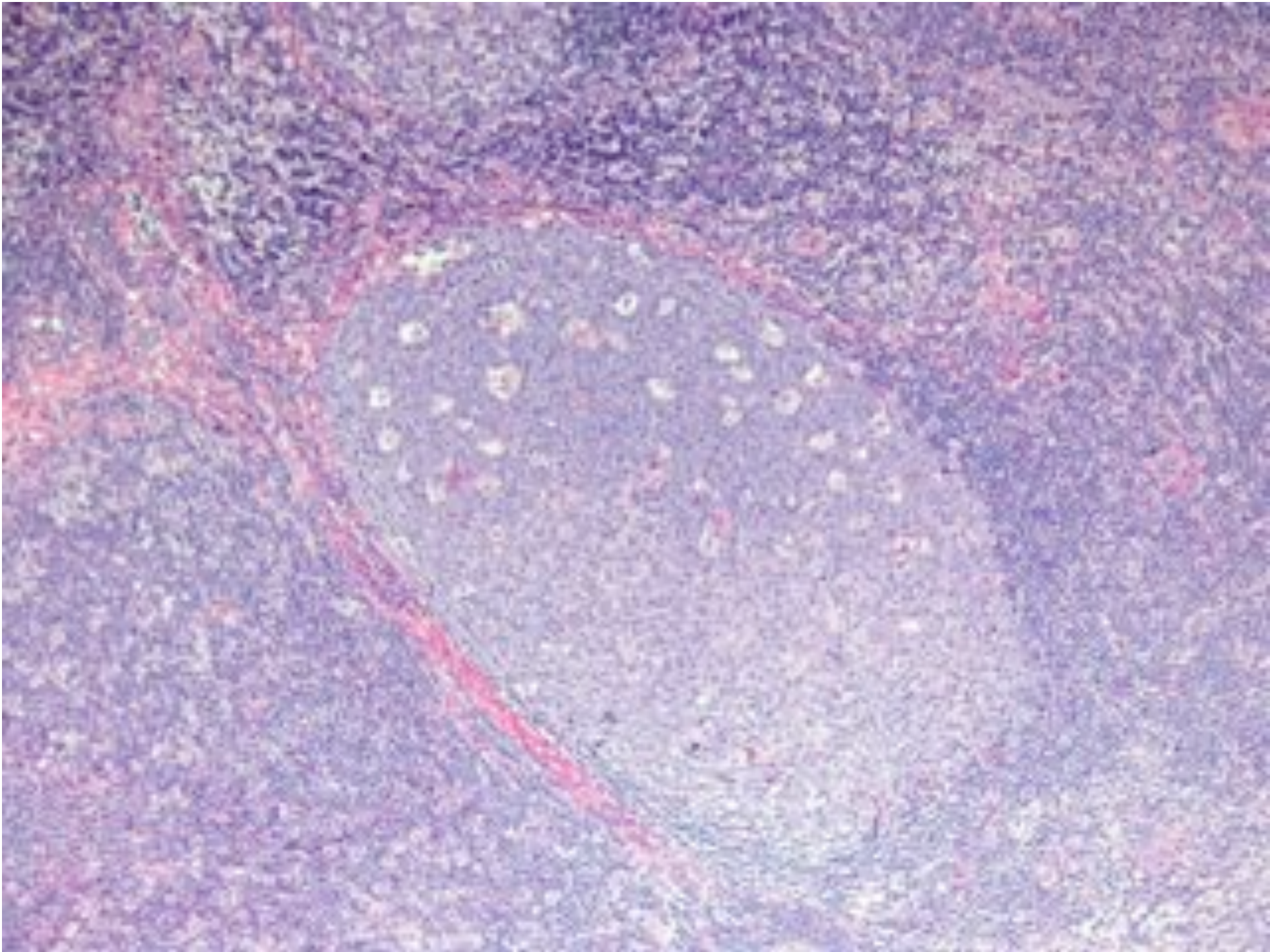
HOW TO DIAGNOSE B-CELL NHL

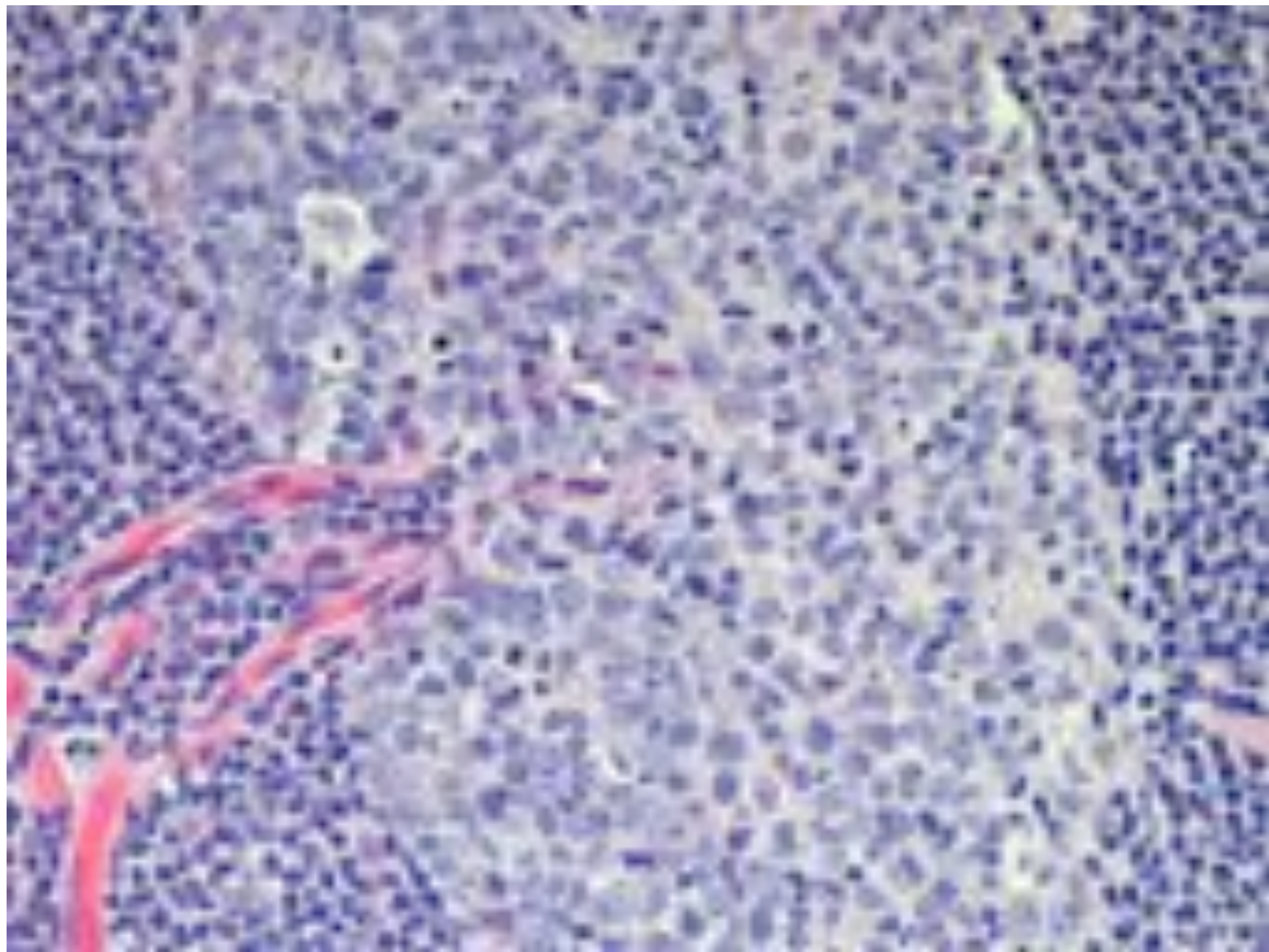
Lymph node compartments



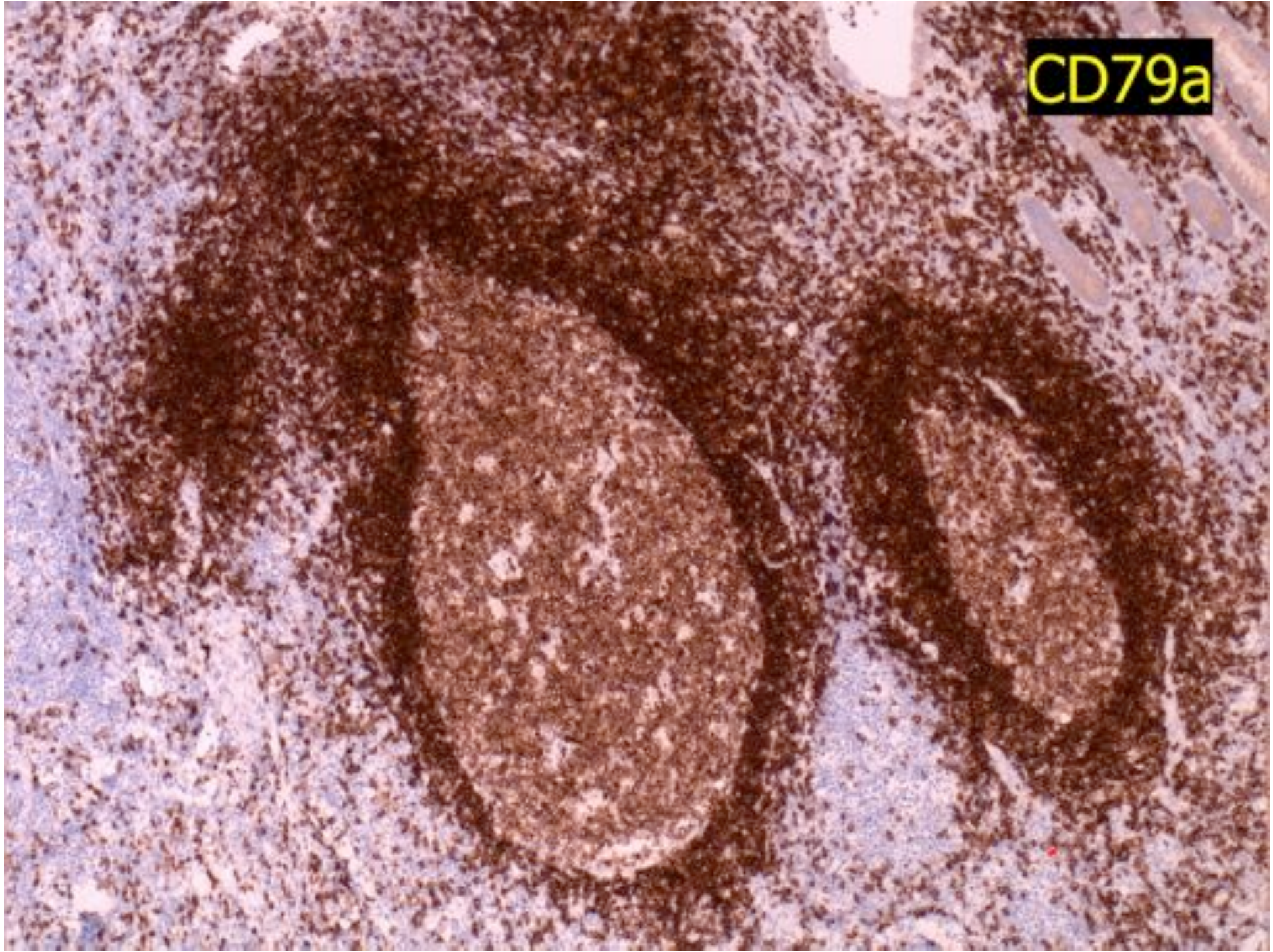



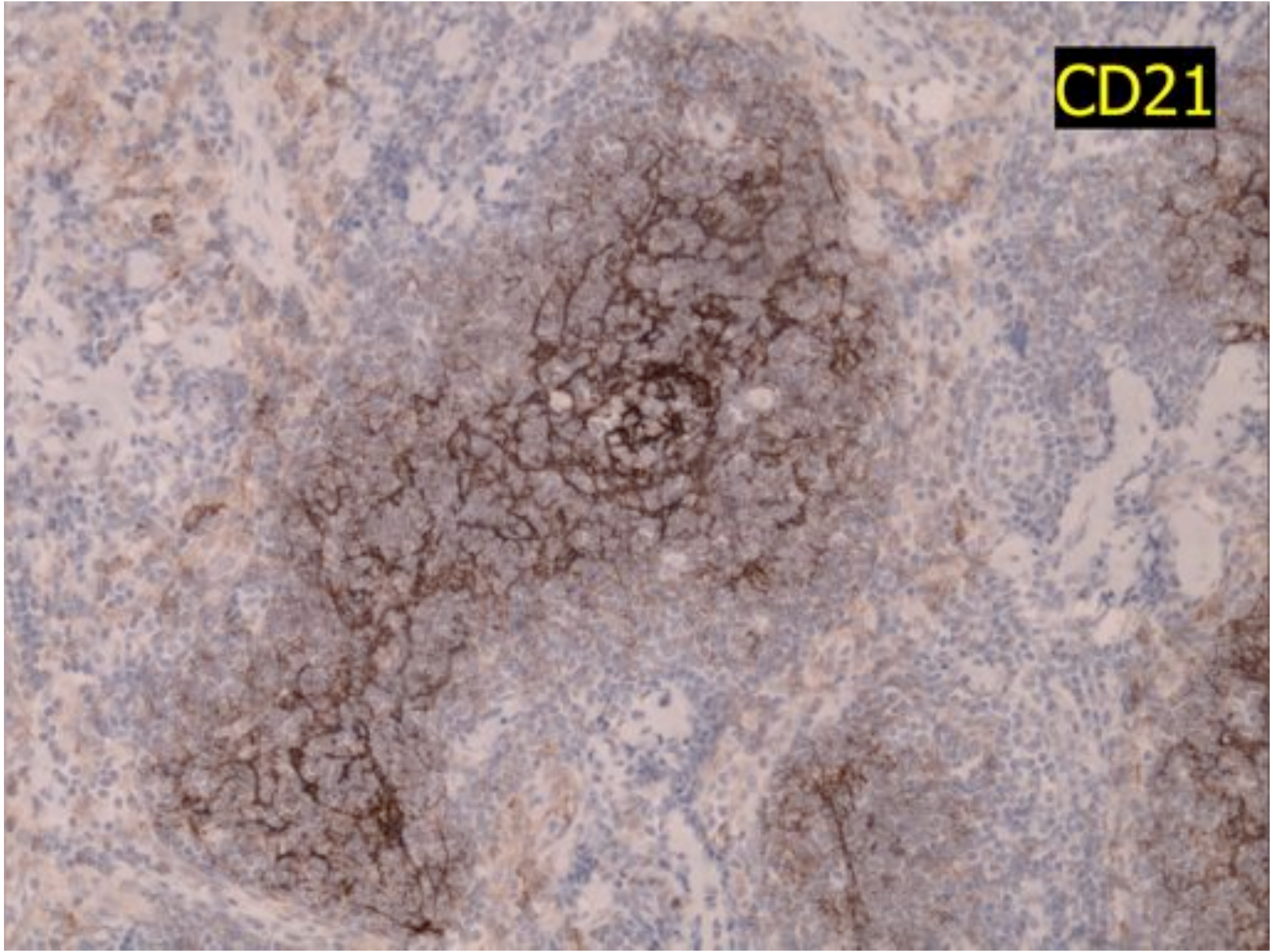




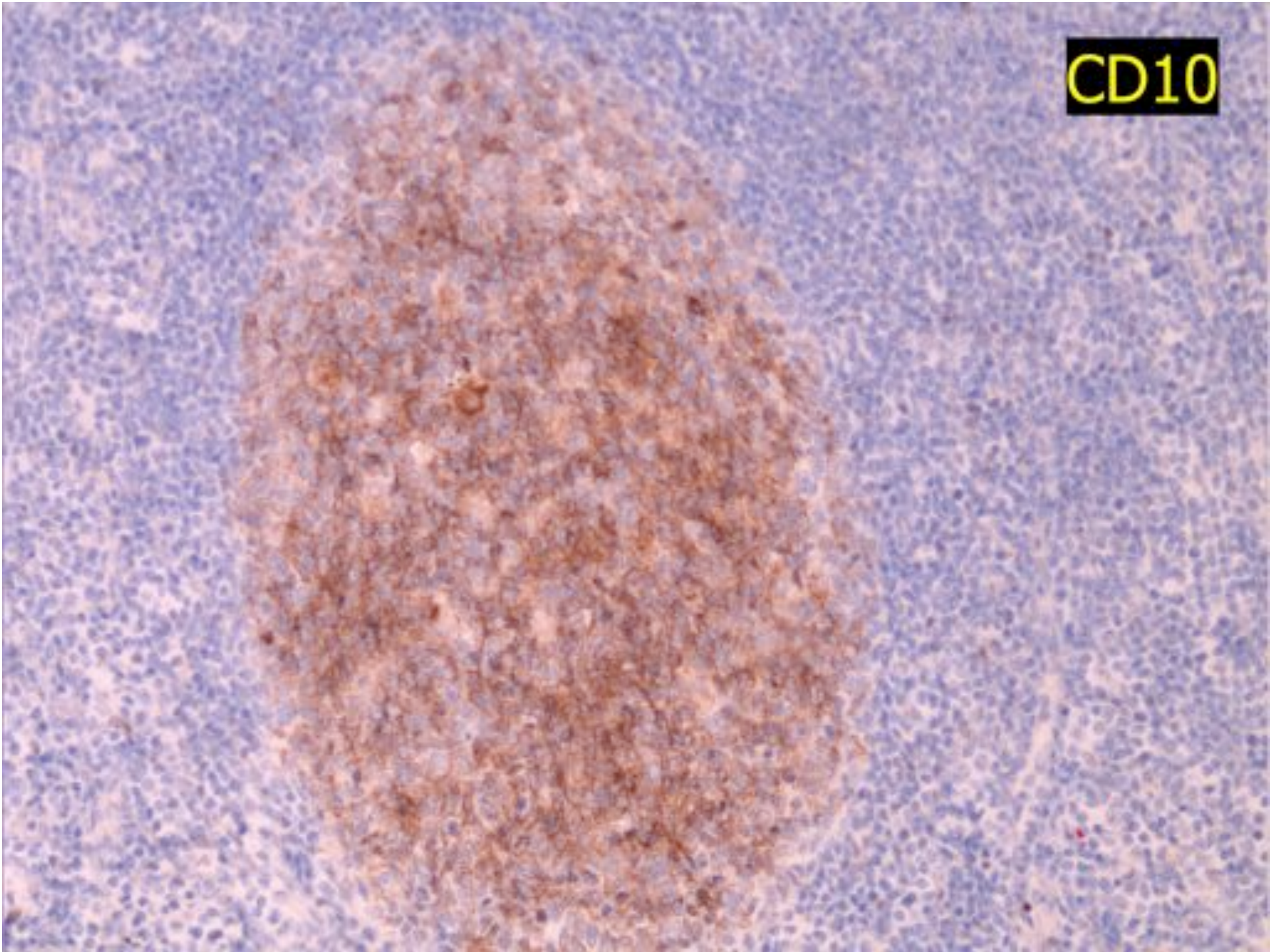
CD79a



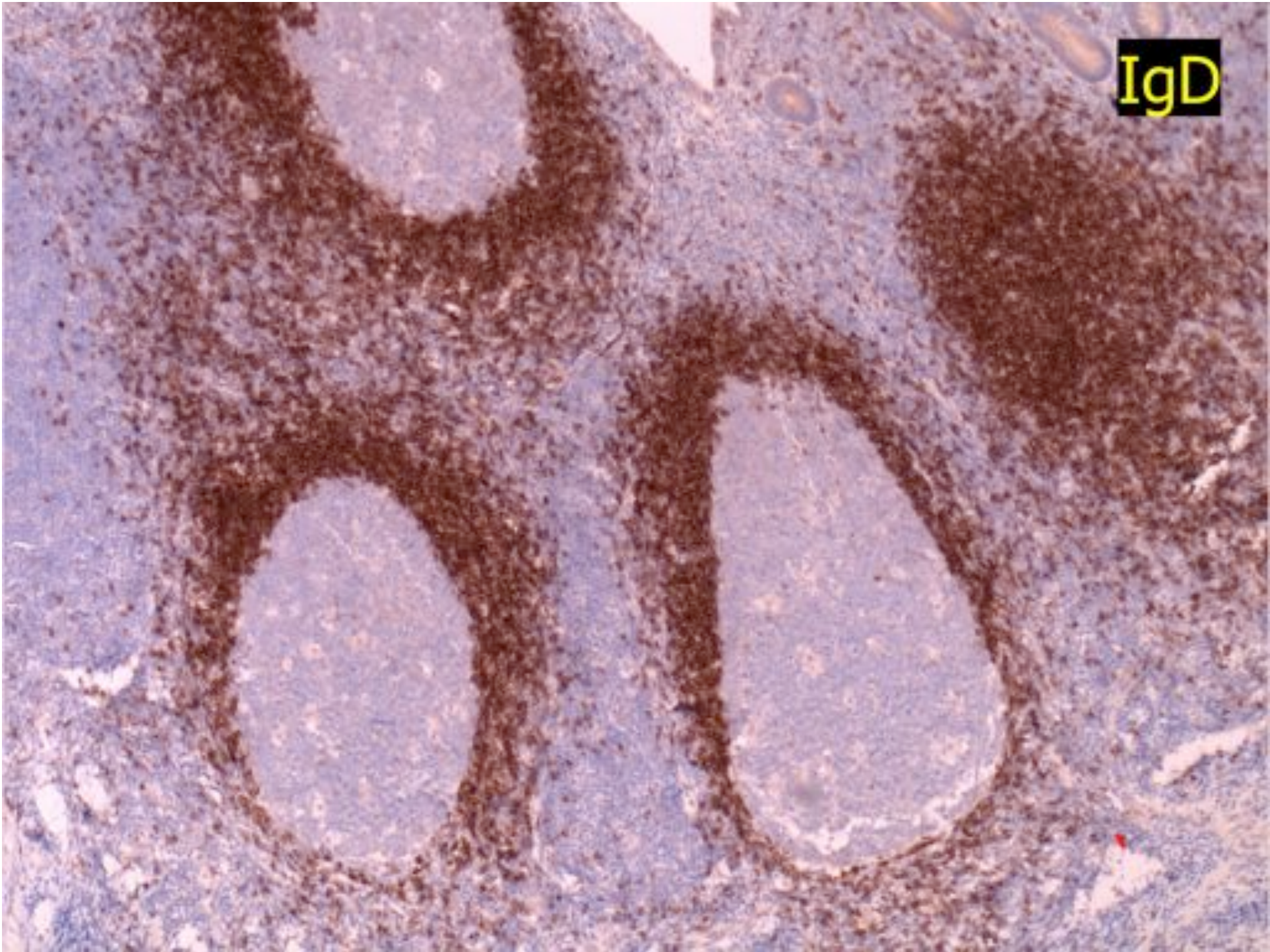
CD21

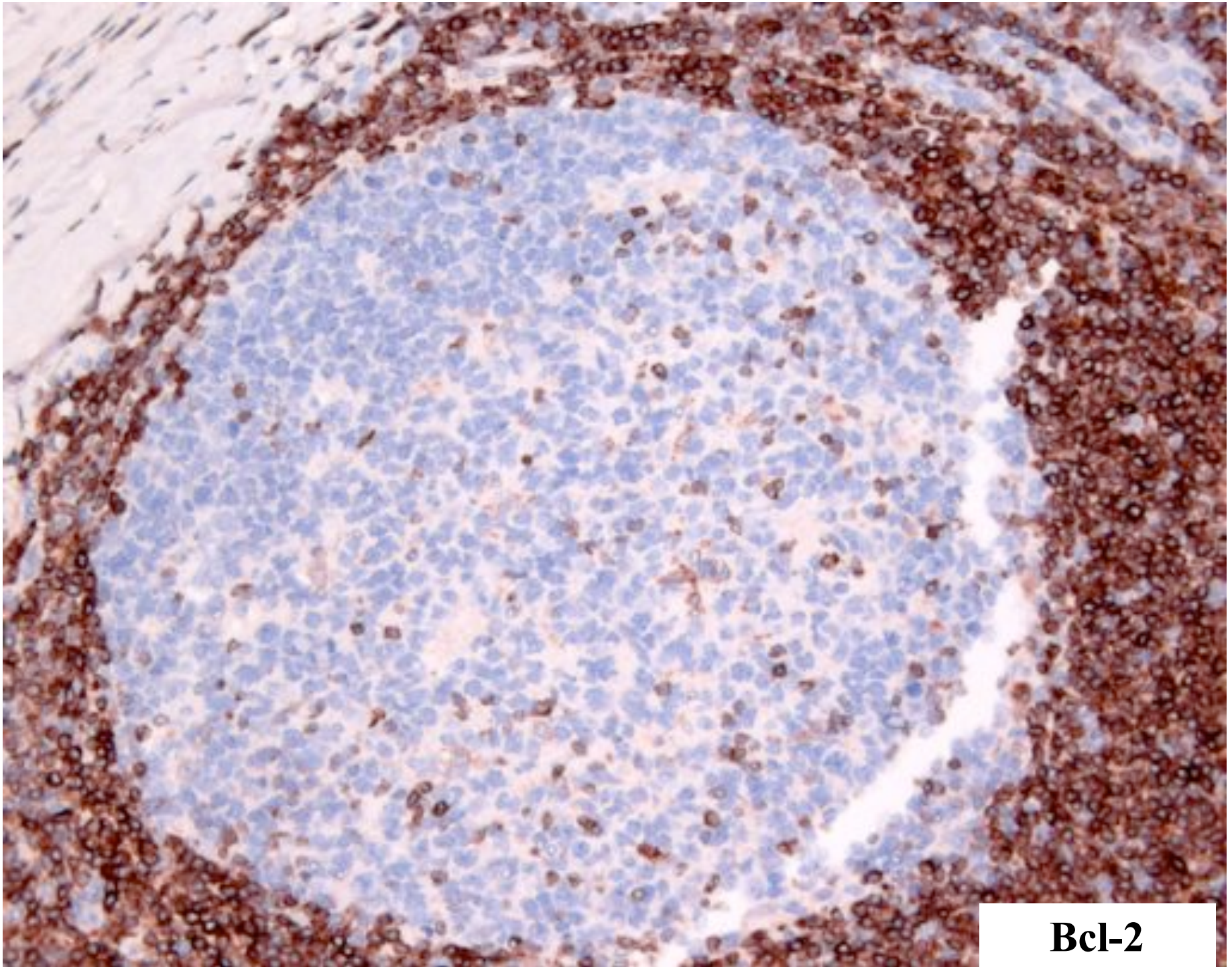


CD10

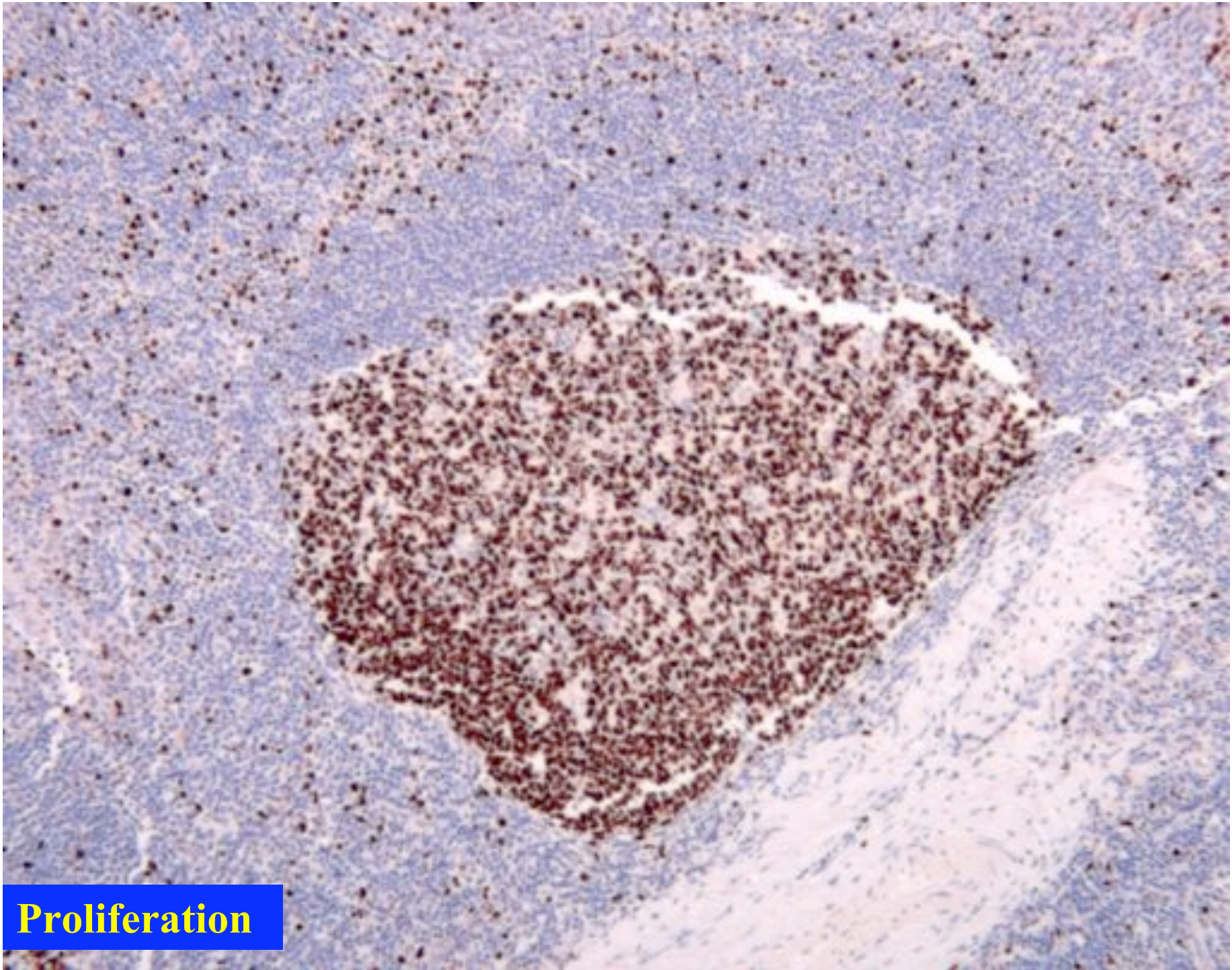


IgD

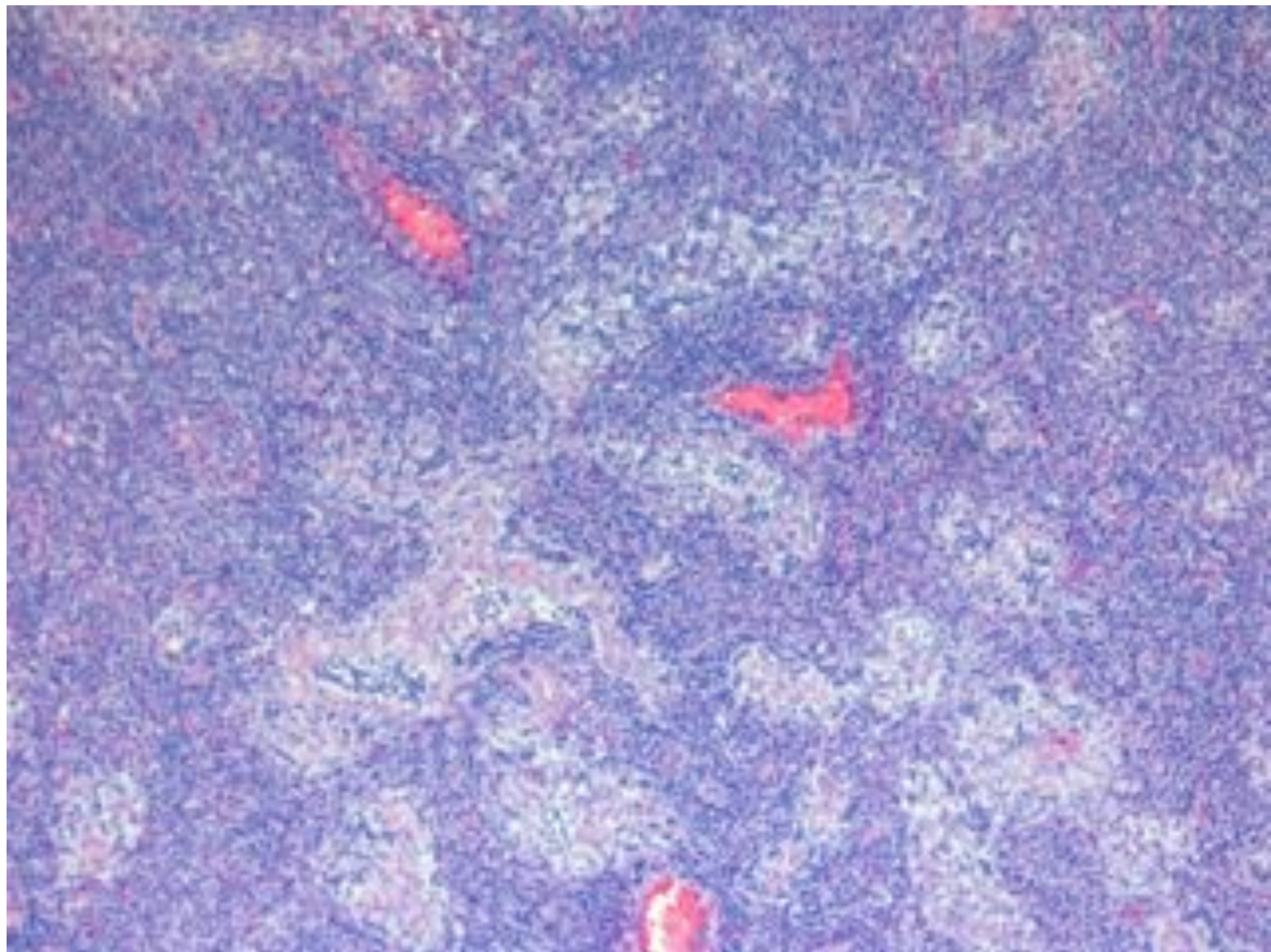




Bcl-2

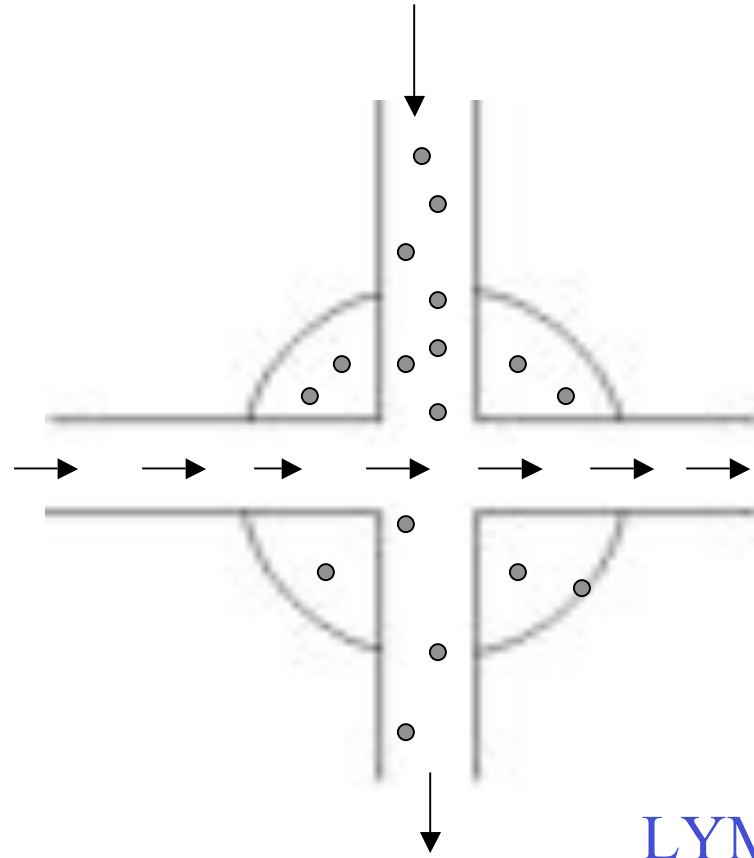


Proliferation



Lymphocytes

Foreign antigen in lymphatics



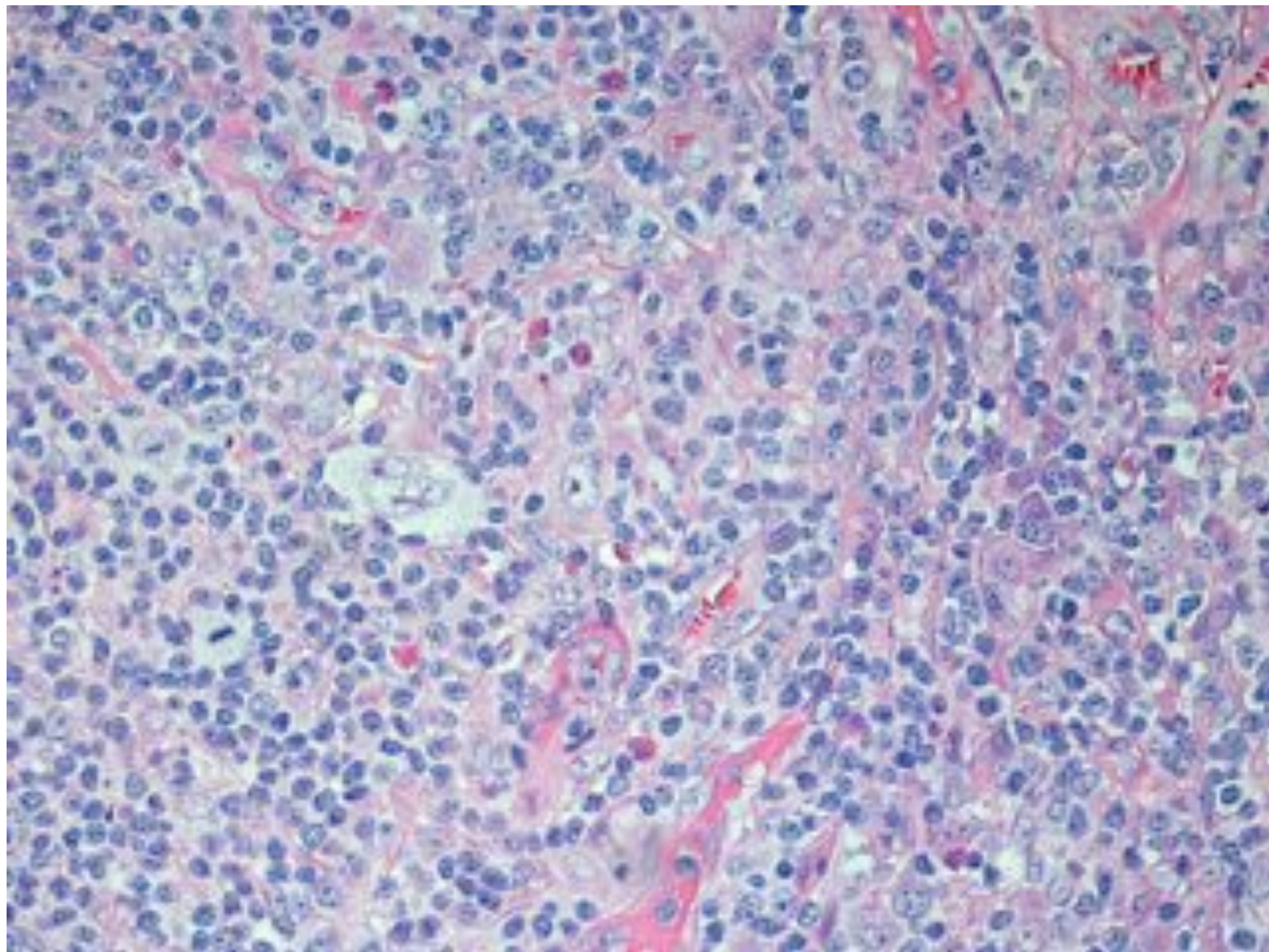
LYMPH NODE –
CONFLUENCE OF
TWO STREAMS

Lymphoma Diagnosis

- Cytologic abnormality
- Architectural abnormality
- Monotony

CYTOLOGICAL ABNORMALITY

- Nuclear pleomorphism
- High nuclear/cytoplasmic
- Many mitoses
- Abnormal mitoses

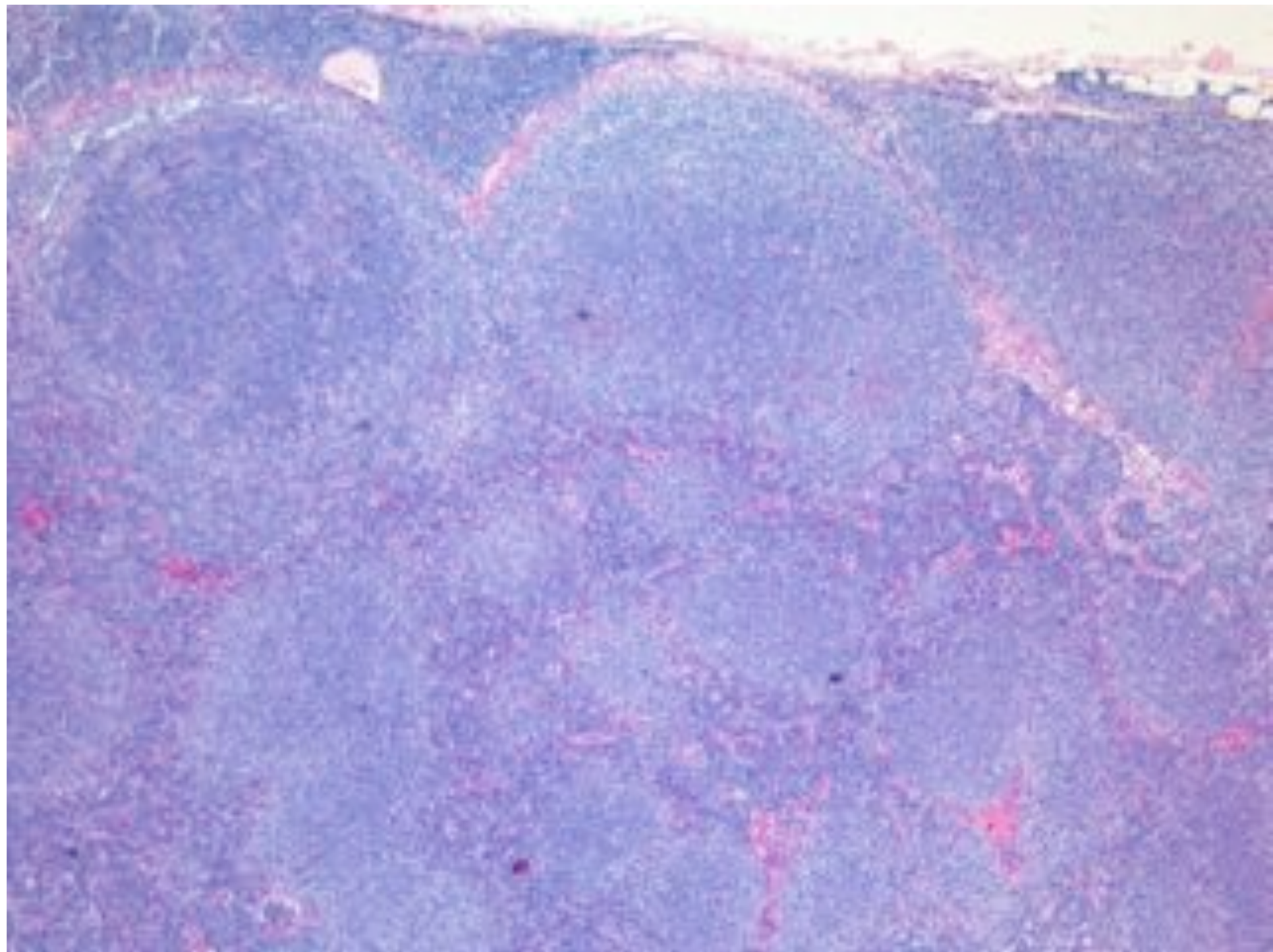


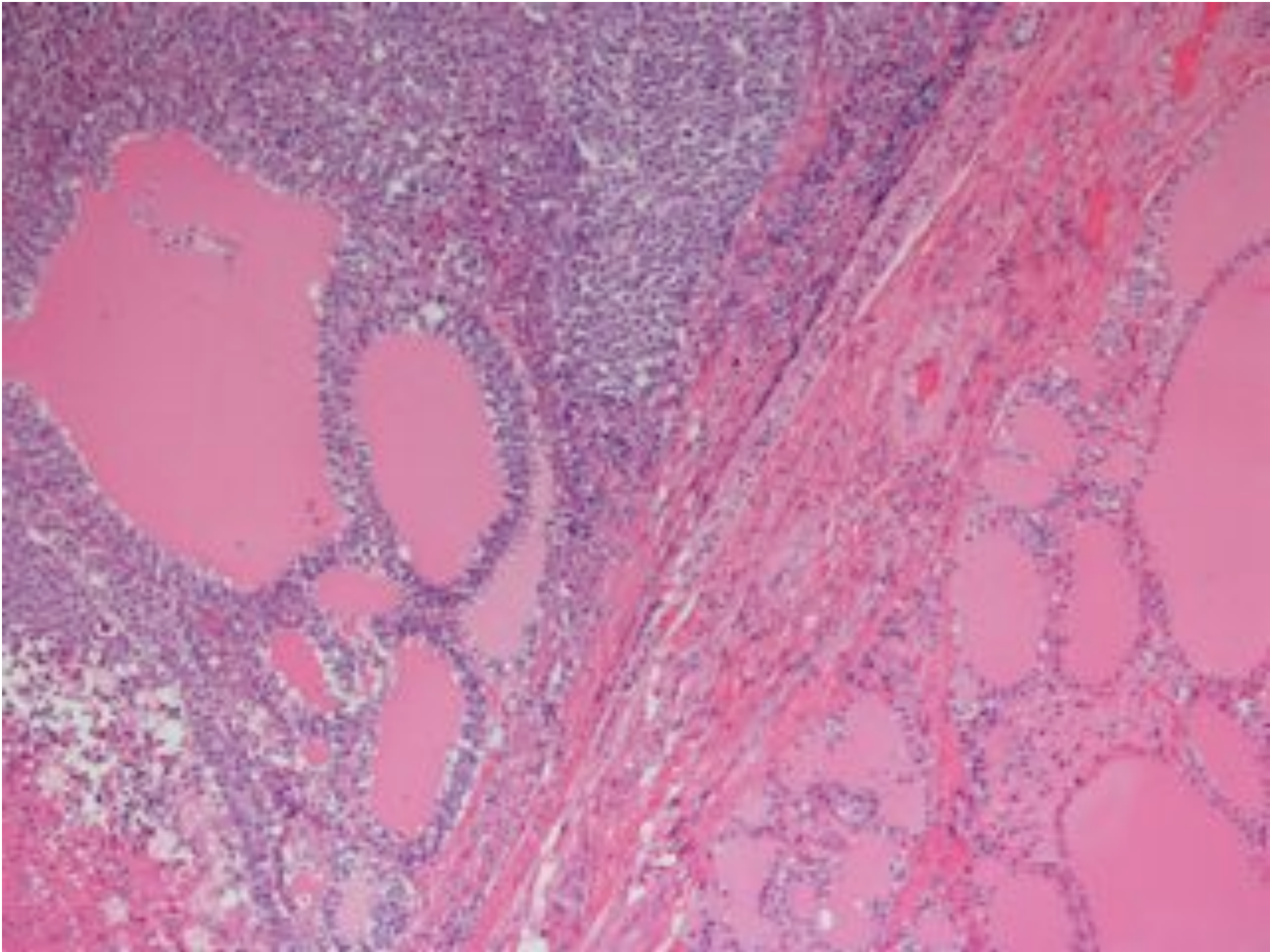
Lymphoma Diagnosis

- Cytologic abnormality
- Architectural abnormality
- Monotony

Architectural

- Invasion
- Destruction of normal tissues
- Abnormal location





Lymphoma Diagnosis

- Cytologic abnormality
- Architectural abnormality
- Monotony

Monomorphic v Polymorphic

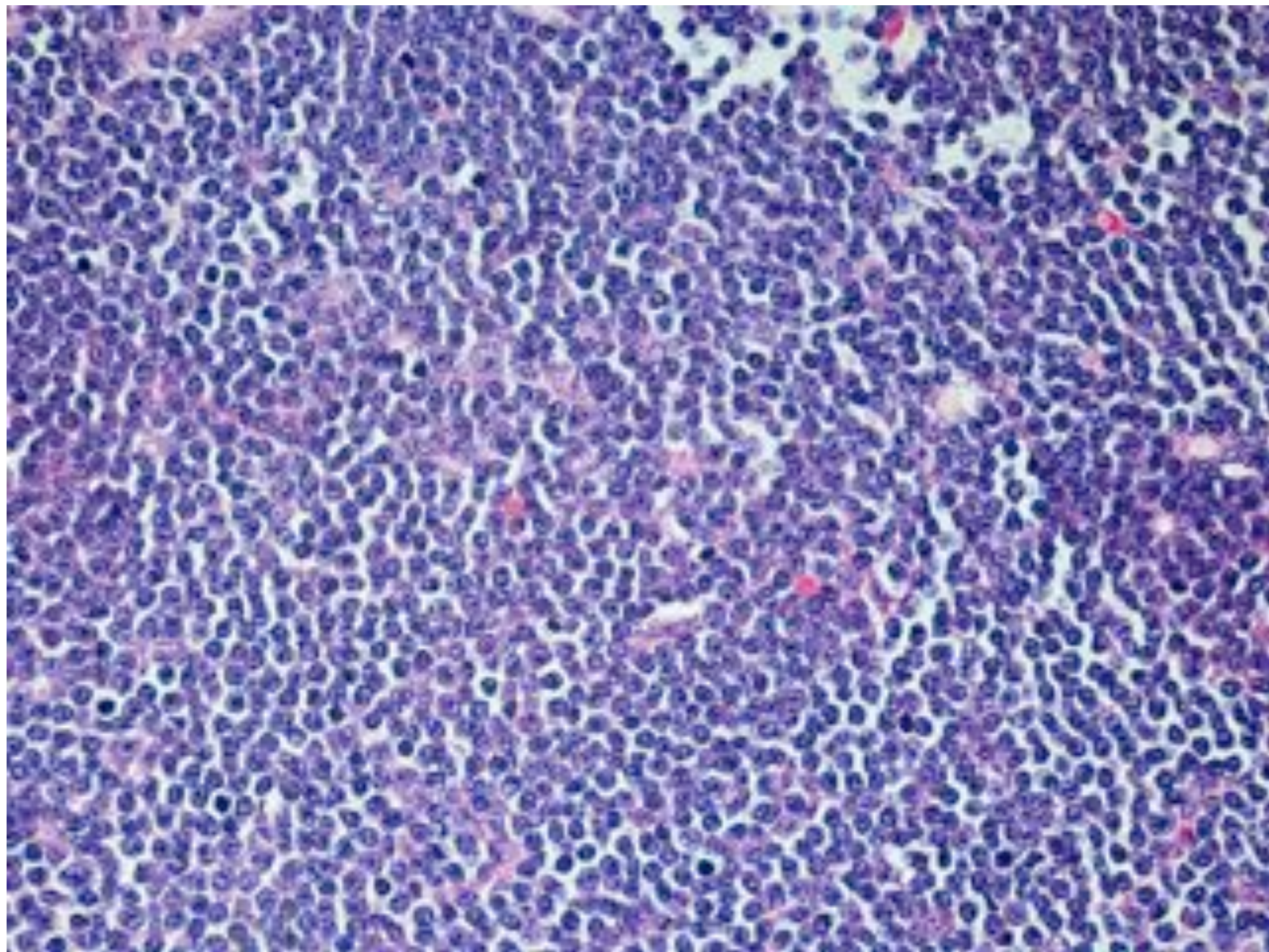
Sheets of same cell type



Monotony (monomorphic)

Reactive Lymph Nodes

- Polymorphic
 - Lymphocytes
 - Blasts
 - Macrophages
 - Eosinophils



Lymphoma Diagnosis

- Cytologic abnormality
- Architectural abnormality
- Monotony

Lymphoma Diagnosis

- Clinical features
- Morphology
- Immunohistochemistry
- Molecular biology

Lymphocyte Antigens

B cell

CD79a

CD20

CD10

T cell

CD3

CD5

CD2

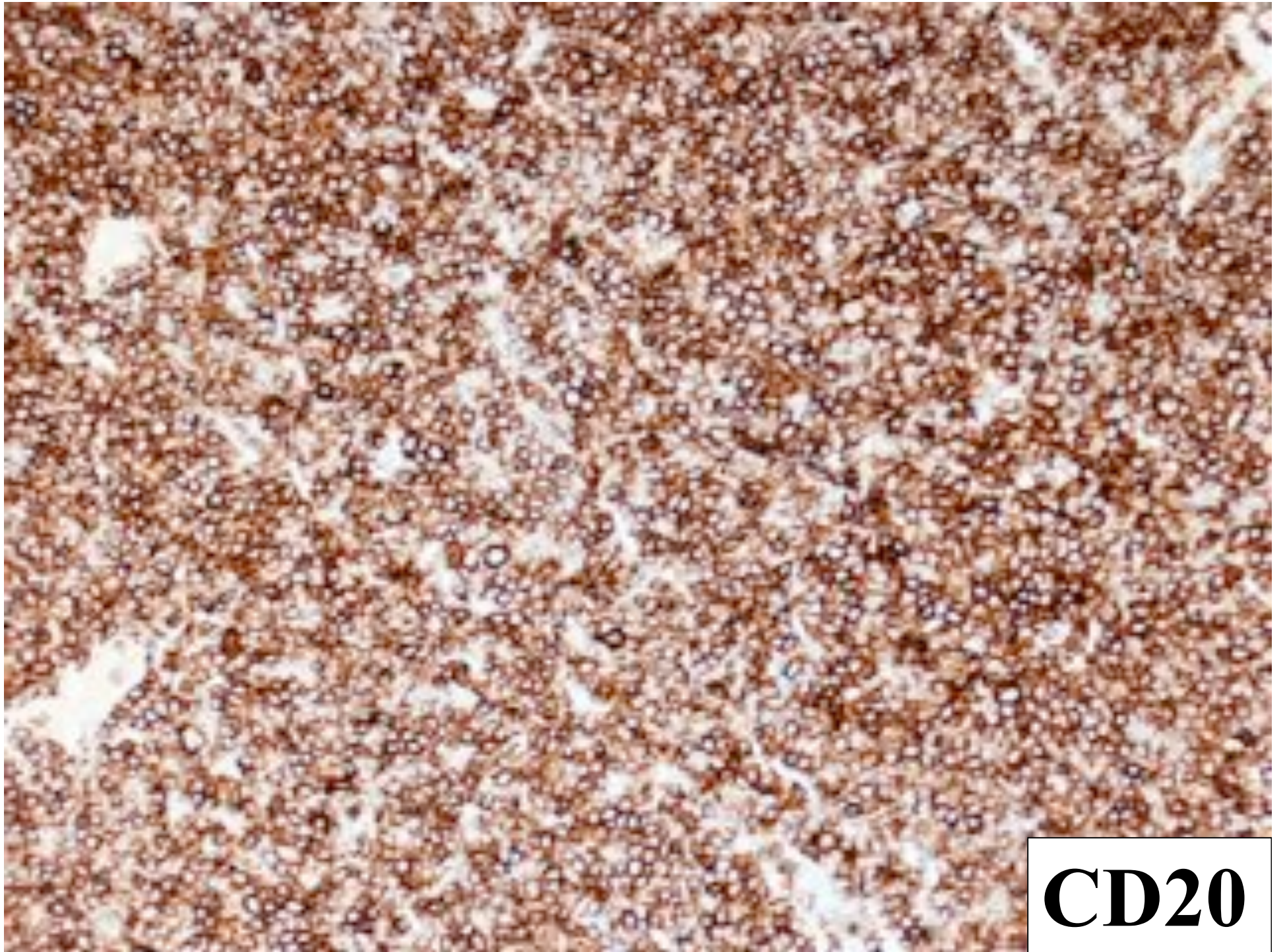
Aberrant Phenotype

B-cell	NHL
--------	-----

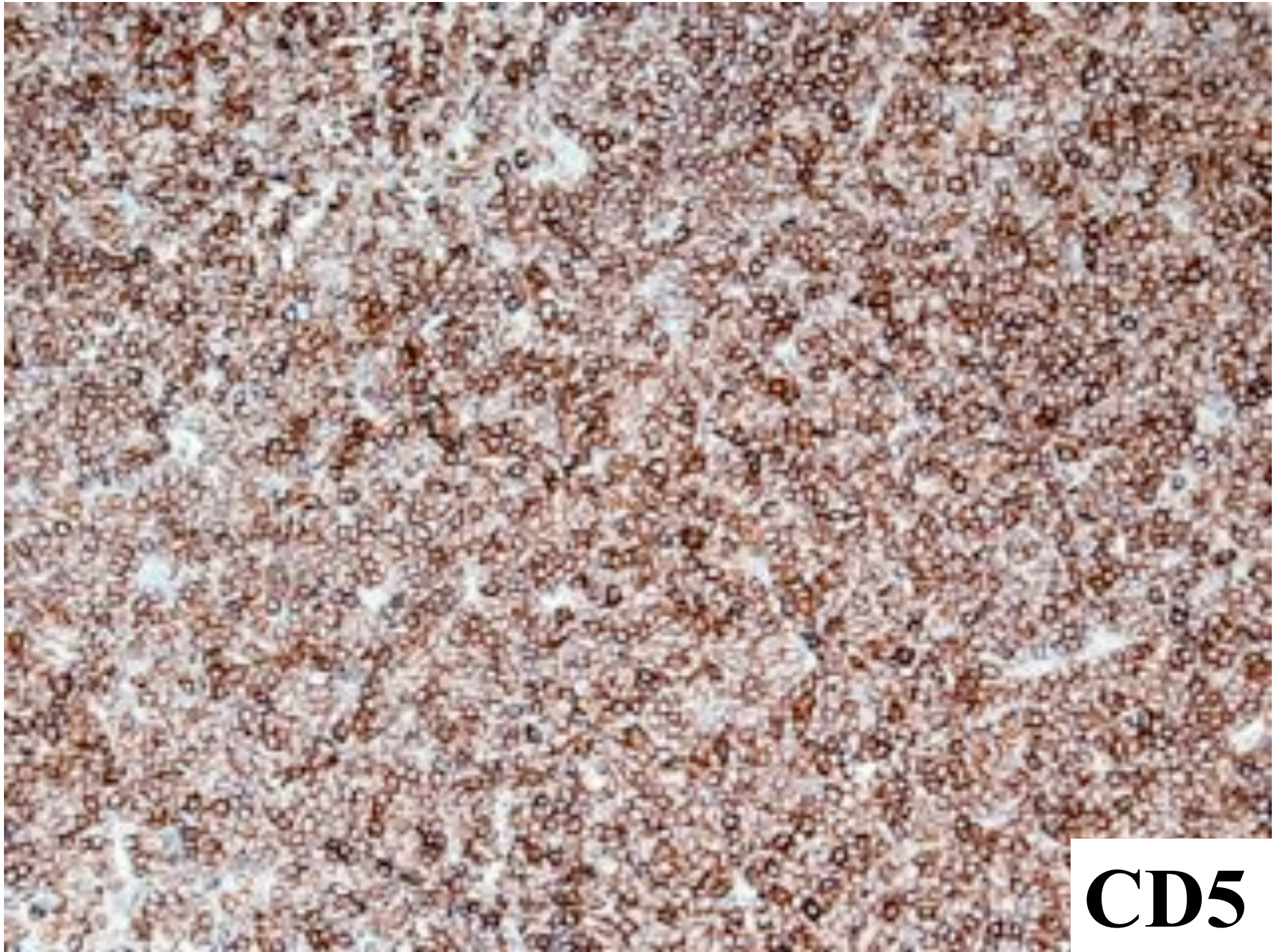
CD20	POS
------	-----

CD5	POS
-----	-----

(CLL and mantle cell lymphoma)



CD20



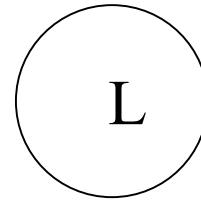
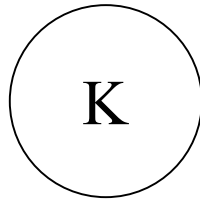
CD5

Aberrant Phenotype

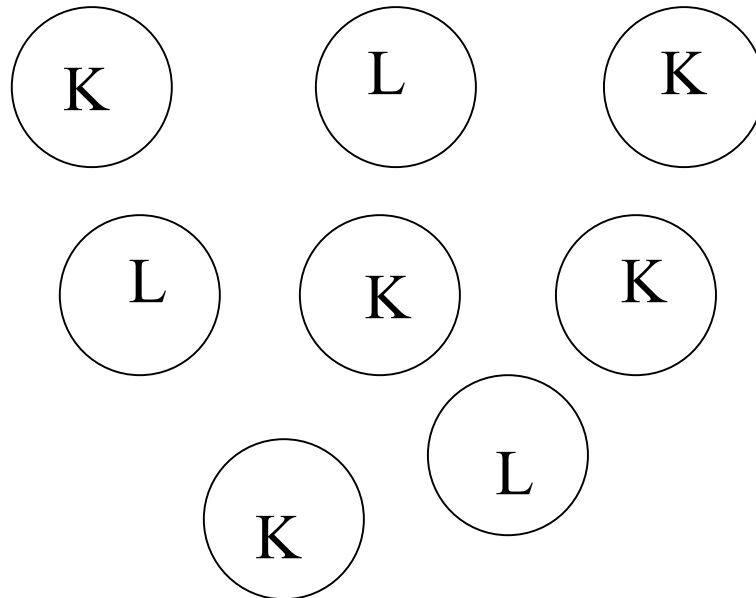
CLONALITY

Immunoglobulin

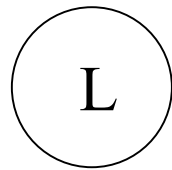
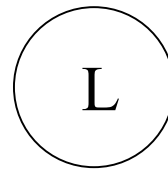
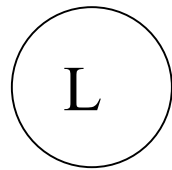
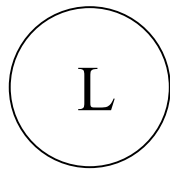
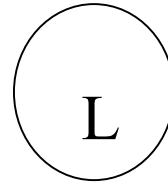

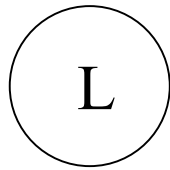
LIGHT CHAINS



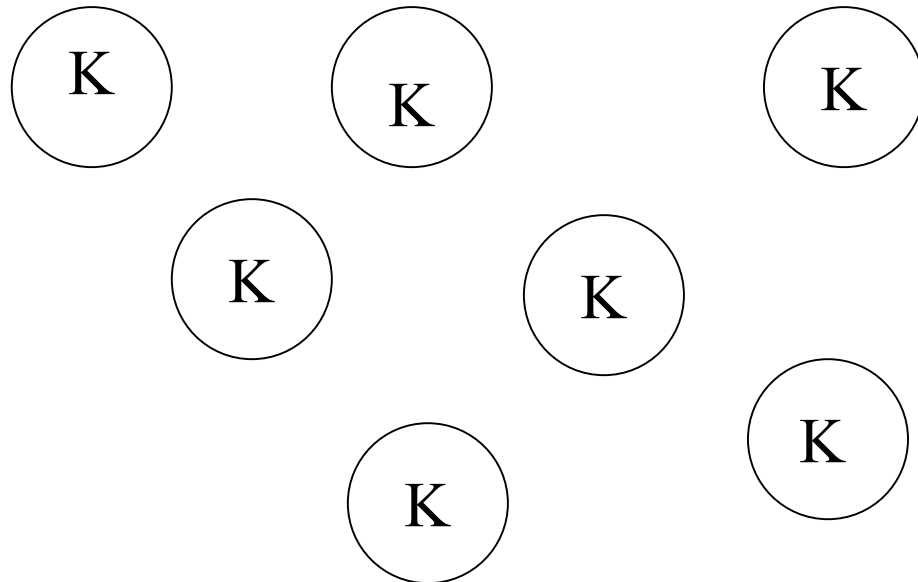
Reactive




B - NHL



B - NHL





L

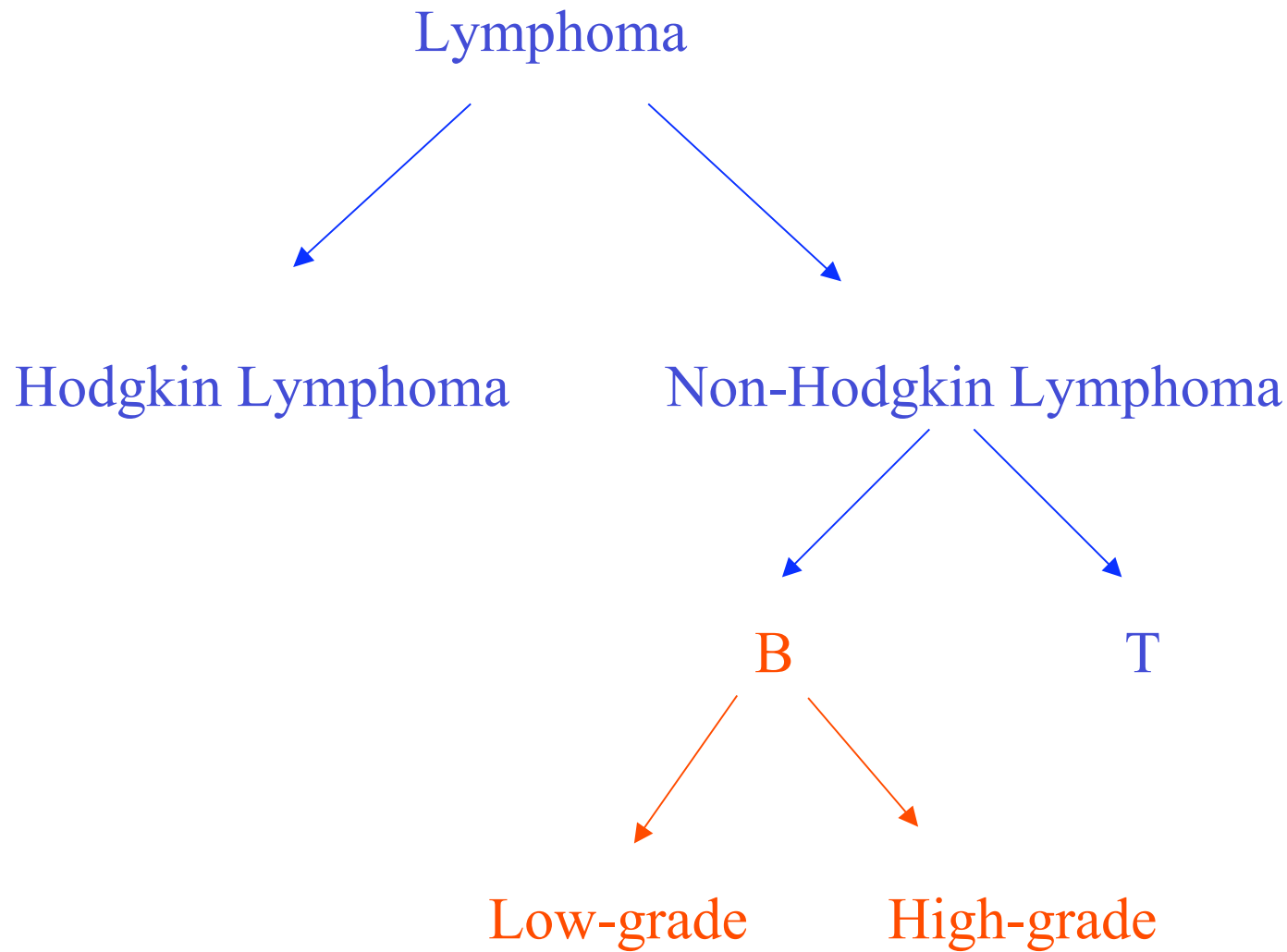


K

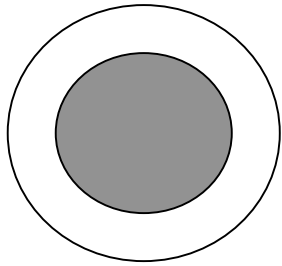
Lymphoma Diagnosis

- Clinical features
- Morphology
- Immunohistochemistry
- Molecular biology

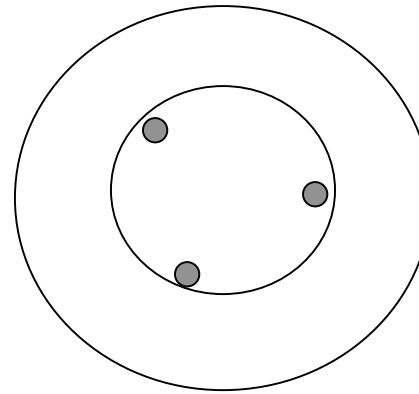
LYMPHOMA CLASSIFICATION



Grade in B-cell NHL



Lymphocytes

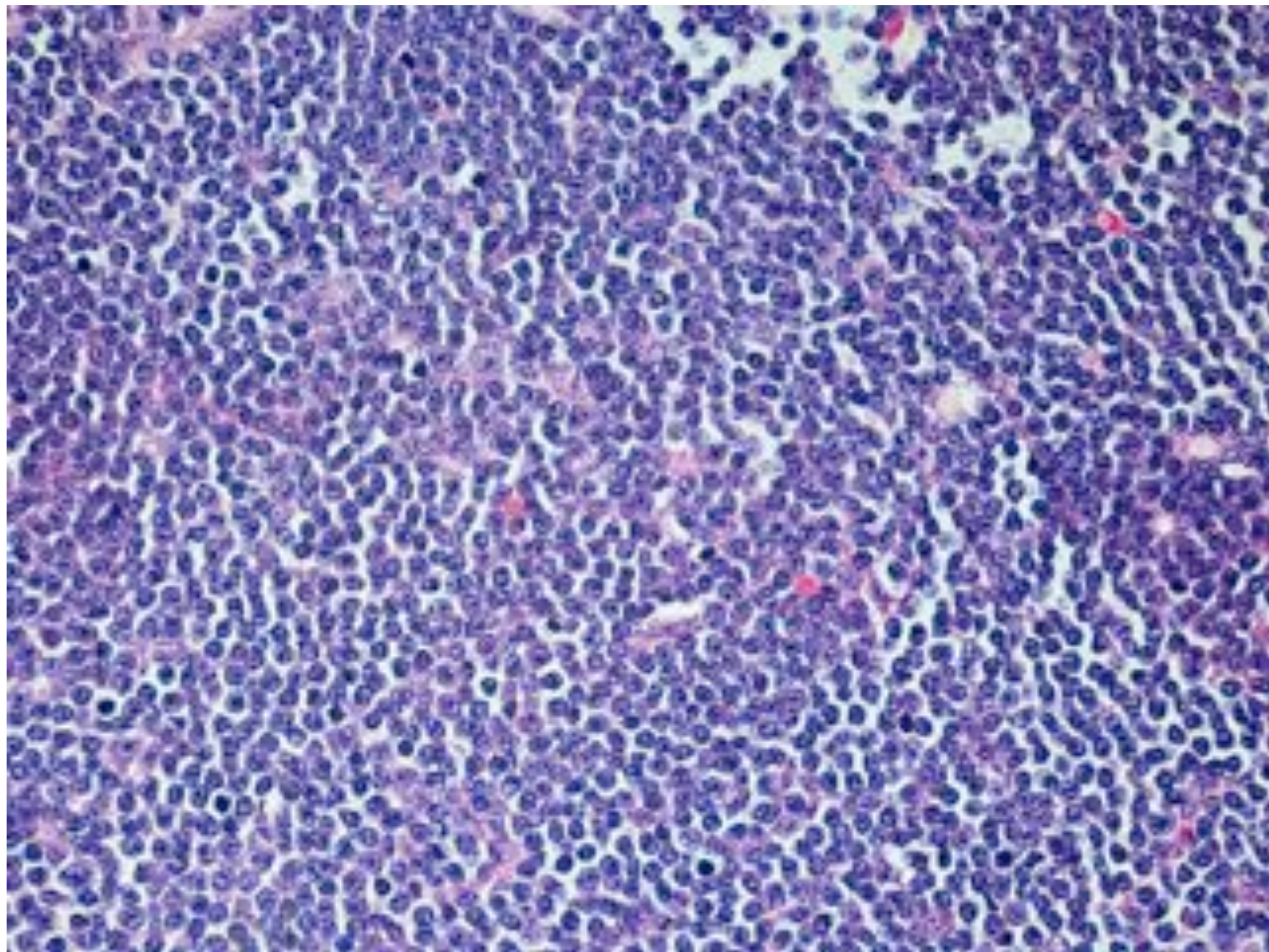


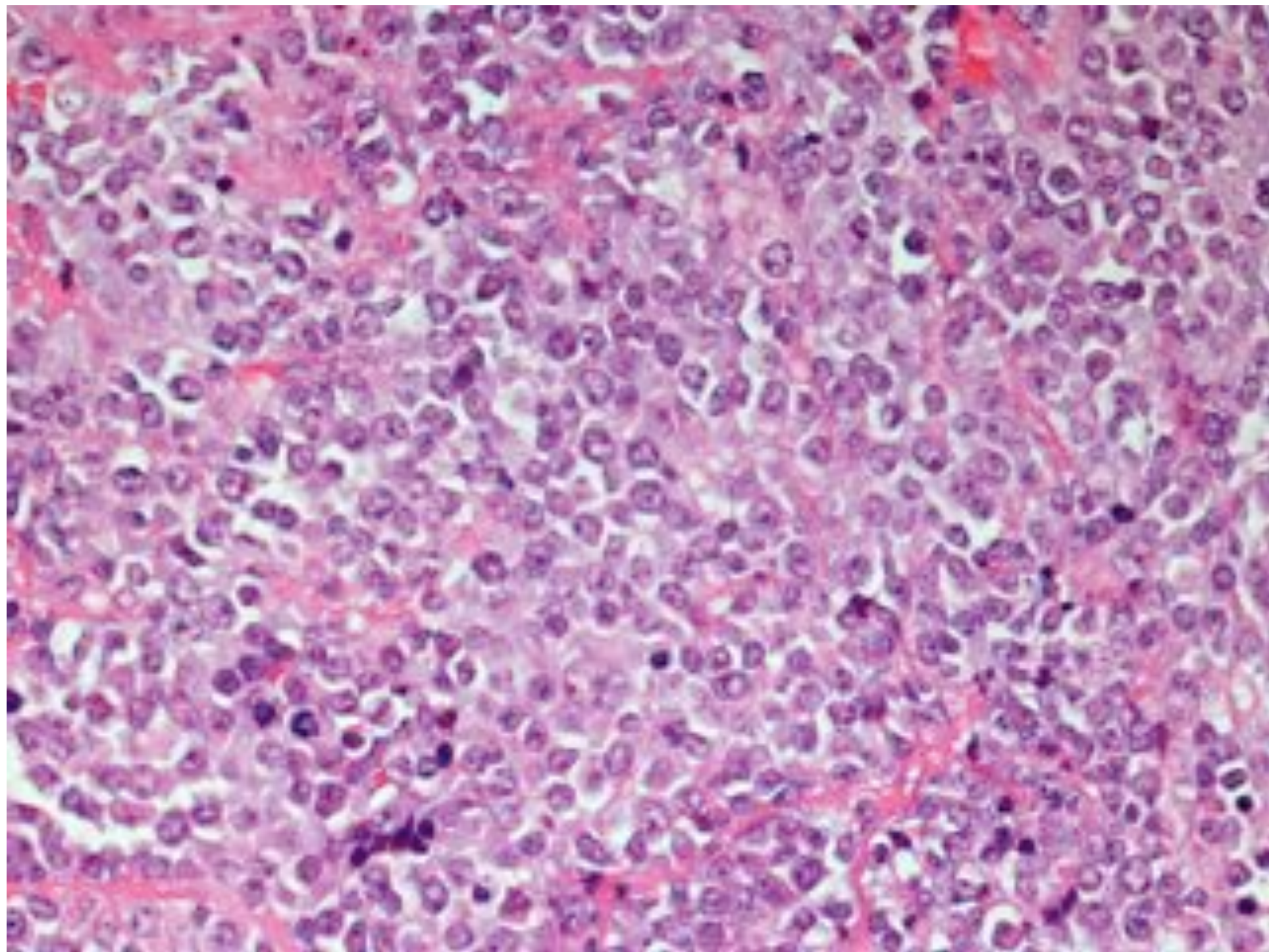
Blasts

All 'cytes - low grade

Cytes/blasts - low grade

Blasts - high grade





LYMPHOMA GRADE

CLL/Lymphocytic	→	DLBCL (Richter's)
Mantle Cell Lymphoma	→	Blastoid Mantle Cell
Follicular Lymphoma (G1, G2, G3a, G3b)		(DLBCL)

NODULAR and FOLLICULAR GROWTH PATTERNS

NODULAR

FOLLICULAR

CLL/lymphocytic

Occasionally

Follicular lymphoma

YES

Mantle cell lymphoma

YES

Marginal zone lymphoma

YES

Nodular sclerosis Hodgkin Lymphoma

NO

Lymphocyte rich Hodgkin Lymphoma

YES

Nodular lymphocyte predominant Hodgkin lymphoma

YES

